

## LETTERS TO THE EDITOR

### Differential expression of cyclooxygenase 2 in human colorectal cancer

EDITOR.—We were puzzled by the recent paper by Dimberg and colleagues (*Gut* 1999;45:730-732) which reported that up-regulation of cyclooxygenase 2 (COX-2) protein expression was prominent in rectal adenocarcinomas compared with that in adenocarcinomas arising from the colon. "Low or undetectable levels of COX-2 protein expression" were demonstrated in 15 of 19 colonic adenocarcinomas located proximal to the rectum. Overall, upregulation of COX-2 protein expression was reported in only 56% of colorectal cancers.

Previous reports,<sup>1-7</sup> which include one by the current authors on a not dissimilar case series,<sup>1</sup> and two in the joint authorship of the accompanying commentary writer,<sup>2,3</sup> have shown consistent upregulation of COX-2 expression in colonic and rectal adenocarcinomas (in 85-90% of cases) compared with matched normal colonic mucosa using different techniques, including northern blot analysis, RT-PCR, western blot analysis, and immunohistochemistry. Furthermore, four of these studies refer to the distribution of adenocarcinomas throughout the colon without showing evidence of differential COX-2 expression between rectal and more proximal tumours.<sup>1,2,4,5</sup> In the one previous study which analysed COX-2 protein expression in human colorectal cancers by western blot analysis,<sup>7</sup> immunoreactive COX-2 was detected in 76% of cases with a 10-fold increase in median tissue COX-2 concentration compared with normal colonic mucosa.

In our view, the authors should attempt to explain the discrepancy between their results and previously published data. It is interesting to note that, in the study of Kargman *et al*, five of six patients taking NSAIDs had low or undetectable COX-2 protein expression.<sup>7</sup> Moreover, aspirin has recently been shown to suppress induction of COX-2 mRNA and protein in interleukin-1 $\beta$  and phorbol ester stimulated human endothelial cells and fibroblasts.<sup>8</sup> Do the authors have data on NSAID use in their cohort of patients prior to surgery?

M HULL

Division of Medicine and Molecular Medicine Unit,  
University of Leeds, Leeds, UK  
Email: medmah@stjames.leeds.ac.uk

M LANGMAN

University of Birmingham, Birmingham, UK

- 1 Dimberg J, Samuelsson A, Hugander A, *et al*. Gene expression of cyclooxygenase-2, group II and cytosolic phospholipase A2 in human colorectal cancer. *Anticancer Res* 1998;18:3283-7.
- 2 Eberhart CE, Coffey RJ, Radhika A, *et al*. Up-regulation of cyclooxygenase 2 gene expression in human colorectal adenomas and adenocarcinomas. *Gastroenterology* 1994;107:1183-8.
- 3 Shattuck-Brandt RL, Lamps LW, Heppner Goss KJ, *et al*. Differential expression of matrix metalloproteinase-2 and cyclooxygenase-2 in intestinal and colorectal neoplasms. *Mol Carcinog* 1999;24:177-87.
- 4 Gustafson-Svard C, Lilja I, Hallbook O, *et al*. Cyclooxygenase-1 and cyclooxygenase-2 gene expression in human colorectal adenocarcinomas and in azoxymethane induced colonic tumours in rats. *Gut* 1996;38:79-84.

- 5 Maekawa M, Sugano K, Sano H, *et al*. Increased expression of cyclooxygenase-2 to -1 in human colorectal cancers and adenomas, but not in hyperplastic polyps. *Jpn J Clin Oncol* 1998;28:421-6.
- 6 Sano H, Kawahito Y, Wilder RL, *et al*. Expression of cyclooxygenase-1 and -2 in human colorectal cancer. *Cancer Res* 1995;55:3785-9.
- 7 Kargman SL, O'Neill GP, Vickers PJ, *et al*. Expression of prostaglandin G/H synthase-1 and -2 protein in human colon cancer. *Cancer Res* 1995;55:2556-9.
- 8 Xu X-M, Sansores-Garcia L, Chen X-M, *et al*. Suppression of inducible cyclooxygenase 2 gene transcription by aspirin and sodium salicylate. *Proc Natl Acad Sci USA* 1999;96:5292-7.

### Reply

EDITOR.—We agree with Drs Hull and Langman that we found upregulation of COX-2 protein expression in a lower fraction of colorectal cancers (CRC) than previously reported. In part, this may simply be explained by the composition of different tumour types within CRC—that is, the number of colonic versus rectal tumours in our cohort compared with others. In the papers referred to it is difficult to assess the fraction of the different tumour types studied. The differences may also be dependent on the genetic basis for the CRCs studied, which we also have indicated in our report but perhaps not emphasised sufficiently. CRCs with a defective mismatch repair capability, recognised by microsatellite instability (MSI), are accompanied by reduced COX-2 levels.<sup>1</sup> At present, we do not know the fraction of MSI type tumours in our series and therefore cannot assess this possibility. An indirect estimate may be achieved since the *Min* mouse model and human studies provide direct evidence that COX-2 expression may be related to loss of APC function.<sup>2</sup> APC and  $\beta$ -catenin mutation analysis of our tumour series shows a good, although not perfect, correlation with COX-2 protein upregulation. Among 18/20 rectal tumours with COX-2 protein upregulation, 12 contained mutations in the APC/ $\beta$ -catenin genes. In contrast, only one of three APC/ $\beta$ -catenin mutated colon tumours revealed COX-2 protein induction and among the remaining 15 non-mutated tumours, two displayed COX-2 protein upregulation. Thus the fraction of APC/ $\beta$ -catenin mutated tumours was also slightly lower (21/38—55%) than previously reported and in accordance with the differential COX-2 induction observed. This may indicate that a larger fraction of CRCs in our cohort are of the MSI type.

Other possibilities for the differences in the fraction of COX-2 upregulation in our tumour series may be the definition of "induction". In our case, a tumour/normal ratio from densitometric scanning of western blots must exceed 2 in two successive independent experiments of the same sample pair to be considered true induction. The use of different methodologies may also influence relative expression of COX-2, for example RT-PCR is sensitive to the quality of isolated mRNA and PCR is not really a quantitative method but needs to be carefully controlled to allow quantitative estimations.

It is also correct, as stated by Drs Hull and Langman, that NSAIDs may suppress COX-2 mRNA induction and COX-2 protein expression in some of the patients in our series. Normally, all drug treatments are withdrawn at least one week prior to surgery at our hospital, making most patients drug free at the time of surgery. However, we do not know if patients

self-administer these types of drugs during the waiting period. We have reviewed the medical records for all CRCs included in the study and found that 7/39 patients were receiving aspirin for cardiovascular protection. Five of these patients had rectal tumours and displayed 7-40-fold induction of COX-2 protein: the two patients with colonic cancer and aspirin treatment revealed <2- and 10-fold induction, respectively. Thus COX-2 suppression caused by NSAID cannot explain the low prevalence of COX-2 induction in the colonic tumours.

Regulation of COX-2 is not fully understood. Because of the close correlation of upregulated COX-2 with mutations in APC/ $\beta$ -catenin genes it has been hypothesised that there is a regulatory link and that the chemopreventive effect of NSAIDs can be attributed to inhibition of COX-2. However, in a recent paper by He and colleagues<sup>3</sup> it was demonstrated that PPAR $\delta$  (peroxisome proliferator activated receptor  $\delta$ ) is a target of both APC and NSAIDs resulting in suppressed PPAR $\delta$  activity and promotion of apoptosis. In addition, COX-2 null mouse embryo fibroblast cells remain sensitive to the antiproliferative and antineoplastic effects of NSAIDs<sup>4</sup>; hence there seems to be other important mechanisms for NSAID mediated tumour suppression.

The samples in our series were obtained consecutively without any selection. At present, we believe that the observed differential expression of COX-2 may be due to underlying differences in genetic alterations and/or that rectal tumours may represent a biologically distinct subtype of bowel cancer. However, we cannot exclude the possibility that the next 39 CRCs collected will display the opposite COX-2 expression pattern, although we believe this is unlikely.

J DIMBERG

Department of Natural Science and Biomedicine,  
University College of Surgery,  
Faculty of Health Sciences,  
Jönköping, Sweden  
Email: djja@hj.hj.se

P SÖDERKVIST

Department of Biomedicine and  
Division of Cell Biology,  
Faculty of Health Sciences,  
Linköping, Sweden  
Email: petso@mcb.liu.se

- 1 Karnes WE, Shattuck-Brandt R, Burgart LJ, *et al*. Reduced COX-2 protein in colorectal cancer with defective mismatch repair. *Cancer Res* 1998;58:5473-7.
- 2 Oshima M, Dinchuk JE, Kargman SL, *et al*. Suppression of intestinal polyposis in *Apc*<sup>fl/fl</sup> knockout mice by inhibition of cyclooxygenase 2 (COX-2). *Cell* 1996;87:803-9.
- 3 He TC, Chan TA, Vogelstein B, *et al*. PPAR $\delta$  is an APC-regulated target of nonsteroidal anti-inflammatory drugs. *Cell* 1999;99:335-45.
- 4 Zhang X, Morham SG, Langenbach R, *et al*. Malignant transformation and antineoplastic actions of nonsteroidal anti-inflammatory drugs (NSAIDs) on cyclooxygenase-null embryo fibroblasts. *J Exp Med* 1999;190:451-60.

### Proton pump inhibitors for Barrett's oesophagus

EDITOR.—Recently, the authors of two leading articles, Triadafilopoulos (*Gut* 2000;46:144-46) and Shepherd (*Gut* 2000;46:147-49) referred to our paper in *Gut*.<sup>1</sup> We would like to draw attention to the fact that the legend in tables 4 and 5 in our paper should be read as (cm.month), (squares.month), and (%.month) since the variable is the area under the curve (AUC), which is the product of length or surface and

time. The printed notation (with a slash) might suggest that the figures concern the change per month. In spite of our suggested change in the galley proof, this notation was maintained. Nevertheless, it does not change the purport of our conclusion, nor the discussion in both leading articles.

F T M PETERS

Department of Gastroenterology and Hepatology,  
Groningen University Hospital,  
PO Box 30 001, 9700 RB Groningen,  
The Netherlands  
Email: ftm.peters@int.azg.nl

- 1 Peters FTM, Ganesh S, Kuipers EJ, et al. Endoscopic regression of Barrett's oesophagus during omeprazole treatment: a randomised double blind study. *Gut* 1999;45:489-494.

### MCP-3 in inflammatory bowel disease

EDITOR.—We read with interest the article by Wedemeyer and colleagues (*Gut* 1999; 44:629-35) on chemokines in inflammatory bowel disease.

Monocyte chemoattractant protein 3 (MCP-3) expression in inflammatory bowel diseases is a very interesting observation and we agree with the authors that MCP-3 might play an important role in the pathophysiology of these diseases.

We have recently published an article on the C-X-C chemokines interleukin (IL)-8 and IP-10, and the C-C chemokines MCP-1 and MCP-3 in the mucosa of active ulcerative colitis.<sup>1</sup> It concerns an immunohistochemical study in which we showed increased expression of these chemokines in the lamina propria of patients with ulcerative colitis compared with normal controls. Furthermore, we observed a significant difference in expression between inactive and moderate/severe ulcerative colitis based on the histological grading in MCP-1, MCP-3, and IL-8.

Wedemeyer and colleagues state in their discussion that MCP-1 is expressed in the epithelial cells and lamina propria whereas MCP-3 is almost exclusively produced by epithelial cells. However, in the results section and further in the discussion the authors mentioned sporadic MCP-3 expression in the lamina propria of inflamed tissue. The photographs show only epithelial cells and it is not possible to see the staining pattern of the lamina propria.

We found MCP-3 expressing cells in the lamina propria which was significantly increased in active ulcerative colitis compared with both inactive ulcerative colitis and normal controls. Furthermore, MCP-3 expression in lamina propria was also enhanced in patients suffering from pouchitis compared with patients with a normal pouch (unpublished data).

In the study of Wedemeyer *et al*, unfortunately the data on MCP-3 expression in Crohn's disease were not significant which might be because of the small number of patients examined. It would be interesting to further evaluate the role of chemokines in Crohn's disease.

In conclusion, albeit with some minor differences, both studies have shown that MCP-3 plays an important role in ulcerative colitis.

U HELWIG  
K M LAMMERS  
P GIONCHETTI  
F RIZZELLO  
M CAMPIERI

Department of Internal Medicine and Gastroenterology,  
University of Bologna, Bologna, Italy  
Email: paolo@meol.unibo.it

M UGUCCIONI

Theodor Koerber Institute,  
University of Bern, Bern, Switzerland

- 1 Ugucioni M, Gionchetti P, Robbiani DF, et al. Increased expression of IP-10, IL-8, MCP-1 and MCP-3 in ulcerative colitis. *Am J Pathol* 1999;155:331-6.

### Reply

EDITOR.—We thank Dr Helwig and colleagues for their interest in our recent paper in which we showed enhanced expression of the C-C chemokine MCP-3 in inflammatory bowel disease mucosa. In the article by Ugucioni and colleagues,<sup>1</sup> we noted their slightly different findings in terms of localisation of MCP-3 expression. Using different techniques (cryostat and paraformaldehyde fixatives, different anti-MCP-3 antibodies) we found consistent expression of MCP-3 in the intestinal epithelium and sporadically in the lamina propria. Ugucioni *et al* reported MCP-3 expression in the lamina propria. The reason why they did not find MCP-3 expression in the epithelium remains unclear. A possible explanation could be that patients received different therapies at the time of colonoscopy. Only one of the patients investigated in the study by Ugucioni *et al* received steroids while most patients with macroscopic inflamed mucosa enrolled in our study received either oral or parenteral steroid medication at the time of biopsy. As mentioned in the results, we also found occasional MCP-3 staining cells within the lamina propria but did not focus our investigation on these cells. Which lamina propria cells express MCP-3 remains to be determined. We found that human isolated mast cells are capable of expressing MCP-3 mRNA (unpublished data) which makes them a possible candidate. Other candidates are macrophages and endothelial cells, as reported by Ying and colleagues,<sup>2</sup> who found MCP-3 expression in bronchial biopsies located in these two cell types and in epithelial cells.

In conclusion, we agree with Dr Helwig and colleagues that the role of chemokines in inflammatory bowel disease needs to be evaluated in more detail. Further data are necessary to answer the question of whether or not these alterations in chemokine expression are restricted to specific disorders such as ulcerative colitis or resemble a more general finding associated with any type of intestinal inflammation and host defence mechanisms.

J WEDEMEYER  
A LORENTZ  
M P MANNES  
S C BISCHOFF

Department of Gastroenterology and Hepatology,  
Medical School of Hannover, Hannover, Germany  
Email: bischoff.stephan@mh-hannover.de

- 1 Ugucioni M, Gionchetti P, Robbiani DF, et al. Increased expression of IP-10, IL-8, MCP-1 and MCP-3 in ulcerative colitis. *Am J Pathol* 1999;155:331-6.  
2 Ying S, Meng Q, Zeibecoglou K, et al. Eosinophil chemotactic chemokines (cotaxin, cotaxin-2, RANTES, monocyte chemoattractant protein-3 (MCP-3), and MCP-4), and C-C chemokine receptor 3 expression in bronchial biopsies from atopic and nonatopic (intrinsic) asthmatics. *J Immunol* 1999;163:6321-9.

### One minute unbuffered urease test: should it be read at 10 minutes?

EDITOR.—The one minute unbuffered rapid urease test,<sup>1</sup> previously described in your journal,<sup>2</sup> was adopted for use at the Royal Melbourne Hospital endoscopy day ward

because of its affordability, ease of use, and rapidity. Over time, we had noticed a number of cases where the test had been negative at the one minute mark but later became positive. As we were unsure of whether these "late" positive results represented true or false positives, we decided to run a short study to assess the accuracy of the urease test compared with the "gold standard" of histology.

To this end we read and recorded the urease test at one and 10 minutes and compared the results with histological demonstration of *Helicobacter pylori* on a single antral biopsy. This was carried out on 90 unselected patients undergoing upper gastrointestinal endoscopy for varied indications. Forty one patients were found to have *H pylori* on histology. The urease test was positive in 20 of these 41 when read at one minute compared with 34 at 10 minutes. There were two false positive results at the one minute mark and four at the 10 minute mark. The performance of the urease test at one and 10 minutes is compared in table 1.

We have demonstrated a significant disparity from published data<sup>2</sup> in the sensitivity of the ultra rapid urease test in our ward. Previous reports have shown a difference between the test results at one minute compared with 15 minutes but this was attributed to the lower initial temperature of the test solution as it was kept refrigerated until just prior to use.<sup>3</sup> In our ward the test solution is made up in batches and stored at 4°C in the refrigerator but the test tubes are put out at the beginning of the day and thus start off at room temperature. There is evidence to suggest that storage at 4°C for a number of days has no deleterious effects on the performance of the rapid urease test<sup>4</sup> but this factor may explain the poor performance of the one minute test in our hands.

These factors aside, it is important to point out that we have concluded that the rapid urease test is quite accurate, with sensitivity and specificity comparable with published values<sup>4-6</sup> for other urease tests, if the reading time is modified to 10 minutes. There are other instances<sup>3-4</sup> of variability of urease test performance depending on the time interval at which it is read. It may be that, prior to use, these tests need to be validated as conditions may vary from the prescribed ones under which the test was designed.

At 10 minutes the unbuffered urease test still provides results quicker than most rapid urease tests and in fact allows us to inform patients and organise further management for them prior to discharge from the endoscopy suite. Given the overall performance of the test, we are quite happy to plan the treatment of *H pylori* on the basis of its results. Histology can be reserved for those cases where urease testing is equivocal or other signs, such as mucosal abnormalities, are being sought.

S SENGUPTA  
G CROSTHWAITE  
University Department of Surgery,  
Royal Melbourne Hospital, Parkville 3050, Australia

Table 1 Comparison of the unbuffered rapid urease test performance at one and 10 minutes

	1 min test	10 min test	p Value
Sensitivity	49%	83%	<0.001
Specificity	96%	92%	0.20
Positive predictive value	91%	90%	0.43
Negative predictive value	69%	87%	<0.002

Correspondence to: G Crosthwaite, 1st Floor, 55 Flemington Rd, North Melbourne 3051, Australia. Email: g.l.crosthwaite@bigpond.com

- 1 Arvind AS, Cook RS, Tabaqchali S, Farthing MJG. One-minute endoscopy room test for *Campylobacter pylori*. *Lancet* 1988;i:704.
- 2 Thillainayagam AV, Arvind AS, Cook RS, Harrison IG, Tabaqchali S, Farthing MJG. Diagnostic efficiency of an ultrarapid endoscopy room test for *H. pylori*. *Gut* 1990;32:467-9.
- 3 NG FH, Wong SY, NG WF. Storage temperature of the unbuffered rapid urease test. *Am J Gastroenterol* 1997;92:2230-1.
- 4 Yousfi MM, El-Zimaity HM, Cole RA, Genta RM, Graham DY. Comparison of agar gel (CLOtest) or reagent strip (PyloriTek) rapid urease tests for detection of *H. pylori* infection. *Am J Gastroenterol* 1997;92:997-9.
- 5 Cutler AF. Testing for *H. pylori* in clinical practice. *Am J Med* 1996;100:35-41S.
- 6 Weston AP, Campbell DR, Hassanein RS, Cherian R, Dixon A, McGregor DH. Prospective, multivariate evaluation of CLOtest performance. *Am J Gastroenterol* 1997;92:1310-15.

### Thalidomide treatment of oesophageal ulceration

EDITOR.—I read with interest the case report of oesophageal ulceration treated successfully with thalidomide (*Gut* 1999;45:463-464). With others, I reported the first successful use of this drug in oesophageal ulceration in 1992<sup>1</sup> although the patient we reported on did indeed have AIDS, and the ulceration was diffuse and proliferative rather than discrete, mimicking lymphoma both macroscopically and microscopically.

The precise mechanism of thalidomide's effectiveness in oesophageal ulceration remains unclear. The case reported raises the intriguing possibility of more widespread application of this drug in idiopathic gastrointestinal ulceration. It has already been used in the lower gastrointestinal tract in Crohn's disease with some success. Idiopathic aphthous ulceration may be the first step in the pathogenesis of Crohn's disease—the breach in the mucosal barrier may allow entry of bacterial flora and their products to the internal milieu thus setting in train the inflammatory cascade that becomes clinical inflammatory bowel disease. A potent, orally available, and especially non-teratogenic T cell inhibitor as effective as thalidomide would be a useful addition to the pharmacological weaponry available for use in inflammatory bowel disease and perhaps also in helicobacter negative gastroduodenal and small intestinal ulceration.

J RYAN  
Brighton Gastroenterology Associates,  
Suite 5, 2 Church St,  
Brighton 3186,  
Victoria, Australia  
Email: jeremy@brightongastro.com

- 1 Ryan J, Colman J, Pedersen J, Benson E. Thalidomide to treat esophageal ulcer in AIDS. *New Engl J Med* 1992;327:208.

### Use of Doppler ultrasound in Crohn's disease

EDITOR.—We read with interest the article by Maconi *et al* (*Gut* 1998;43:654-650). We find it encouraging that other workers are interested in superior mesenteric artery (SMA) flow concerning Crohn's disease activity. Our group has been working on the subject for several years. However, we found it surprising to read that "according to the literature" SMA flow does not correlate with disease activity. Firstly, disease activity needs to be

defined. The Crohn's disease activity index does not correlate with disease activity in individual patients<sup>2</sup> and the reference standard used by Maconi *et al* is probably not a reliable indicator for disease activity. Secondly, it is not correct in our view to correlate the resistive index in one article<sup>3</sup> with mean velocity in another<sup>4</sup> and flow volume in yet another,<sup>5,6</sup> and make the statement "yielding conflicting results" on page 654. In our opinion only flow volume measurements can be used as a reliable indicator.<sup>5,7,8</sup> The fact that Maconi *et al* did not find a correlation between SMA volume flow and disease activity is probably caused by their choice of reference standard, as pointed out by Kjeldsen and colleagues,<sup>1</sup> Hodgson and Bhatti,<sup>2</sup> and van Oostayen and colleagues.<sup>5</sup>

J A VAN OOSTAYEN  
M N J M WASSER  
Leiden University Medical Centre,  
Department of Diagnostic Radiology, Bldg I, C2-S,  
Albinusdreef 2, 2333 ZA, Leiden, Netherlands

- 1 Kjeldsen J, Schaffalitzky de Muckadell OB. Assessment of disease severity and activity in inflammatory bowel disease. *Scand J Gastroenterol* 1993;28:1-9.
- 2 Hodgson HJF, Bhatti M. Assessment of disease activity in ulcerative colitis and Crohn's disease. *Inflamm Bowel Dis* 1995;1:117-34.
- 3 Bolondi L, Gaiani S, Brigola C, *et al*. Changes in splanchnic hemodynamics in inflammatory bowel disease. Non-invasive assessment by Doppler ultrasound flowmetry. *Scand J Gastroenterol* 1992;27:501-7.
- 4 Maconi G, Imbesi V, Bianchi Porro G. Doppler ultrasound measurement of intestinal blood flow in inflammatory bowel disease. *Scand J Gastroenterol* 1996;31:950-3.
- 5 Van Oostayen JA, Wasser MNJM, Griffioen G *et al*. Doppler sonography evaluation of superior mesenteric artery flow to assess Crohn's disease activity: correlation with clinical evaluation, Crohn's disease activity index, and  $\alpha_1$ -antitrypsin clearance in feces. *AJR Am J Roentgenol* 1997;168:429-33.
- 6 Hare C, Hassan MT, Bartram CI, *et al*. Superior mesenteric artery Doppler flow: a valuable indicator of disease activity in Crohn's disease. *Gut* 1996;38:A639 (abstract).
- 7 Van Oostayen JA, Wasser MNJM, Van Hogeand RA, Griffioen G, De Roos A. Activity of Crohn disease assessed by measurement of superior mesenteric artery flow with Doppler US. *Radiology* 1994;193:551-4.
- 8 Van Oostayen JA, Wasser MNJM, Griffioen G, Van Hogeand RA, C.B.H.W.L, De Roos A. Diagnosis of Crohn's ileitis and monitoring of disease activity: value of Doppler ultrasound of superior mesenteric artery flow. *Am J Gastroenterol* 1998;93:88-91.

### Percutaneous drainage of echinococcal cysts (PAIR—puncture, aspiration, injection, reaspiration): results of a worldwide survey for assessment of its safety and efficacy

EDITOR.—In 1996 a letter (*Gut* 1996;38:936) about the use of PAIR (puncture, aspiration, injection of a scolecidal agent, reaspiration) raised a criticism of Dr Morris, a leading expert on the treatment of echinococcosis.<sup>1</sup>

At the same time the WHO Informal Working Group on Echinococcosis launched a survey to evaluate the status of this procedure. A number of centres around the world known to be active in this field were requested to complete forms for patients treated with PAIR: 765 abdominal cysts, mostly hepatic, treated with this technique were reported from various countries. We report the results of this survey (table 1).

Either needles (18-22 gauge) or catheters (5-9 French gauge), depending on the size and location of the cysts, were used. Scolecidal agents were mainly 20% hypertonic saline and 95% ethanol solution. After aspiration and parasitological control of the fluid, a quantity of scolecidal agent, approximately equivalent to one third of the amount aspirated, was injected into the cysts and left for a time varying from 5 to 30 minutes, and then reaspirated: only in the cases of Giorgio and colleagues<sup>2</sup> was the scolecidal agent not reaspirated. In all cases, except for two failures (0.26%) followed by surgery, various degrees of reduction in size (at least 50%) and involution (healing) of the cysts were observed on ultrasound follow up. Anaphylactic shock occurred in four cases (0.52%) and was promptly treated; in one case (0.13%) death ensued notwithstanding resuscitative manoeuvres. Recurrences were observed in 12 cases (1.57%) but in eight (1.05%) they were related to an insufficient amount of scolecidal agent (one tenth instead of the average equivalent of one third of the aspirated fluid). Spillage of the fluid in the abdominal cavity was observed in four cases (0.52%) but all patients were receiving prophylaxis with albendazole (seven days to four hours before to 1-4 weeks after) and no peritoneal dissemination occurred. Minor complications (fever, rash, abscess formation, and biliary fistules) were observed in 105 cases (13.7%); abscess formation was treated with echo guided percutaneous drainage. The follow up is more than five years for 75 cases at the time of presentation of this survey.

These data show that the use of PAIR is widespread and increasing, especially in countries where echinococcosis is endemic. This is also because of its low cost and high efficacy. These data are in accordance with the literature: as of today more than 2400 cysts have been punctured and reported in indexed journals, and success and complication rates are even lower than those of our survey. PAIR is a safe and effective therapeutic tool; the risk of anaphylaxis during PAIR has been greatly overrated. Complication rates, recurrences, and mortality rates are lower than those of surgery.<sup>3</sup> Accuracy of follow up may be a problem where the population is nomadic, but so far no case of peritoneal dissemination after PAIR has been reported.

Table 1 Results of the survey on PAIR by the WHO Informal Working Group on Echinococcosis

Total cases (cysts)	765
Follow up >5 y	75
Follow up <5 y	690
Major complications	
Anaphylactic shock	4 (0.52%) (1 death—0.13%)
Spillage	4 (0.52%) (albendazole prophylaxis)
Minor complications	
Fever (33), rash (14), pain (30), infection of cavity (11), nausea and vomiting (10), intracystic haemorrhage (3), hypotension (2)	105 (13.7%)
Failures	2 (0.26%)
Recurrences	12 (1.57%) (8 (1.05%) due to an insufficient quantity of scoleicide)

There is a need for further studies on PAIR. One of the main issues is to standardise at least some of the points of the various PAIR protocols, under the supervision of the WHO, to compare their efficacy, set up prospective studies, and distribute guidelines to optimise the use of the treatment. Whereas before we felt that the technique was limited to a narrow group of patients,<sup>4</sup> today we believe that PAIR is not only an alternative but an effective first choice diagnostic and therapeutic tool in the management of human cystic echinococcosis.

C FİLICE  
E BRUNETTI  
R BRUNO  
F G CRIPPA  
WHO-INFORMAL WORKING GROUP ON  
ECHINOCOCCOSIS-PAIR NETWORK†

*Divisione di Malattie Infettive e Tropicali,  
IRCCS Policlinico S Matteo,  
Università di Pavia,*

*via Taramelli 5, 27100, Pavia, Italy*

Correspondence to: E Brunetti.

Email: selim@unipv.it

†D Vuitton, Besançon, France; P Schantz, Atlanta, USA; M Caremani, Arezzo, Italy; A Giorgio, Napoli, Italy; C Bastid, Marseille, France; J Stefaniak, Poznan, Poland; E Zeyhle, Nairobi, Kenya; H Wen, China; V Pelacz, Neuquén, Argentina; R Pettinari, Chubut, Argentina; O Akhan, Ankara, Turkey; S Men, Ankara, Turkey; G Hernandez, Avila, Spain; H Schipper, Amsterdam, Netherlands.

- 1 Morris DL. Percutaneous aspiration in the treatment of hydatid liver cysts. *Gut* 1996;**38**:936.
- 2 Giorgio A, Tarantino L, Francica G, et al. Unilocular hydatid liver cysts: treatment with US-guided, double percutaneous aspiration and alcohol injection. *Radiology* 1992;**184**:705–10.
- 3 Khuroo MS, Wani NA, Javid G, et al. Percutaneous drainage compared with surgery for hepatic hydatid cysts. *N Engl J Med* 1997;**337**:881–7.
- 4 Filice C, Brunetti E. Echo-guided diagnosis and treatment of hepatic hydatid cysts. *Clin Infect Dis* 1997;**25**:169–71.

## Reply

EDITOR,—I remain unconvinced of two basic things: is it (PAIR) safe and is it effective? With regard to safety these are three issues.

- (a) Anaphylaxis. This occurred in four patients after PAIR in the current report and caused one death. An additional three patients became hypotensive and 14 developed a rash. I believe this is a higher risk than surgery should entail.
- (b) Dissemination. The peritoneal dissemination of hydatid disease due to needling a liver cyst will take some time to present—how long? In a series of patients with peritoneal hydatid disease, presentation did not occur until nine years (5–14 years) after surgery.<sup>1</sup> Current follow up of PAIR does not address this issue. Spillage of hydatid material only causes recurrence in approximately 30% of patients.<sup>2</sup> Peritoneal hydatid can be a serious or fatal problem.<sup>1</sup>
- (c) Sclerosing cholangitis. A significant proportion of hydatid cysts communicate with the biliary tree; use of scolicedal agents even at open surgery has caused sclerosing cholangitis. The surgeon has the opportunity of identifying and protecting such a communication prior to the use of scolicide.

Is it effective? The comment that the recurrence rate of PAIR is now less than sur-

gery is either simplistic or deliberately misleading. Filice *et al* state that 75 patients (or is it cysts?) have been followed up for five years—the type and frequency of follow up is not stated and this is really critical. Careful ultrasonic follow up can demonstrate recurrence following surgery in up to 22% of patients<sup>3</sup> but one can equally well quote surgical series with poor follow up with low recurrence rates; to claim that recurrence rates are lower following PAIR when the type and completeness of follow up is not even stated in scientifically quite invalid.

That cysts shrink (variably) following PAIR is reported, but what does this mean—is this synonymous with parasite death? I doubt it! Only one PAIR study reported reaspiration at three days post-PAIR<sup>4</sup> and 2/14 patients had live proloscolices.

The use of albendazole for four hours to seven days prior to and for 1–4 weeks after PAIR is clearly an attempt to reduce the risk of recurrence. In my original laboratory work it took of the order of 30 days to be effective<sup>5</sup> and in humans, two patients who received albendazole for one and three weeks, respectively, prior to operation had viable proloscolices.<sup>6</sup> The use of post-spillage therapy to reduce the risk of implantation has been variably effective in animal models of spillage.<sup>7,8</sup>

We have made at least some attempt to define the minimum length of such therapy.<sup>8</sup>

The over representation of a poor presentation of data, which I suspect is of even poorer quality, does not improve my view of PAIR, or of the WHO working group. I am quite prepared to accept that PAIR may be the best available option in some areas of the world where surgery and perioperative care are compromised by economic factors or lack of experience, but its comparison with surgery should await careful long term follow up.

D L MORRIS

*Department of Surgery,  
St George Hospital,  
University of New South Wales,  
Kogarah 2217, Australia*

Correspondence to: Professor D Morris.  
Email: David.Morris@unsw.edu.au

- 1 Koravias DD, Vagianos CE, Kakkos SK, Panagopoulos CM, Andrcula K. Peritoneal echinococcosis. *World J Surg* 1996;**20**:337–40.
- 2 Schiller CF. Complications of echinococcus cyst rupture. A study of 30 cases. *JAMA* 1966;**195**:220–2.
- 3 Little JM, Hollands MT, Eckberg H. Recurrence of hydatid disease. *World J Surg* 1988;**12**:700–4.
- 4 Giorgio A, Tarantino L, Francica G, et al. Unilocular hydatid liver cysts: treatment with US-guided, double percutaneous aspiration and alcohol injection. *Radiology* 1992;**184**:705–10.
- 5 Chinnery JB, Morris DL. Effect of albendazole sulphoxide on viability of hydatid protoscolices in vitro. *Trans R Soc Trop Med Hyg* 1986;**80**:815–17.
- 6 Morris DL. Preoperative albendazole therapy in hydatid cyst. *Br J Surg* 1987;**74**:805–6.
- 7 Morris DL, Chinnery J, Hardcastle JD. Can albendazole reduce the risk of implantation of spilled protoscolices? An animal study. *Trans R Soc Trop Med Hyg* 1986;**80**:481–4.
- 8 Taylor DH, Morris DL, Richards KS. Perioperative prophylactic chemotherapy of echinococcus granulosis: Determination of minimum effective length of albendazole therapy in in vitro protoscolix culture. *HPB Surgery* 1990;**2**:159–64.

## BOOK REVIEWS

**Mucosal T cells. Chemical Immunology. Vol 71.** Edited by MacDonald TT. (Pp 242; illustrated; individuals \$104.50, institutions \$208.75.) Switzerland: Karger, 1998. ISBN 3 8055 6722 7.

I should say immediately that this is an excellent book. For those interested in mucosal immunology, little more is necessary. It comprises an up to date and comprehensive series of 13 reviews by scientists who have made important contributions to the field. I am very pleased to have a copy; it will be extremely useful.

Clinical gastroenterologists spend a great deal of their time battling with mucosal T cells, yet because these cells are too small to be seen with an endoscope (in any case they would be obscured in exudate or by the epithelial cell layer) and are difficult to stain on formalin fixed histopathology sections, they are rarely observed. The weapons used against these adversaries are principally non-specific drugs which have, obviously, worked if the patient gets better.

Thus, although it is tempting to take Sherlock Holmes' attitude and, when told by Watson that the earth revolves around the sun, feel that the mind is an attic that when filled with details of astronomy (or mucosal immunology), will leave no space for the more useful minutiae of Egyptian tobacco (or the indications for the latest biliary expanding metal stent). But Holmes liked to have a comprehensive grasp of the background of the case, and I believe that he would not have missed a chance to study this book had he been a contemporary gastroenterologist.

The language of the book may be a problem for the non-immunologist, particularly if one's medical school notes stop at the Bursa of Fabricius. This is certainly state of the art immunology, but is directed at clinicians as well as scientists. Therefore, if you want to know more about current developments in inflammatory bowel disease, coeliac disease, or HIV, or you are just curious about what some of those cells that you see in biopsy samples might be doing, I strongly recommend that you invest some money in a copy of this book and some effort in reading it. Furthermore, I suggest beginning with the chapter on "Mouse models of gut inflammation"—such models may not be identical to human inflammatory bowel disease, but at least they give us an opportunity to understand it.

And if you can't remember what CD25 is? Get a copy of *Immunobiology* by Janeway and Travers (3rd Edition; Current Biology Ltd, 1997); this is another excellent book where no previous knowledge is assumed. There you are—two rave reviews—or three if you count *A Study in Scarlet*.

A J S MACPHERSON

**Gastrointestinal Endosonography.** Edited by Van Dam J, Sivak MV. (Pp 298; illustrated; £95.00.) UK: W B Saunders & Company, 1999. ISBN 0 7216 7989 7.

This is a collection of work by 31 predominantly North American, European, and Japanese gastroenterologists, digestive surgeons,

and radiologists. The list of authors includes leading figures in the field of digestive endosonography, namely those who took part in the development of the first pieces of equipment and who described the basic principles of endoscopic ultrasound, and the new generation of practitioners responsible for the most recent developments in this area, particularly the introduction of the endoscopic ultrasound guided puncture. This collective work is complete and exhaustive: it is in large format and divided into seven sections, supplemented by a very detailed and helpful index.

The book is a popular work and the teaching material it contains is very practical, detailed, and useful for beginners. However, the book relies on the experiences of the expert authors, which I find to be of much less interest. Much of their experience is now outdated and there is little scope for discussion of other practices. It contains few illustrations of variable quality. I find it strange that colour Doppler and endoscopic images are grouped at the beginning of the book and reproduced in black and white in appropriate chapters.

In summary, this is a book of high quality work with some good illustrations. The division between the technical sections and those on anatomy is well balanced, which is original to this type of work and is very informative. A number of chapters are extremely useful, particularly those on the linear array echoendoscope and portal hypertension. Some areas covered have less impact, particularly those concerned with the authors' different experiences of gastroesophageal and retroperitoneal pathology. Generally, retroperitoneal endosonography is poorly covered; biliary echoendoscopy is not discussed at all. This significant gap is an invitation to other authors to publish a work dedicated to biliopancreatic echoendoscopy; a useful supplement to the work of doctors van Dam and Sivak.

L PALAZZO

**An Atlas of Diagnostic Radiology in Gastroenterology.** Edited by Vallance R. (Pp 396; illustrated; £120) Oxford: Blackwell Science, 1998. ISBN 0 63205 022 5.

It seems almost unimaginable to me that, somewhere out there, exists a clinical gastroenterologist who would not want to own this book. Maybe I was destined to be the curator of the book review section of *Gut* just so that a review copy of this majestic atlas might come across my desk. What little effort it is to find words of praise for this *tour de force* of gastrointestinal radiology.

In one of the most delightfully understated introductions of the century, Roddy MacSween writes that "...this volume brings credit to radiology as a discipline". Oh yes indeed, and so very much more! Dr Vallance and selected colleagues have produced a book in which every single illustration (and there are many hundreds) is crystal clear. There are many radiological texts that are comprehensive, and there is a lesser number in which the pictures are clear. There are few books indeed in which every picture credibly reveals the pathology in a totally convincing manner. I do not believe there is single illustration in this

book that is not of a high order, and this applies equally to plain radiographs, barium studies, ultrasound, CT, MRI, angiography, or EUS.

Despite its visual excellence, there are idiosyncrasies. Quite what CT and MRI scans of parotid tumours are doing in a book of GI radiology quite escapes this reviewer. Less satisfactory still are some of the mini essays introducing each system. I suspect most readers will not be particularly enlightened by the two page essays that introduce each organ—too brief to say any more than most clinicians must surely know already. For example, who would learn much from:

**Ileostomy enema.** The distal small bowel may be examined satisfactorily in patients with an ileostomy by retrograde infusion of barium with or without air, introduced by Foley catheter.

The essays are weak, but the legends and the figures are of exceptional quality. A well constructed legend obviates the need for arrows, or other marks, on the radiograph. In this atlas, arrows do appear from time to time, but they are not intrusive. I suggest that this atlas might very well be added to the extremely short list of books that every gastroenterologist should own.

IAN FORGACS

## NOTES

### Sir Frances Avery Jones British Society of Gastroenterology Research Award 2001

Applications are invited by the Education Committee of the British Society of Gastroenterology who will recommend to Council the recipient of the 2001 Award. Applications (TWENTY COPIES) should include:

- A manuscript (2 A4 pages ONLY) describing the work conducted
- A bibliography of relevant personal publications
- An outline of the proposed content of the lecture, including title
- A written statement confirming that all or a substantial part of the work has been personally conducted in the UK or Eire.

Entrants must be 40 years old or less on 31 December 2000 but need not be a member of the Society. The recipient will be required to deliver a 30 minute lecture at the Annual meeting of the Society in Glasgow in March 2001. Applications (TWENTY COPIES) should be made to the Honorary Secretary, British Society of Gastroenterology, 3 St Andrews Place, London NW1 4LB by 1 December 2000.

### British Society of Gastroenterology Hopkins Endoscopy Prize 2001

Applications are invited by the Endoscopy Committee of the British Society of Gastroenterology who will recommend to the Council

the recipient of the 2001 Award. Applications (TEN COPIES) should include:

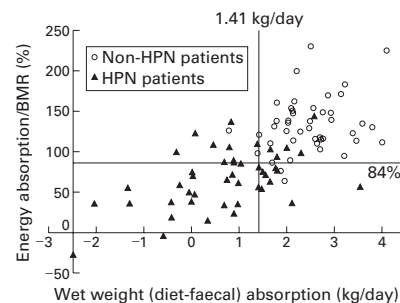
- A manuscript (2 A4 pages ONLY) describing the work conducted
- A bibliography of relevant personal publications
- An outline of the proposed content of the lecture, including title
- A written statement confirming that all or a substantial part of the work has been personally conducted in the UK or Eire.

An applicant need not be a member of the Society. The recipient will be required to deliver a 20 minute lecture at the Annual meeting of the Society in Glasgow in March 2001. Applications (TEN COPIES) should be made to the Endoscopy Section Secretary, British Society of Gastroenterology, 3 St Andrews Place, London NW1 4LB by 1 December 2000.

## CORRECTIONS

An error occurred in the paper by Fisher et al (*Gut* 2000;46:534–539). Levels of protein C, protein S, antithrombin and factor VII were tenfold too high throughout the manuscript. In the Methods section, normal ranges for protein C, protein S, antithrombin and factor VII should have read 66–122 U/dl, 68–146 U/dl, 75–140 U/dl, and 50–150 U/dl. Similar corrections should apply throughout the Results section and in the legend to figure 1. This was an editorial error for which *Gut* apologises.

An error occurred in figure 1 in the paper by Jeppesen and Mortensen (*Gut* 2000;46:701–706). The correct figure is published below. The correct figure appears on the *Gut* website ([www.gutjnl.com](http://www.gutjnl.com)) and thus diverges from the print version of the May issue. We apologise for any confusion this error may have caused.



**Figure 1** 48 hour balance studies defining intestinal failure. Absorption of wet weight and energy in relation to the basal metabolic rate (BMR) calculated by the Harris-Benedict equations in 44 patients managing without parenteral support (non-HPN patients, open circles) and in 45 patients depending on home parenteral nutrition (black triangles). The 5% confidence limits of the non-HPN patients, defining intestinal failure, are given by the lines. Energy absorption/BMR was 84% and wet weight absorption 1.41 kg/day.