

Correction

We regret that in the article by Swash *et al* (*Gut* 1988; **29**: 1692–8) Figures 1 and 6 were duplicated and the correct Figure 1 is printed below.

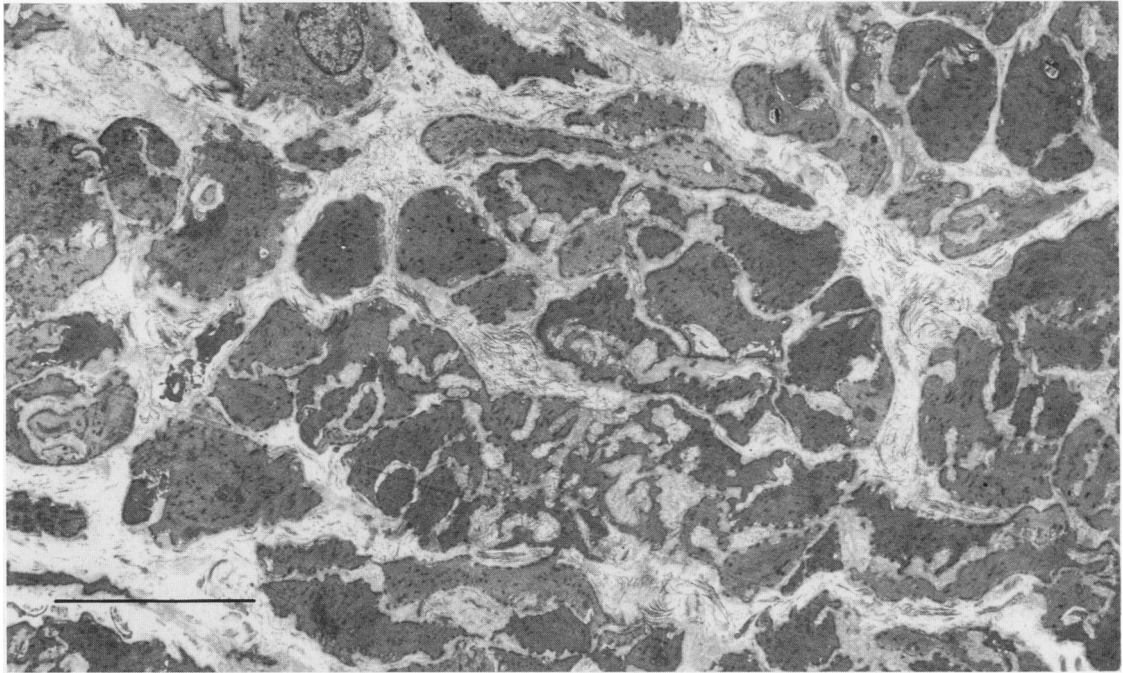


Fig. 1 *Internal anal sphincter muscle in aged control subject. Lobular arrangement of smooth muscle cells is present, but there are increased amounts of collagen in the interstitial spaces. There is marked variability in size and electron density of the smooth muscle cells. Bar 10 μ m.*