

OC-078

USING DIFFUSION WEIGHTED MR IMAGING TO DISSECT THE NEUROANATOMY OF HUMAN SWALLOWING RELATED BEHAVIOURS

doi:10.1136/gut.2011.239301.78

S Mistry,^{1,*} E Michou,¹ S Singh,¹ S Jefferson,¹ D Downey,² K Embleton,² H Haroon,² D Morris,² G Parker,² S Williams,² S Hamdy,¹ and Manchester Academic Health Sciences Centre and Biomedical Imaging Institute ¹Inflammation Sciences, University of Manchester, Manchester, UK; ²Imaging Science, University of Manchester, Manchester, UK

Introduction Understanding the relevance of neural pathways that control human swallowing and related behaviours is paramount to correctly identifying and treating swallowing disorders. We aimed to evaluate these connections using complementary imaging modalities in vivo.

Methods In 13 healthy adults (3 Male/10 Female, 27–62 years old) Transcranial Magnetic Stimulation (TMS) evoked pharyngeal motor responses were recorded via a swallowed intraluminal catheter and used to assess motor cortical pharyngeal representation in both hemispheres.¹ Thereafter, event-related 3T functional magnetic resonance imaging (fMRI) was applied to assess blood-oxygen-level-dependent signal changes (compared to rest) in response to a pseudo-randomised order of water and saliva swallowing in addition to a tongue elevation task. Swallow related behaviour was monitored using a pressure feedback belt around the subjects' neck. Distortion-corrected diffusion weighted imaging (DWI) data were then acquired for probabilistic tractography to determine anatomical fibre tracts. Task-related fMRI activations were identified in SPM8 and used to seed unconstrained multi-fibre probabilistic tractography independently in each hemisphere.² These results were compared with TMS inter-hemispheric differences.

Results TMS data revealed 12/13 subjects had asymmetric motor representation (lateralised dominance) for the pharynx (6 left, 6 right) with significantly larger responses observed in the lateralised projection ($p < 0.001$). fMRI data (figure 1) also revealed asymmetric activations in both sensorimotor

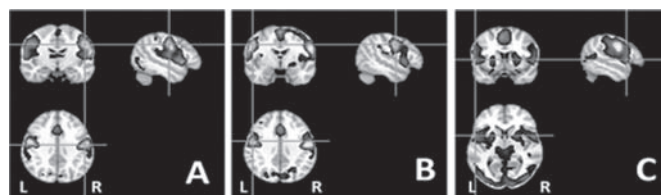


Figure 1 OC-078 fMRI activation for swallowing and related behaviours

cortices in each subject for the different tasks which were used as seed regions for tractography. Largest activations were observed in primary motor cortices (Brodmann Area (BA) 4) after water swallowing, predominantly right lateralised. By contrast, tongue elevation and saliva swallowing produced a greater number of left lateralised brain areas, particularly pre- and supplementary-motor cortex (BA 6) as well as areas involved with language and speech processing (BA 22,40,44). Tractography revealed larger tract volumes in the hemispheric dominant projection predicted by TMS compared to the non-dominant projection for water but not for saliva swallowing or tongue elevations ($p < 0.001$).

Conclusion Using multimodal imaging we have performed a detailed mapping of the network of neural pathways that contribute to human swallowing and its related behaviours. Our data also provide further evidence for cerebral asymmetry and its relevance in the control of human swallowing.

Competing interests None.

Keywords diffusion weighted imaging, functional magnetic resonance imaging, human, magnetic resonance imaging, neuroanatomy, pharyngeal motor evoked potential, swallowing, tractography, transcranial magnetic stimulation.

REFERENCES

1. Mistry, *et al.* Unilateral suppression of pharyngeal motor cortex to repetitive transcranial magnetic stimulation reveals functional asymmetry in the hemispheric projections to human swallowing. *J Physiology* 2007.
2. Parker, *et al.* A framework for a streamline-based probabilistic index of connectivity (PICO) using a structural interpretation of MRI diffusion measurements. *J Magnetic Resonance Imaging* 2003.