

PMO-147 RECOMBINANT ERYTHROPOETIN SUPPORT IS EQUALLY EFFECTIVE IN THE TREATMENT OF HCV PRE AND POST TRANSPLANT

doi:10.1136/gutjnl-2012-302514b.147

A Barnabas,* D Joshi, K Agarwal. *Institute for Liver Studies, Kings College Hospital, London, UK*

Introduction Recombinant EPO is often used in an attempt to improve Hepatitis C virus (HCV) treatment outcomes in complex patient groups. We assessed if its use was as effective in the post-transplant population as in a non-transplant group that also required EPO support. There is currently an absence of clear guidelines in this area and little evidence to support its efficacy overall.

Methods Between December 2009 and July 2010, 57 patients were prescribed EPO while undergoing HCV treatment. In this group, 13 patients who had undergone liver transplantation were identified. These were matched by HCV, genotype, gender and stage of liver fibrosis with a non-transplant group also treated with EPO. Numbers of patients being re-treated for HCV were similar in transplant and non-transplant groups (6/13 and 7/15 respectively).

Results 3/15 (19%) in the non-transplant group and 1/13 (7.7%) patients in the transplanted group achieved a sustained virological response to treatment. Discontinuation rates, however, were lower in the non-transplant group (4 vs 8, OR 10.4). The initial Hb was not significantly different between the two groups (mean 12.78 in the transplant group and 13.42 in the non-transplant group, $p=0.39$). Mean decrement in Hb was similar in transplant and non-transplant groups over the first 8 weeks of treatment (3.07 vs 2.54 g/dl) and the mean time to nadir in haemoglobin was similar in both groups (16 vs 19 weeks). 7/15 (47%) (non-transplant vs 7/13 (54%) transplant patients had a Hb decrement >4 mg/dl on treatment (OR 0.83). Five patients (38%) in the transplant group and 7 (47%) in the non-transplant group required EPO prior to treatment week 8. Median treatment duration was shorter in the transplant group (24 vs 48 weeks). Ribavirin dosages varied widely in both groups and there was significant variation in ribavirin dose reduction strategies. One patient in the non-transplant group developed a deep vein thrombosis and one patient in the transplant group had a CVA while on treatment with EPO.

Conclusion Anaemia related to hepatitis C treatment both presents and is managed similarly in both transplant and non-transplant difficult-to-treat populations. The risk of thrombotic events with EPO use is significant should be carefully borne in mind when initiating EPO support.

Competing interests None declared.

PMO-148 EVALUATION OF LIVER FIBROSIS IN YOUNG ADULT PATIENTS WITH CHRONIC HEPATITIS B VIRUS

doi:10.1136/gutjnl-2012-302514b.148

¹C Patel,* ¹U S Gill, ¹W Alazawi, ²P Shaw, ³E Alstead, ⁴Y Kallis, ⁴P Kooner, ⁴R Marley, ⁵S Naik, ⁶J ChinAleong, ⁷R D Goldin, ¹G R Foster, ¹P T F Kennedy. ¹Department of Hepatology, Blizard Institute of Cell & Molecular Science, Barts and The London School of Medicine & Dentistry; ²Department of Pharmacy, Whipps Cross University Hospital NHS Trust, London, UK; ³Department of Hepatology, Whipps Cross University Hospital NHS Trust, London, UK; ⁴Department of Hepatology, Barts and The London NHS Trust, London, UK; ⁵Department of Paediatric Gastroenterology & Hepatology, Barts and The London NHS Trust, London, UK; ⁶Department of Histopathology, Barts and The London NHS Trust, London, UK; ⁷Liver & GI Pathology, Imperial College, London, UK

Introduction Current guidelines do not recommend treatment of Chronic Hepatitis B (CHB) in young adults as they are believed to be immune tolerant with minimal liver damage. Recently we

demonstrated that young CHB patients have evidence of immune activity comparable to older patients. Therefore, a proportion of young patients will develop fibrosis as a consequence of immune mediated liver injury. Despite this, the most appropriate modality to assess liver fibrosis remains controversial. We compare the utility of liver biopsy and digital image analysis with FibroScan for assessment of CHB in young adults.

Methods Young adult CHB patients were followed in a dedicated clinic and seen 3-monthly. Liver biopsy was performed where indicated and compared with FibroScan scores. Digital image analysis was performed on a selected number of Sirius red stained sections to evaluate percentage fibrosis. 167 patients were assessed; 101/167 (male=63); median age 26 (range 16–30) underwent liver biopsy and were included for analysis.

Results 47/101 patients were eAg+. Overall median ALT was 41IU/L (range 14–426) & HBV DNA was 5.22 logIU/ml (range 1.4–9.3). Median Ishak fibrosis score was 1 (range 0–6); median FibroScan score was 5.95 kPa (range 2.6–35.2). There was no difference in the FibroScan score in patients with advanced (F5/6) and minimal fibrosis (F0/1); median FibroScan scores were 6 and 5.95 respectively, ($p=ns$). The correlation co-efficient between fibrosis and FibroScan was not statistically significant ($p=0.46$). FibroScan scores were confounded by ALT; using Prati criteria to define normal ALT (female <19 IU/l, male <30 IU/l), we noted an ALT twice ULN revealed a higher FibroScan score, regardless of fibrosis ($p=0.05$ and 0.04; males and females respectively). On the contrary, digital image analysis more accurately reflected fibrosis stage irrespective of ALT.

Conclusion A proportion of young adult patients with CHB have significant liver disease on biopsy. This study highlights the limitations of FibroScan in assessing liver fibrosis in this cohort. Our data demonstrates the utility of digital image analysis in benchmarking fibrosis in young patients, potentially providing a more accurate methodology to assess progression of fibrosis over time.

Competing interests None declared.

PMO-149 TENOFOVIR USE IN HEPATITIS B INFECTION IN PREGNANCY

doi:10.1136/gutjnl-2012-302514b.149

G Chakraborty,* S Clark, D Forton. *Department of Hepatology, St Georges University of London, London, UK*

Introduction Antenatal screening and immunoprophylaxis reduces the perinatal transmission of hepatitis B virus but vertical infection may occur with high level viraemia. Antiviral therapy during the 3rd trimester of pregnancy may reduce the incidence of intrauterine infection. Lamivudine treatment reduces vertical transmission if given with immunoglobulin and vaccination in mothers with viral loads $>10^8$ IU/ml. There are no published trials for tenofovir in this context, although its use is supported by safety data from Anti-retroviral Pregnancy Registry in USA (category B) with the added benefit of low viral resistance. Breastfeeding is not recommended as tenofovir is secreted in milk. Discontinuation of tenofovir after delivery carries the risk of hepatitis flares and liver decompensation. There are no guidelines for the use of antivirals in HBV+ve pregnant women and treatment decisions are made on an individual basis.

Methods We initiated tenofovir 245 mg in five HBV monoinfected women in the 3rd trimester to prevent vertical transmission. Demographic, virological and outcome data were collected.

Results The patients were newly diagnosed during antenatal screening. They were all HBeAg+ve with high viral loads and normal ALT, presumed immunotolerant. All women wished to breastfeed and four were advised to stop tenofovir at delivery but

Abstract PMO-149 Table 1

Patient	Age (years)	Ethnicity	Mean ALT (U/L) (pre treatment)	Viral load (IU/ml), pre treatment	3-month Treatment with Tenofovir—stopped at delivery	Mean ALT (U/L) (post treatment)	Viral load—after 3 months
1	29	Chinese	20	2.15×10^8	Stopped 6 days before	20	4 log drop
2	24	African	16	4.6×10^7	Yes	70	2 log drop
3	40	Afghani	24	1.4×10^7	Yes	88	None recorded
4	34	Asian	35	$>1.7 \times 10^8$	Continued after birth	55	6 log drop
5	22	Chinese	23	9.2×10^7	Yes	98	None recorded

one stopped 6 days before birth. 1 mother continued after delivery due to increased ALT during treatment with ultrasound evidence of liver disease. There were no reported adverse effects. During or at the end of treatment four patients had rises in ALT ($>1-2\text{ULN}$) but no jaundice or hepatic decompensation. All the babies were born healthy and received immunoglobulin and vaccination.

Conclusion This small series demonstrates the safety of tenofovir in the last trimester of pregnancy. Small increases in ALT were seen which could be due to pregnancy, the initiation or discontinuation of tenofovir. It is necessary to assess the stage of liver disease to guide the treatment strategy after birth, although this is not always feasible in pregnancy. The timing of tenofovir discontinuation is determined by breastfeeding. We recommended that breastfeeding should start 24 h after treatment cessation, although there is not an evidence base to support this. Long-term prospective studies are indicated to confirm efficacy, safety and to determine optimal discontinuation strategies in relation to breastfeeding.

Competing interests None declared.

PMO-150 SECOND HARMONIC GENERATION MICROSCOPY OF COLLAGEN AND EVALUATION OF LIVER FIBROSIS IN CHRONIC HEPATITIS C (CHC) INFECTION

doi:10.1136/gutjnl-2012-302514b.150

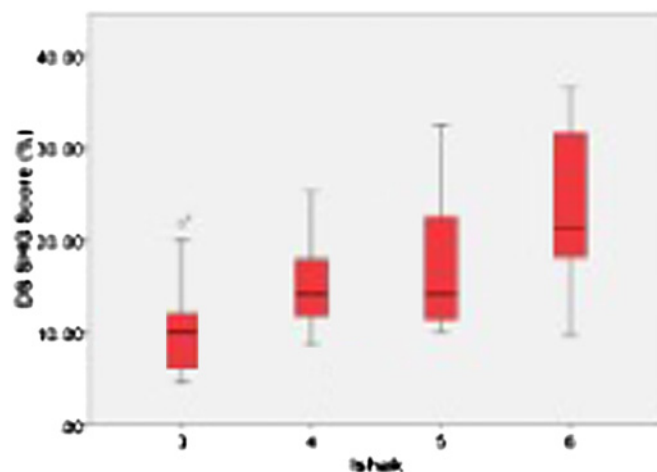
¹G E Dolman, ²D Sevrain, ³C Odin, ²Y Le Grand, ⁴A M Zaitoun, ^{1,5}W L Irving, ¹I N Guha. ¹NIHR BRU NDDC, University of Nottingham, Nottingham, UK; ²Laboratoire de Spectrométrie et Optique Laser, Université de Bretagne Occidentale, Brest, France; ³Institut de Physique de Rennes, Université de Rennes 1, Rennes, France; ⁴Department of Histopathology, Nottingham University Hospitals, Nottingham, UK; ⁵School of Molecular Medical Sciences, University of Nottingham, Nottingham, UK

Introduction There is an urgent need to create tools to quantify collagen in liver fibrosis to facilitate stratification of disease and development of anti-fibrotic agents. Multiphoton microscopy enables imaging of unstained biopsies using endogenous sources of non-linear signals such as Two-Photon Excitation Fluorescence (TPEF) and Second Harmonic Generation (SHG). SHG allows specific detection of non-centrosymmetric structures such as fibrillar collagen, mainly type I. The SHG score is a measure of relative collagen area and is obtained by post-acquisition SHG/TPEF image processing. We have assessed the ability of our method to quantify collagen in advanced fibrosis due to CHC, with respect to Ishak stage (IS).

Methods Biopsies from patients with advanced fibrosis (IS ≥ 3) were selected from 1 centre in the Trent Study of Patients with Hepatitis C Virus, a prospective cohort study formed in 1991. Index biopsies prior to 2008 were selected and notes reviewed for subsequent liver related outcomes (LRO). LRO was defined as variceal bleed, ascites, encephalopathy, HCC or liver related death. SHG was measured on 4 μm FFPE sections. A mask of the biopsy area was created with TPEF. Image processing was performed by two independent researchers, blinded to Ishak stage, using in-house macros and each using different software (Image J & Matlab). PASW 17.0 was used for statistical analysis.

Results The SHG score was acquired in 58 of 83 biopsies (66%). 25 were excluded due to signal artefact from paraffin, obscuring SHG

signal from collagen. There was no significant difference in scoring by two researchers ($p < 0.001$). The median SHG score was 15.96% (IQR 11.3–21.3%). Abstract PMO-150 figure 1 shows the median SHG score for each IS. SHG signal increased with disease severity (IS3:10.1%; IS4:14.1%; IS5:14.1%; IS6:21.2%). LRO occurred in 15 patients after a median of 57 months post-biopsy. The mean SHG score at index biopsy was 19.1% in those with, and 16.6% in those without subsequent LRO (non-significant difference, $p > 0.05$).



Abstract PMO-150 Figure 1

Conclusion SHG has proved to be a valuable method of quantifying collagen in liver fibrosis and does not require standard histochemical stains. Further development of this quantitative measure may result in a tool to assess response to anti-fibrotic therapy and progression to clinical endpoints.

Competing interests None declared.

REFERENCES

- Gailhouse L, et al. Fibrillar collagen scoring by second harmonic microscopy: A new tool in the assessment of liver fibrosis. *J Hep* 2010;**52**:398–406.
- Guilbert T, et al. A robust collagen scoring method for human liver fibrosis by second harmonic microscopy. *Opt Expr* 2010;**18**:25794–807.

PMO-151 EXCELLENT DISEASE FREE AND OVERALL SURVIVAL RATES AFTER LONG TERM FOLLOW-UP OF A COHORT OF INJECTING DRUG USERS TREATED FOR HCV

doi:10.1136/gutjnl-2012-302514b.151

¹H Lewis, ²M Wilkinson, ²J Dalton, ²H Gardner, ³J Hothi, ³N Ibrahim, ²K King, ³M Mirza, ²A Tippett, ²J Turton, ²C Woods, ²S Wynne, ⁴R Igbe, ¹G R Foster. ¹The Liver Unit, Queen Mary University of London, London, UK; ²Specialist Addiction Services, East London NHS Foundation Trust, London, UK; ³Barts and the London School of Medicine and Dentistry, London, UK; ⁴University of Bristol Medical School, Bristol, UK

Introduction Hepatitis C virus (HCV) is common in injecting drug users (IDU's), but $<10\%$ of those known to be infected are