

### Abstract PTU-138 Figure

**Conclusion** Our findings indicate that in asymptomatic volunteers, central obesity and waist belt cause partial hiatus herniation and that waist belt also causes short segment reflux.

**Disclosure of Interest** None Declared

## Oesophagus

### PTU-139 AN UNUSUAL COMPLICATION OF MYELODYSPLASIA

doi:10.1136/gutjnl-2013-304907.229

<sup>1,2</sup>A K Gabr. <sup>1</sup>South Tyneside NHS Foundation Trust, South Tyneside, UK

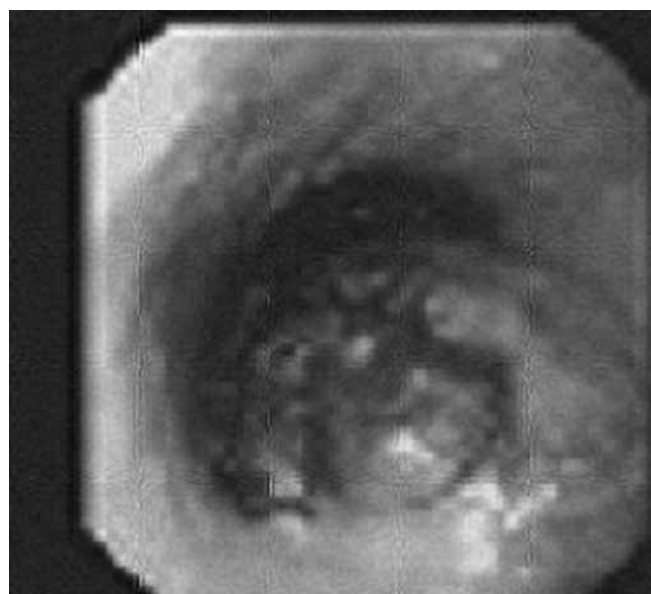
**Introduction** Oesophageal haematoma is a rare clinical entity which is part of the spectrum of oesophageal injuries that includes Mallory-Weiss tear and Boerhave's syndrome. We present a case of oesophageal haematoma as the only complication of myelodysplasia.

**Methods Case presentation** An 81 year old gentleman presented to the emergency department with sudden onset chest pain. He ate a scone and went to bed. Half an hour later, he developed a sharp, retrosternal pain, radiating to the neck. The pain was worse by breathing and swallowing. His past medical history included myelodysplasia and ischemic heart disease. Physical examination was unremarkable. Laboratory investigations showed platelets count of  $59 \times 10^3$ , D. Dimer of 2746 ng/ml. CT pulmonary angiography didn't show any pulmonary embolus but obstructed oesophagus, filled with food up to the middle part. Gastroscopy showed large bluish red mass extending between 23 cm and 40 cm in the Oesophageal lumen, originating from the submucosa. The mass didn't look malignant, therefore, biopsies were not taken. Clinical impression was submucosal oesophageal haematoma. Aspirin was stopped and he was treated conservatively, with liquid diet. Dysphagia improved and he was discharged 4 days later. Complete resolution was shown on follow up CT thorax and gastroscopy 6 weeks later.

**Results Discussion** The first published report of Oesophageal haematoma, from Marks and Keat in 1968, described a small mucosal breach as a constant feature. It is a result of haemorrhage within the oesophageal wall, usually in the submucosa and more often in the distal oesophagus as it is least supported by adjacent structures. The pathogenesis is unclear, Cribblez and colleagues reviewed 91 patients with submucosal haematoma in literature. Precipitating factors were vomiting in 22% of cases, instrumentation in 17%, haemostasis abnormalities in 21% and spontaneous occurrence in 37%. Acute chest pain is a common presentation that should be differentiated from other causes as myocardial infarction. The typical triad of chest pain, haematemesis and dysphagia occurred only in one third of patients. CT typically, shows symmetric or asymmetric oesophageal thickening with concentric or eccentric oesophageal mass with well-defined borders. Gastroscopy is the diagnostic test of choice. Most cases resolve spontaneously within 1–3 weeks with conservative approach. Surgery is only indicated in complicated cases. Angiography is usually considered when endoscopic therapy failed or when surgery is risky.

**Conclusion** Diagnosis of Oesophageal haematoma can be achieved by interpreting symptoms in conjunction with imaging and endoscopy findings at presentation and follow up. Prognosis is favourable, as it usually resolves with conservative management.

**Disclosure of Interest** None Declared



### Abstract PTU-139 Figure

### PTU-140 THE EFFECT OF PROTON PUMP INHIBITORS (PPIS) ON OESOPHAGEAL ACID REFLUX USING A PROLONGED WIRE-LESS BRAVO PH MONITORING

doi:10.1136/gutjnl-2013-304907.230

<sup>1</sup>G Sui, <sup>2</sup>M Fox, <sup>1,2</sup>A Anggiansah, <sup>1</sup>A Vales, <sup>1</sup>T Wong. <sup>1</sup>Oesophageal Lab, Guy's hospital, London; <sup>2</sup>Biomedical Research Unit, Queen's Medical Centre, Nottingham, UK

**Introduction** Recently prolonged catheter-free pH monitoring (Bravo®, Given Imaging, Yoqeam, Israel) up to 96 hours has become possible which enables more physiological evaluation of oesophageal acid exposure and its response to therapeutic interventions. This study applied this technology to measure acid reflux, and reflux related symptoms in patients with proven gastro-oesophageal reflux disease on and off high-dose PPIs. The potential utility of this methodology in guiding medical therapy was assessed.

**Methods** Patients with reflux symptoms were recruited prospectively from Mar.2012 to Oct.2012. PPI was stopped for 7 days prior to the Bravo capsule insertion. The 1<sup>st</sup> 48hr pH recording was performed off PPI and the 2<sup>nd</sup> 48hr was on twice daily PPI. The 48hr pH and symptom data for the two periods were compared, including percentages of acid exposure in total, upright and supine periods and symptom–reflux association for which heartburn (HB), chest pain (CP) and regurgitation (RG) were analysed. Data were expressed as median & interquartile. Wilcoxon signed-rank and Mann Whitney tests were used for statistical analysis (\*P < 0.05; \*\*P < 0.01; \*\*\* < 0.001).

**Results** Data from prolonged pH monitoring up to 96 hours were available from 89 patients of whom 36 (22 males, mean age 50, range 26–76 years old) with complete studies and pathological acid exposure in the 1<sup>st</sup> 48 hours were studied in detail. Acid reflux measurements on PPI therapy were greatly reduced when compared to those recorded off therapy (Table). 27/36 (75%) patients had normal acid exposure on PPI therapy. The overall number of HB and CP reported in the 2<sup>nd</sup> 48hr period was reduced by almost two thirds (13 (4–26) vs.5 (2–14) \*\*); however the number of these symptoms that were actually associated with acid reflux events was almost completely abolished (4 (2–14) vs.1 (0–3) \*\*\*). No effect on volume RG was present.