



Editor's choice  
Scan to access more  
free content

# A global consensus on the classification, diagnosis and multidisciplinary treatment of perianal fistulising Crohn's disease

Krisztina B Gecse,<sup>1,2</sup> Willem Bemelman,<sup>3</sup> Michael A Kamm,<sup>4</sup> Jaap Stoker,<sup>5</sup> Reena Khanna,<sup>6,7</sup> Siew C Ng,<sup>8</sup> Julián Panés,<sup>9</sup> Gert van Assche,<sup>10</sup> Zhanju Liu,<sup>11</sup> Ailsa Hart,<sup>12,13</sup> Barrett G Levesque,<sup>14,15</sup> Geert D'Haens,<sup>1,2</sup> for the World Gastroenterology Organization, International Organisation for Inflammatory Bowel Diseases IOIBD, European Society of Coloproctology and Robarts Clinical Trials

► Additional material is published online only. To view please visit the journal online (<http://dx.doi.org/10.1136/gutjnl-2013-306709>).

For numbered affiliations see end of article.

**Correspondence to** Professor Geert D'Haens, Department of Gastroenterology and Hepatology, Academic Medical Center, University of Amsterdam, Meibergdreef 9, Amsterdam 1105 AZ, The Netherlands; [g.dhaens@amc.uva.nl](mailto:g.dhaens@amc.uva.nl)

Received 3 January 2014  
Revised 17 May 2014  
Accepted 28 May 2014  
Published Online First  
20 June 2014

## ABSTRACT

**Objective** To develop a consensus on the classification, diagnosis and multidisciplinary treatment of perianal fistulising Crohn's disease (pCD), based on best available evidence.

**Methods** Based on a systematic literature review, statements were formed, discussed and approved in multiple rounds by the 20 working group participants. Consensus was defined as at least 80% agreement among voters. Evidence was assessed using the modified GRADE (Grading of Recommendations Assessment, Development, and Evaluation) criteria.

**Results** Highest diagnostic accuracy can only be established if a combination of modalities is used. Drainage of sepsis is always first line therapy before initiating immunosuppressive treatment. Mucosal healing is the goal in the presence of proctitis. Whereas antibiotics and thiopurines have a role as adjunctive treatments in pCD, anti-tumour necrosis factor (anti-TNF) is the current gold standard. The efficacy of infliximab is best documented although adalimumab and certolizumab pegol are moderately effective. Oral tacrolimus could be used in patients failing anti-TNF therapy. Definite surgical repair is only of consideration in the absence of luminal inflammation.

**Conclusions** Based on a multidisciplinary approach, items relevant for fistula management were identified and algorithms on diagnosis and treatment of pCD were developed.

## INTRODUCTION

Penner and Crohn first described perianal fistulas as complications of Crohn's disease (CD) 75 years ago.<sup>1</sup> Population based studies confirmed that perianal fistulas are the most common manifestation of fistulising CD, developing in 20% of Crohn's patients and recurring in approximately 30% of the cases.<sup>2,3</sup> The cumulative incidence of perianal fistulising CD (pCD) is 12% after 1 year and this doubles 20 years after diagnosis.<sup>2</sup> The risk of developing a fistula depends on disease location, being most frequent in colonic disease with rectal involvement.<sup>3</sup> Perianal fistulas impose a significant burden on the patients. Unfortunately there are limitations in the available literature, making it challenging to develop an evidence based approach to pCD. The objective of the working group was to develop a consensus on the classification, diagnosis

and treatment of pCD, based on best available evidence and expert opinion in order to offer guidance to clinicians.

## METHODS

### Working group

The World Congress of Gastroenterology 2013 called for the development of state-of-the-art, evidence based views for designated areas of gastroenterology. An expert consensus group on pCD was formed and a literature review process (summarised in online supplementary figure S1) followed, covering all relevant papers and abstracts until March 2014. The search initially identified 4680 references. A selection process by the research committee members and additional references identified by manual search led to 247 retained articles.

### Consensus process

Four areas of interest were identified: (1) classification and scoring, (2) diagnosis, (3) medical treatment, and (4) surgical management. For each of these areas the research committee drafted statements based on the systematic literature review and developed potential algorithms. These were discussed and revised by the group during their meetings. As a final step all participants voted on each statement, using definitions of agreement previously reported by Bitton *et al.*<sup>4</sup> Consensus was a priori defined as at least 80% agreement. The modified GRADE (Grading of Recommendations Assessment, Development, and Evaluation) criteria were used to establish the strength of recommendations and the quality of evidence (see online supplementary table S1).<sup>5</sup>

## CONSENSUS STATEMENTS

### Section 1: Classification and scoring

Statement 1—General considerations for classification and scoring

1.1 A clinically useful *classification* of perianal fistulas in CD should enable the treating physician to determine optimal management strategy.

*Vote: A+=80%, A=15%, D=5%; grade of recommendation: 1C*

1.2 *Scoring* of perianal fistula activity in CD should enable the treating physician to evaluate disease severity and response to therapy.



CrossMark

**To cite:** Gecse KB, Bemelman W, Kamm MA, *et al.* *Gut* 2014;**63**: 1381–1392.

**Vote:** A+=70%, A=20%, A-=5%, D-=5%; *grade of recommendation:* 1C

**Discussion** Several classification and scoring systems have been developed in an attempt to quantify disease extent and severity of pCD.<sup>6–16</sup> We propose that a distinction is made between a detailed *anatomic description* of perianal fistulas (ie, classification) and the assessment of *fistula activity* (scoring), a dynamic measure that is sensitive to change under treatment. However, both components are necessary to design an optimal therapeutic strategy and are relevant for prognosis (table 1).

#### Statement 2—Fistula activity

Evaluation of fistula activity is recommended both by clinical and radiological (MRI) features.

**Vote:** A+=70%, A=20%, A-=5%, D+=5%; *grade of recommendation:* 2C

**Discussion** The Perianal Disease Activity Index (PDAI) is based on the assessment of quality of life (pain/restriction of activities and restriction of sexual activities) and perianal disease severity (fistula discharge, type of perianal disease, and degree of induration) rated on a five-point Likert scale.<sup>13</sup> It was tested for reliability and responsiveness and was validated against physicians' and patients' global assessments.<sup>13</sup> A cut-off PDAI score >4 resulted in 87% accuracy when using clinical assessment (active fistula drainage and/or signs of local inflammation) as reference.<sup>17</sup> 'Fistula drainage assessment' was first used to quantify fistula healing in a randomised controlled trial (RCT) with infliximab.<sup>14</sup> A fistula was considered 'closed' when it no longer drained despite gentle finger compression. A response was defined as a reduction of 50% or more in the number of draining fistulas on at least two consecutive visits. Fistula remission was defined as the absence of any draining fistulas on two consecutive visits. Although this clinical assessment has been used in further RCTs, it has several drawbacks.<sup>18–20</sup> 'Gentle finger compression' is largely investigator dependent and is an approach that has never been formally validated. Persistent tracts *without* fluid drainage are scored as 'remission'. Moreover, the external appearance of the fistula is used as a surrogate for the whole internal fistula tract. MRI studies have shown that internal fistula healing lags behind clinical remission by a median of 12 months.<sup>21</sup> The site of a former/residual fistula tract could be the path of least resistance for a new or recurrent fistula tract to occur.<sup>22</sup> In an attempt to combine anatomical fistula description and features reflecting active inflammation, van Assche *et al*<sup>16</sup> developed an MRI based scoring system. Anatomical components include the number and course of the fistula tracts, while the activity of inflammation was evaluated by hyperintensity of fistula tracts on T2 weighted MRI images, the presence of abscess and proctitis.<sup>16</sup> The score was validated against the PDAI but had a weak correlation

( $r=0.371$ ,  $p=0.036$ ).<sup>22</sup> One year of infliximab therapy was associated with significant improvement of the Van Assche score, particularly for the item T2 hyperintensity.<sup>23</sup> Disappearance of contrast enhancement was the only MR feature associated with clinical remission.<sup>23</sup> In a more recent study, this score was found to be insensitive to change in patients with reduced fistula calibre during long term follow-up.<sup>21</sup> Recently, perianal fistula length assessed by MRI was found to be a predictor of response to treatment.<sup>24</sup> In conclusion, improved instruments to score perianal CD fistula activity are needed.

#### Statement 3—Fistula anatomy

**3.1** The course of the fistula tract in relation to the anal sphincter and the levator plate (superficial, intersphincteric, transsphincteric, suprasphincteric, extrasphincteric, and supralelevator or infralevator) is an important component for *classification*.

**Vote:** A+=90%, A=5%, D-=5%; *grade of recommendation:* 2B

**3.2** High and low transsphincteric fistulas should be distinguished in the classification. Fistulas are defined as low when the tract runs through the lower one third of the external anal sphincter.

**Vote:** A+=70%, A=20%, A-=10%; *grade of recommendation:* 2C

**Discussion** Parks *et al*<sup>6</sup> studied the anatomy of perianal fistulas and the associated risk of post-surgical incontinence in 400 consecutive patients, as illustrated in figure 1. Section 4 describes the impact of fistula anatomy on surgical treatment.

#### Statement 4—Proctitis

The presence of proctitis, defined as any ulceration and/or stricture in the rectum, or inflammation and/or stricture of the anal canal, is an important component for fistula assessment.

**Vote:** A+=90%, A=10%; *grade of recommendation:* 1C

**Discussion** The presence of proctitis is highly relevant for fistula management and prognosis as discussed in detail in sections 3 and 4.

#### Statement 5—Abscess

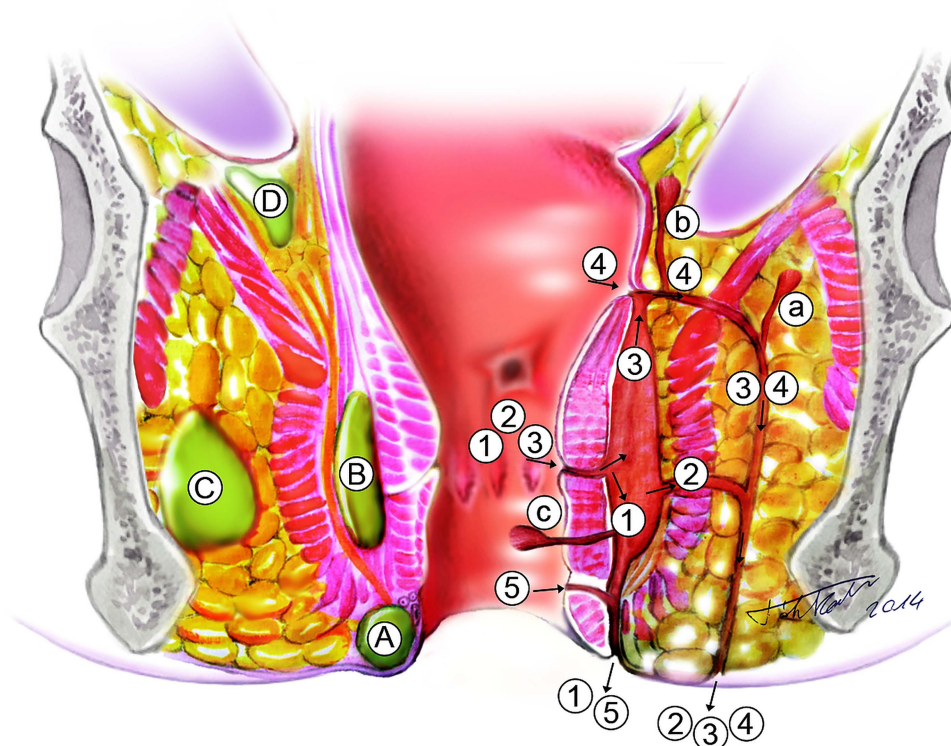
A perianal abscess clinically defined as fluctuation and radiologically defined as a confined fluid collection (a hyperintense lesion on T2 weighted MRI images and/or a hypo- or anechoic area with endoanal ultrasound (EUS)) with a rim of inflammatory tissue (rim enhancement on post-contrast T1 weighted MRI images and/or often poorly demarcated lesions on EUS) is an important component for classification.

**Vote:** A+=55%, A=35%, A-=10%; *grade of recommendation:* 2C

**Discussion** Perianal CD fistulas are frequently accompanied by abscess formation. Timely detection and management of abscesses minimises the risk of further septic complications. Items found to be clinically relevant for fistula management are depicted in figure 1.

**Table 1** Descriptive and dynamic measures to evaluate perianal fistulas

Descriptive	Dynamic	
	Clinical	Clinical and MRI
Milligan and Morgan	Present <sup>11</sup>	Van Assche Score <sup>16</sup>
Parks/modified Parks <sup>6</sup>	Anal Disease Activity Index <sup>12</sup>	
Buchmann/Alexander-Williams <sup>7</sup>	Perianal Disease Activity Index (PDAI) <sup>13</sup>	
Cardiff <sup>8</sup>	Fistula Drainage Assessment <sup>14</sup>	
St James University Hospital <sup>9</sup>	Pikarsky's Perianal Crohn's Disease Activity Index <sup>15</sup>	
AGA Technical Review <sup>10</sup>		



**Figure 1** Disease characteristics relevant for fistula management. A fistula is a tract of pus and/or granulation tissue between two epithelial surfaces lined with a fibrous wall.<sup>10</sup> Primary tracts are connections between the internal and external openings (1–5), while secondary tracts are blind extensions (a–c). A tract is defined 'low' when it runs through the lower one third of the external anal sphincter.<sup>6</sup> The *course of the fistula tracts* is described by the Parks classification. The external sphincter complex, defined by the external sphincter and the puborectal muscle, serves as reference: (1) intersphincteric: the tract penetrates the internal sphincter and runs through the intersphincteric space to the perianal skin; (2) transsphincteric: the tract penetrates both the internal and the external sphincter or the puborectal muscle; (3) suprasphincteric: tract runs first upwards in the intersphincteric space, then downwards crossing the levator ani muscle and then reaching the perianal skin; (4) extrasphincteric: tract originates from the rectal wall and runs down through the levator ani muscle, without penetrating the external sphincter or the puborectal muscle.<sup>6</sup> Later a fifth category was added for superficial tracts (5) that did not involve the sphincter complex. *Secondary tracts* and their relationship to the levator plate (a) infralevator or (b) supralevator and (c) horizontal extension, also known as 'horseshoes', are distinguished. Furthermore *proctitis* and the presence of *abscesses* with regard to their localisation (A, perianal; B, intersphincteric; C, ischiorectal; D, suprasphincteric) are also noted.

## Section 2: Diagnosis and follow-up

### Statement 6—Endoscopy

Endoscopic assessment of the rectum is essential to determine the most appropriate management strategy.

*Vote:* A+=85%, A=10%, A-=5%; *grade of recommendation:* 1C

**Discussion** Endoscopy allows assessment of the extent and severity of luminal inflammation, and the presence of internal openings and other complications such as strictures and cancer.<sup>25</sup> Proctitis is a predictive factor of persistent non-healed fistula tracts and higher proctectomy rate.<sup>26</sup>

### Statement 7—Examination under anaesthesia

Examination under anaesthesia (EUA) has an important role in the diagnosis and classification of pCD. It also allows immediate therapeutic intervention such as abscess drainage and/or seton placement. If a perianal abscess is suspected, EUA with drainage is the procedure of choice and should not be delayed if MRI is not immediately available. However, if additional collections are suspected, imaging is necessary.

*Vote:* A+=50%, A=35%, A-=10%, D-=5%; *grade of recommendation:* 1C

**Discussion** Experienced colorectal surgeons are up to 90% accurate (95% CI 78% to 98%) in detecting and classifying

perianal fistulas, sinuses, and abscesses.<sup>27</sup> As shown in a study with infliximab, higher success rates and lower recurrence rates were attained in patients who underwent EUA with abscess drainage and seton placement before starting anti-tumour necrosis factor (anti-TNF) treatment.<sup>28</sup>

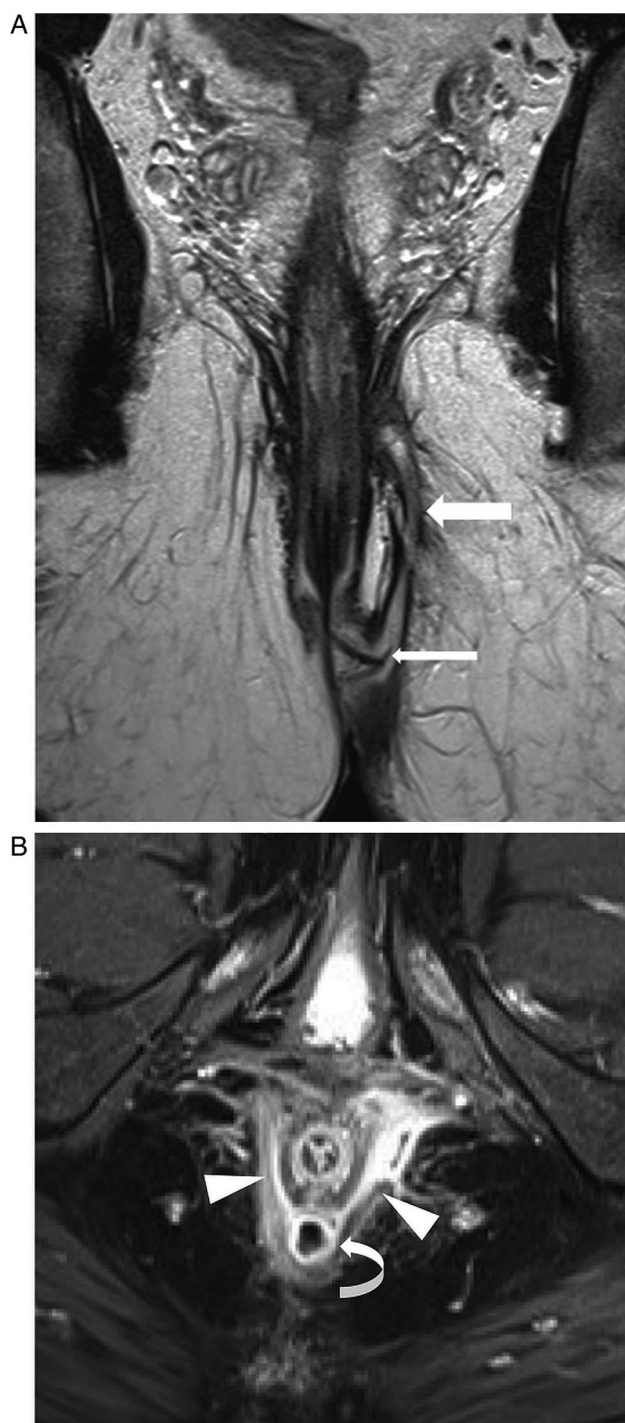
### Statement 8—MRI

**8.1 Pelvic MRI** is a highly accurate non-invasive modality for the diagnosis and classification of perianal fistulas; therefore it is considered the gold standard imaging technique for perianal CD. MRI provides additional detailed information on luminal disease location, disease severity, and fluid collections.

*Vote:* A+=90%, A=10%; *grade of recommendation:* 1B

**Discussion** MRI accurately visualises the anal sphincter and the pelvic floor muscles, as well as the fistula tracts and abscesses, with an accuracy ranging from 76–100% (figure 2).<sup>29–32</sup> In addition, MRI may identify clinically 'silent' abscesses and luminal inflammation (figure 3).<sup>33</sup> T2 weighted sequence with fat suppression is the optimal technique for MR fistula imaging. A gadolinium enhanced T1 weighted sequence is useful for the differentiation between fluid/pus and granulation tissue (table 2). Phased-array external coils have larger field of view with good coverage for supralevator fistulae.<sup>30</sup> Endoanal coils provide an



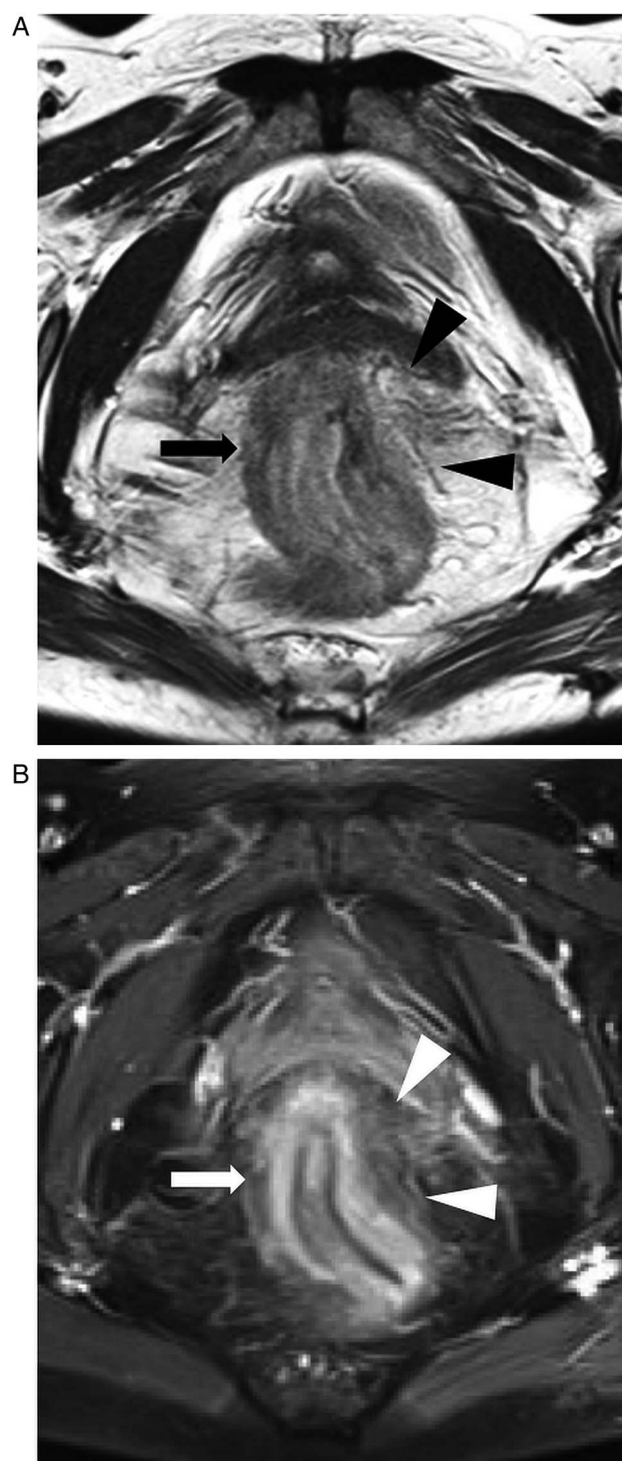


**Figure 2** Representative MR image of a male patient with perianal fistulising Crohn's disease. (A) Coronal oblique T2 weighted turbo spin-echo sequence and (B) axial oblique fat saturated T1 weighted turbo spin-echo sequence demonstrate a transsphincteric fistula (arrow) with a seton in place (thin arrow), an intersphincteric abscess (curved arrow) with bilateral granulation tissue filled extensions (arrowheads) in the puborectal muscle.

advantage in identifying internal openings; however, they are less widely available and have a restricted field of view.<sup>34</sup>

#### Statement 9—Endoanal ultrasound

EUS (with or without hydrogen peroxide) is a useful alternative to MRI in diagnosing perianal CD fistulas; however, accuracy can be limited by its restricted view.



**Figure 3** Representative MR image of a female patient with perianal fistulising Crohn's disease and proctitis. (A) Axial oblique T2 weighted turbo spin-echo sequence and (B) axial oblique fat saturated T1 weighted turbo spin-echo sequence show a thickened rectal wall (arrow), with increased enhancement and surrounding infiltrate (arrowheads).

*Vote:* A+=50%, A=45%, D-=5%; *grade of recommendation:* 2B **Discussion** EUS (with a frequency between 5–16 MHz) allows a detailed visualisation of the anal sphincter complex with accuracy between 86–95% for correct classification and 62–94% for identification of internal openings.<sup>35–37</sup> However, EUS cannot accurately identify ischioanal fossa or supralelevator abscesses, as the penetration is limited.<sup>27</sup> The use of endoluminal probes can

**Table 2** Interpretation of MRI

	T2	Post-contrast T1
Fistula tract		
Fibrosis	Hypointense	No enhancement
Pus/fluid	Hyperintense	No or rim only enhancement
Granulation tissue	Hyperintense	Enhancement
Abscess	Hyperintense	Rim enhancement

be restricted by luminal stenosis. In selected cases, local infusion of hydrogen peroxide or colour Doppler EUS with saline injection improves visualisation.<sup>38–40</sup> When prospectively comparing hydrogen peroxide enhanced three dimensional EUS and endoluminal MRI with surgical assessment as reference, 81% and 90% agreement was found, respectively.<sup>41</sup> Furthermore, the Crohn's Ultrasound Fistula Sign (CUFS) can differentiate between Crohn's related and cryptogenic fistulae-in-ano with a positive and negative predictive value of 87% and 93%, respectively.<sup>42</sup> As a complementary method, the accuracy of transperineal ultrasound to detect and classify fistulas was found to be comparable to EUS. However, its accuracy to diagnose deep abscesses is low (47.1%) due to restricted field of view.<sup>43</sup> Transperineal ultrasound may offer an advantage in detecting anovulvar fistulae (88.9% vs 44.4% when compared with MRI).<sup>43</sup> Both EUS and MRI are superior to clinical examination when assessing and monitoring perianal fistulas.<sup>27 44–46</sup> In a meta-analysis of four studies comparing EUS and MRI, performance characteristics for MRI (0.87, 95% CI 0.63 to 0.96) and EUS (0.87, 95% CI 0.70 to 0.95) demonstrated comparable sensitivities in detecting perianal fistulas. The specificity for MRI (0.69, 95% CI 0.51 to 0.82) was higher than that for EUS (0.43, 95% CI 0.21 to 0.69).<sup>47</sup> A comparison of EUS and MRI diagnostic features is summarised in table 3. The choice mainly depends on local availability, expertise and the complexity of the pCD.

#### Statement 10—Fistulography and CT

The diagnostic accuracy of fistulography and CT is poor in the diagnosis and classification of Crohn's perianal fistulas. Fistulography can, however, provide additional information in some exceptionally complex fistulas.

*Vote:* A+=50%, A=35%, A-=5%, D=5%, D-=5%; *grade of recommendation:* 1C

**Table 3** EUS and MRI in the diagnosis of Crohn's perianal fistulas

	EUS	MRI
Simple fistulas	+++	+++
Complex fistulas	++	+++
High tracts	++	+++
Abscess	++	+++
Internal openings	+++	++*
Availability	-/+++	+ / ++
Costs	+++	+ / ++
Overall accuracy	62.5–95%	76–100%

Modified from Gece *et al.*<sup>108</sup>

\*Sensitivity of MRI to detect internal openings can be enhanced by the use of endoanal coils. However, their use is not widely available. EUS, endoanal ultrasound.

**Discussion** Fistulography and CT are outdated modalities in the diagnostic evaluation of pCD because of exposure to radiation and poor visualisation of the anatomic relationship of the fistulas to the pelvic floor muscles.<sup>48</sup> Only in highly selected cases may fistulograms offer additional information and influence surgical management.<sup>49</sup>

#### Statement 11—Combination of diagnostic modalities

To ensure diagnostic accuracy and to determine an optimal management strategy, a combination of diagnostic modalities is recommended, namely endoscopy and MRI/EUS (depending on availability and expertise) and EUA.

*Vote:* A+=60%, A=20%, D=10%, D-=10%; *grade of recommendation:* 2C

**Discussion** In a prospective study of 32 patients with perianal CD the accuracy of each diagnostic modality was excellent (EUS 91%, EUA 91%, MRI 87%) and the combination of EUA with MRI or EUS increased accuracy to 100%.<sup>27</sup> A diagnostic algorithm for Crohn's perianal fistulas is proposed in figure 4.

### Section 3: Medical treatment

#### Statement 12—Treatment goals

The short term goals in the treatment of pCD are abscess drainage and reduction of symptoms. The long term goals are resolving fistula discharge, improvement in quality of life, fistula healing, preserving continence, and avoiding proctectomy with stoma.

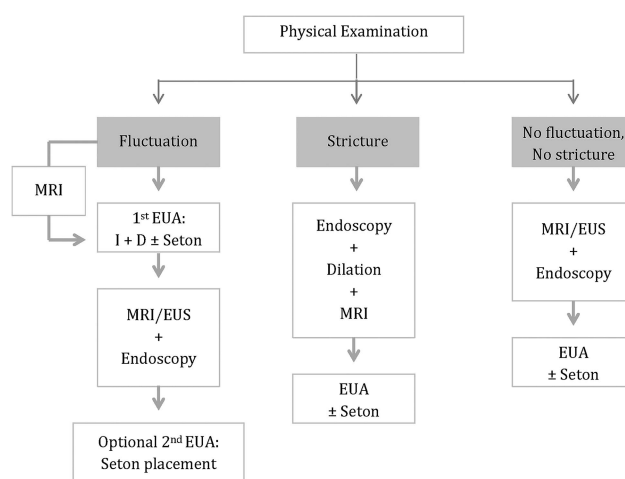
*Vote:* A+=90%, A=10%; *grade of recommendation:* 1C

#### Statement 13—Corticosteroids and aminosaliclates

There is no demonstrated role for aminosaliclates or corticosteroids in perianal CD.

*Vote:* A+=90%, A=10%; *grade of recommendation:* 1C

**Discussion** Aminosaliclates have no clinical effect on perianal CD.<sup>50</sup> Studies evaluating the effect of corticosteroid treatment



**Figure 4** Diagnostic algorithm for perianal fistulising Crohn's disease. In perianal abscess is suspected, MRI is an optional diagnostic method, if readily available, before surgical incision and drainage. Alternatively diagnostic endoscopy can also be performed during examination under anaesthesia (EUA), to minimise patient discomfort. A second EUA might be necessary if seton placement is needed or was not successful upon the first EUA. When stricture is present, Bougie or gentle finger dilation is preferable to preserve sphincter function. EUS, endoanal ultrasound.

in fistulising CD showed worsening of discharge and increased need for surgery.<sup>51</sup>

#### Statement 14

Antibiotics, namely metronidazole and ciprofloxacin, improve fistula symptoms and may contribute to healing.

*Grade of recommendation: 1C*

Therefore, antibiotics are only recommended as adjunctive treatments for fistulas.

*Vote: A+=74%, A=16%, A-=10%; grade of recommendation: 2C*

#### Discussion

Early small and uncontrolled series reported fistula improvement after 6–8 weeks of antibiotic therapy (metronidazole 750–1500 mg/day, ciprofloxacin 500–1000 mg/day) with frequent relapse upon discontinuation and commonly occurring side effects.<sup>52–54</sup> Only one RCT comparing ciprofloxacin, metronidazole and placebo assessed the efficacy of systematic antibiotics for pCD.<sup>55</sup> This short (10 weeks) and underpowered study (n=25) showed no difference between antibiotics and placebo for fistula closure.<sup>55</sup> Neither topical nor systemic metronidazole led to improvement of PDAI in prospective though small trials.<sup>56 57</sup>

Two double blind RCTs assessed the efficacy of ciprofloxacin combined with anti-TNF therapy.<sup>58 59</sup> The first study combined ciprofloxacin with infliximab (n=24) and reported fistula response at week 18 in 73% of patients, versus 39% with infliximab alone (p=0.12).<sup>58</sup> In another RCT the effect of combination therapy with ciprofloxacin and adalimumab was superior to adalimumab monotherapy (in the reduction of at least 50% of the number of draining fistula in 70.6% vs 47.2% (p=0.047)) at week 12.<sup>59</sup> However, after discontinuation of ciprofloxacin the difference between the two groups diminished. Overall these results support the efficacy of antibiotics in reducing fistula drainage but not fistula healing.

#### Statement 15

Thiopurines may have a moderate effect in the treatment of pCD. Evidence for the efficacy of methotrexate and ciclosporin is limited. Tacrolimus is effective for treating active fistulas; when used, therapeutic drug monitoring is required to minimise toxicity.

*Vote: A+=32%, A=32%, A-=26%, D+=10%; grade of recommendation: 2C*

#### Discussion

**Thiopurines** There is no prospective controlled trial involving azathioprine or 6-mercaptopurine with fistula outcome assessed as the primary end point. Available results are derived from a subgroup analysis of a randomised double blind study, where 31% of patients treated with 6-mercaptopurine experienced complete fistula closure compared to 6% of the placebo patients.<sup>11</sup> A recent meta-analysis excluding the above study did not show any efficacy of azathioprine for improving or closing fistulae (OR 4.68, 95% CI 0.6 to 36.69; p=0.14, n=18).<sup>60</sup> In contrast, an earlier meta-analysis assessing the efficacy of thiopurines in 70 patients showed that 54% of patients treated with thiopurines had fistula healing versus 21% of patients treated with placebo (OR 4.44, 95% CI 1.5 to 13.2).<sup>61</sup> The effect of antibiotic and azathioprine combination therapy was evaluated in a prospective open label study and showed the superiority of the combination therapy (p=0.03).<sup>62</sup>

**Methotrexate** There are no clinically relevant trial data on the effect of methotrexate on draining fistulas.

**Tacrolimus** A single, short term, placebo controlled trial randomised 46 patients with actively draining Crohn's fistulas to treatment with oral tacrolimus or placebo.<sup>18</sup> The primary end point—defined as the closure of at least 50% of fistulas maintained for at least 4 weeks—was reached in 43% on active treatment versus 8% on placebo (p=0.004). However, complete closure of all fistulas was not more common in the tacrolimus group.<sup>18</sup> There was more nephrotoxicity with tacrolimus, which was managed by dose reduction.<sup>18</sup> Topical tacrolimus showed no significant benefit.<sup>63</sup>

**Ciclosporin** Several observational studies reported on the efficacy of ciclosporin for fistulising CD. Clinical improvement was rapid, but relapse rates were high after drug discontinuation.<sup>64–66</sup> Related adverse events limited further use of ciclosporin.

#### Statement 16

Infliximab (*grade of recommendation: 1A*) and adalimumab (*1B*) are moderately effective for the induction and maintenance of fistula closure. Evidence for efficacy of certolizumab pegol is weaker (*1C*). Anti-TNF and thiopurine combination therapy may lead to higher fistula healing response and closure rate compared to monotherapy (*2C*).

*Vote: A+=26%, A=42%, A-=16%, D=11%, D+=5%.*

#### Discussion

**Infliximab** Two RCTs have assessed the efficacy of infliximab in fistulising CD. In the first placebo controlled trial an induction regimen induced closure of at least 50% of fistulas for at least 4 weeks in 56–68% of patients compared with 26% treated with placebo (p=0.002 and p=0.02, respectively). Closure of all fistulas was achieved in 38–55% on infliximab.<sup>67</sup> The ACCENT II trial further evaluated infliximab maintenance therapy for this indication. Week 14 responders to the induction regimen were randomised to further treatment with placebo or infliximab 5 mg/kg every 8 weeks.<sup>68</sup> Time to loss of response was significantly longer on infliximab (>40 weeks) than on placebo (14 weeks, p=0.001). Moreover, 39% of patients who received infliximab maintenance therapy had complete closure of all draining fistulas at week 54.<sup>68</sup>

**Adalimumab** There has not been a dedicated controlled trial for fistulising CD with adalimumab. In two placebo controlled trials, CLASSIC-1 and GAIN, the rates of fistula improvement and remission did not differ significantly in adalimumab treated patients at week 4 compared to placebo.<sup>69 70</sup> In the CHARM trial—a 56-week phase III trial to assess the efficacy of maintenance treatment with adalimumab among responders to induction treatment—a subgroup analysis in patients with draining fistula(s) at baseline showed complete fistula healing in 33% of adalimumab treated patients versus 13% of placebo treated patients (p<0.05).<sup>20</sup> An open label extension of this trial showed sustained healing in 90% of patients on adalimumab treatment at 2 years follow-up.<sup>71</sup> In further open label studies, adalimumab was effective in 23–29% of patients with fistulising CD who had lost response or become intolerant to infliximab.<sup>72–74</sup>

**Certolizumab** Subgroup analysis of PRECISE 1 and 2—two large trials assessing the efficacy of certolizumab pegol for moderate to severe CD—looked at fistula response. At week 26, 36% of patients on certolizumab pegol had complete fistula closure compared with 17% on placebo (p=0.038).<sup>75</sup> In contrast, no statistical difference was found in the rate of fistula response, defined as >50% closure at two consecutive visits.<sup>75</sup>



A meta-analysis also evaluated the efficacy of anti-TNFs in pCD, and infliximab was found to have the most available evidence.<sup>76</sup>

**Immunosuppression + anti-TNFs** Data remain conflicting concerning the efficacy of concomitant immunosuppression with anti-TNF agents in pCD. Subgroup analysis of the ACCENT II trial found that concomitant immunosuppressants did not improve response rates to infliximab at 1 year.<sup>68</sup> In the SONIC trial 12% of patients had perianal fistulas, but no separate analysis was performed in this group. Nevertheless, the gain with combination therapy is of particular interest in patients with proctitis.<sup>77</sup> In support, recent studies suggest a clear association between combination therapy and fistula closure.<sup>78</sup>

**Surgery and anti-TNFs** In a large retrospective cohort, 218 patients underwent surgery alone or surgery plus biological therapy. Surgery included seton drainage, fistulotomy, rectal advancement flap, fistulotomy plus seton or other procedures. Clinical response was 35.9% in the surgery treated group and 71.3% in the combined treatment group ( $p=0.001$ ), suggesting that combined treatment modalities offer a better outcome.<sup>79</sup>

Experimental medical treatments are discussed in the online supplementary material.

## Section 4: Surgical management

### Statement 17—Abscess drainage

Surgical drainage of perianal abscesses is generally recommended before initiating medical therapy.

**Vote:** A+=100%; *grade of recommendation:* 1C

**Discussion** In symptomatic perianal CD fistulas are frequently preceded or accompanied by perianal abscesses.<sup>80</sup> Surgical drainage as opposed to spontaneous drainage minimises the risk of further septic complications aggravated by concomitant immunosuppressive treatment.<sup>81</sup>

### Statement 18—Setons

Non-cutting seton placement is useful in order to prevent (recurrent) abscess formation.

**Vote:** A+=85%, A=15%; *grade of recommendation:* 1C

**Discussion** As all fistulas are potential sources of pelvic sepsis, ensuring adequate drainage is fundamental. Seton drains maintain patency of the fistula tracts and hence limit recurrent abscess formation.<sup>82</sup> Loose setons preserve the integrity of the external anal sphincter and are to be preferred.<sup>83</sup> In contrast, cutting setons carry a high risk of anal incontinence (54%) due to scarring of the anal canal.<sup>84</sup> A disadvantage of setons is that the fistula tract cannot 'close' with the seton in place. The optimal timing for seton removal is not well established. In the ACCENT 2 study, all setons were removed by week 2 and the overall new abscess rate was 15%. Several other studies report maintaining seton(s) in situ for longer, thus seton removal at week 2 may be too early.<sup>19 85</sup> In a small prospective trial, where setons were maintained for the duration of infliximab induction, the overall new abscess rate was 0%.<sup>81</sup> These results show that loose seton drainage is an efficient and safe method in the treatment of Crohn's perianal fistulas. It is recommended to keep the seton in place until at least the induction of the anti-TNF treatment period has been completed. Fistula closure can be achieved after seton removal.

### Statement 19—Proctitis

The surgical treatment of pCD in patients with proctitis is limited to abscess drainage and non-cutting seton placement.

Further surgical attempt for fistula closure is recommended only after endoscopic remission of the proctitis has been achieved.

**Vote:** A+=70%, A=30%; *grade of recommendation:* 1C

**Discussion** Both proximally active luminal disease, causing increased bowel frequency, and proctitis are associated with problematic wound healing.<sup>86</sup> Combined infliximab therapy and surgery has been more successful in the absence of luminal inflammation, especially when localised in the rectum.<sup>87</sup> Proctitis is also associated with a higher proctectomy rate (29–77.6%).<sup>26 88</sup> Therefore, active luminal disease in pCD is an indication for aggressive medical treatment.<sup>88</sup>

### Statement 20—Fistulotomy

Fistulotomy is a treatment option for symptomatic superficial and, occasionally, low intersphincteric fistulas, always with consideration for preservation of continence. Performing fistulotomy in low transsphincteric fistulas, especially if anteriorly located in women, is associated with a high risk of incontinence.

**Vote:** A+=60%, A=35% A–=5%; *grade of recommendation:* 2C

**Discussion** In symptomatic superficial, low intersphincteric and selected low transsphincteric fistulas, fistulotomy or lay-open is a safe method, which preserves the continence and offers high healing and low recurrence rates in the absence of proctitis (table 4). In contrast, fistulotomy for high transsphincteric, suprasphincteric and extrasphincteric fistulas is associated with decreased healing and increased incontinence rates.<sup>89</sup> Furthermore, as the anterior part of the external anal sphincter is shorter in women, fistulotomy for low transsphincteric fistulas carries a higher risk of incontinence.

### Statement 21—Definitive surgical repair

Options for definitive surgical repair of pCD include fistulotomy, mucosal advancement flaps (MAFs), bioprosthetic plugs, and ligation of the intersphincteric fistula tract (LIFT). The use of fibrin glue and stem cell injections is not well established yet.

**Vote:** A+=20%, A=35%, A–=40%, D=5%; *grade of recommendation:* 2C

### Discussion

**Mucosal advancement flap (MAF)** is a surgical treatment option for the closure of internal fistula openings. It entails mobilisation of a rectal mucosal flap to cover the primary fistula opening, thereby closing the high pressure end of the fistula,

**Table 4** Fistulotomy in low fistulas

Study	Patients	Healing (%)	Recurrence (%)	Incontinence (%)
Hobbiss and Schofield <sup>109</sup>	32	90	22	ns
Keighley and Allan <sup>110</sup>	12	8	ns	50
Williams <i>et al</i> <sup>89</sup>	41	93	ns	21
Halme and Sainio <sup>111</sup>	10	100	40	50
Scott and Northover <sup>112</sup>	27	81	ns	19
McKee and Keenan <sup>113</sup>	34	62	18	ns
Michelassi <i>et al</i> <sup>114</sup>	33	82	ns	ns
Lozynsky <sup>115</sup>	30	83	17	10
van Koperen <i>et al</i> <sup>116</sup>	28	82	18	66

ns, not stated.

**Table 5** Fibrin glue

Study	Type	Patients	FU	Endpoint
Grimaud <i>et al</i> <sup>117</sup>	RCT	77	8 weeks 37 months (median)	Clinical remission: 38% vs 16% placebo (p=0.04) 18%
Lindsey <i>et al</i> <sup>118</sup>	RCT	42	12 weeks	Cessation of drainage: Simple: 50% vs 100% fistulotomy (p=0.06) Complex: 69% vs 13% seton±flap (p=0.003)
Witte <i>et al</i> <sup>119</sup>	OL	34	7 months (median)	Fistula closure: 55%
Vitton <i>et al</i> <sup>120</sup>	OL	14	3 months 23 months (median)	Fistula closure: 71% 57%
de Parades <i>et al</i> <sup>121</sup>	OL	30	4 weeks 12 months (median)	Fistula closure: 57% 50%
Loungnarath <i>et al</i> <sup>122</sup>	Retro	13 (Crohn)	26 months (median)	Fistula closure: 31%
Zmora <i>et al</i> <sup>123</sup>	Retro	24	12 months (mean)	Fistulae closure: 33%
Sentovich <sup>124</sup>	Retro	20	10 months (mean)	Fistula closure: 85%

FU, follow-up; OL, open label; RCT, randomised controlled trial; Retro, retrospective.

whereas the sphincter complex remains untouched. The excluded fistula segment is expected to dry out over time. In a systematic review of 35 studies with an average follow-up of 28.9 months, the success rate of MAF for Crohn's fistulas was 64% (range 33.3–92.9%). The incontinence rate was 9.4% with a wide interstudy variability (range 0–28.6%). Re-interventions were needed in almost 50% of patients.<sup>90</sup>

**Plugs**, made of collagen, or more recently porcine intestinal submucosa, are inserted via the internal fistula opening to fill the fistula tract and leave the sphincter apparatus untouched. Success rates in retrospective cohorts and one open label study with a median follow-up of 6–15 months varied between 24–88%.<sup>91–94</sup> One of the studies reported that failure was caused by dislodgement of the plug in 22% of the cases; however, the closure rate was reported as excellent (87%) when a suturable bioprosthetic plug was used.<sup>95</sup> In general, plugs may offer a valid first line option for surgical treatment; measures to prevent dislodgement and perioperative antibiotics may increase success and safety, although costs can be a major concern.

**Ligation of the intersphincteric fistula tract (LIFT)** is a surgical option in the management of transsphincteric fistulas when the tract has matured into a fibrotic tube with granulation tissue enabling ligation and transection.<sup>96</sup> The procedure is based on closure of the internal opening and removal of infected tissue via an intersphincteric approach. In the first small case series, a 94% success rate was reported and these results were confirmed by a pilot study including 40 patients.<sup>96–97</sup> A recent study showed more moderate success rates (56% healing >1 year) and all recurrences were within 2 months after the surgery.<sup>98</sup> Prospective studies with higher numbers of Crohn's patients are further awaited.

**Fibrin glue** consists of fibrinogen and thrombin. Upon mixing, a fibrin clot is formed, which is thought to stimulate wound healing by inducing angiogenesis and fibroblast growth. Data show varying success rates for fistula closure, which may

be due to the heterogeneity of the studies regarding fistula origin (Crohn's vs cryptoglandular) and follow-up (table 5). A meta-analysis found no significant difference between fibrin glue and conventional surgery with regard to recurrence and faecal incontinence rates.<sup>99</sup>

**Stem cell based therapy** Mesenchymal stem cells have a high degree of plasticity and ability to modulate immune cells. Peri- or intrafistular injection of autologous expanded adipose derived stem cells, as well as bone marrow derived stem cells, were previously proven to be feasible and safe.<sup>100–102</sup> Initial results show that stem cell±fibrin glue treatment induces fistula closure in 56–82% of patients (vs 16% in the fibrin glue treated patients, p<0.001), and 53% and 30% of patients sustained fistula remission at 1 and 3 years, respectively.<sup>103–106</sup> Although these initial results on stem cell based therapy seem promising, results of further randomised, placebo controlled, ongoing trials on Crohn's fistulas are needed.

**Gracilis muscle transposition** In a single retrospective study including 18 CD patients, gracilis transposition was successful for complex fistulas in 64% and for persistent non-healing perineal sinuses in 50% of the cases with maintained efficacy (90% upon 10 months median follow-up).<sup>107</sup>

#### Statement 22—Diverting stoma

A diverting temporary stoma is an option for patients with severe, complicated, therapy refractory pCD.

*Vote: A+=80%, A=20%; grade of recommendation: 1C*

#### Statement 23—Proctectomy

Transperineal intersphincteric close rectal proctectomy with permanent stoma is the treatment of last resort in severe, therapy refractory fistulising disease.

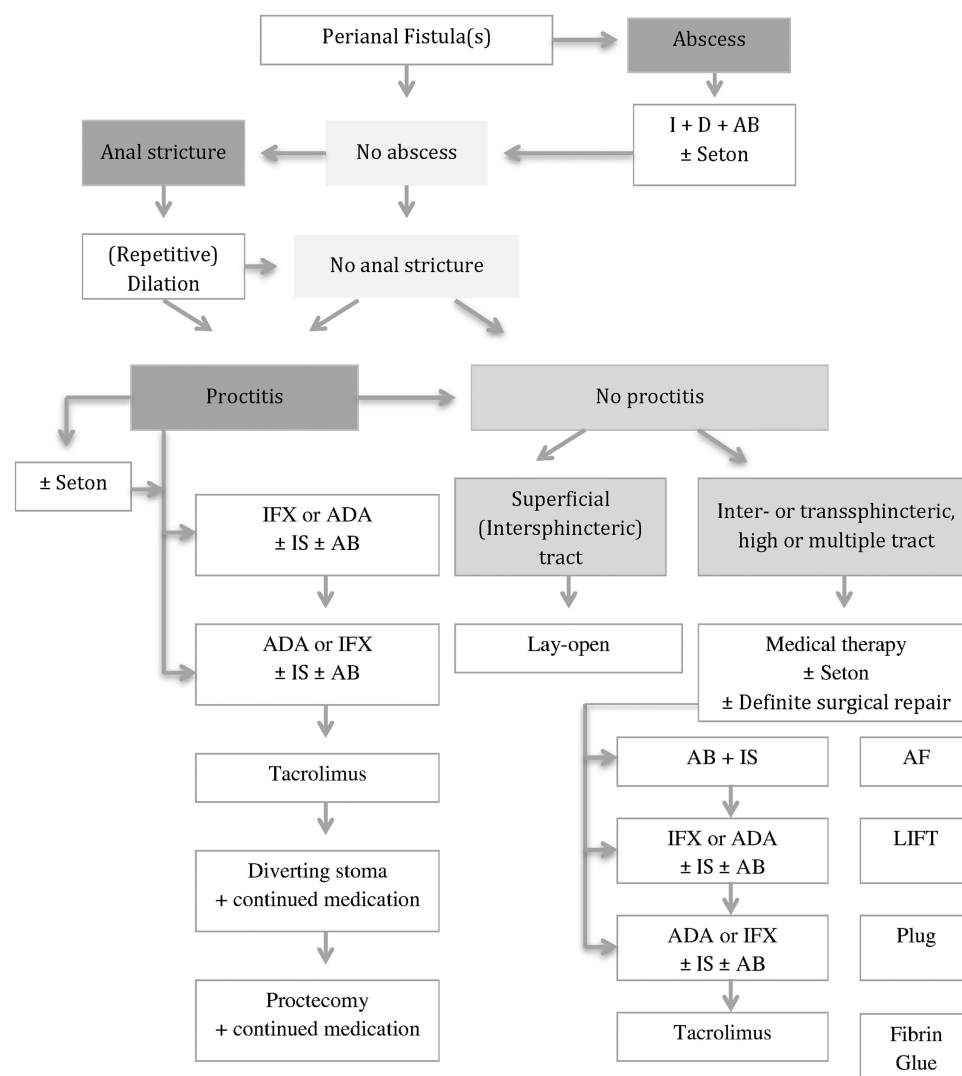
*Vote: A+=60%, A=35%, A-=5%; grade of recommendation: 1C*

**Table 6** Diverting stoma and proctectomy

Study	Patients	FU (months)	Sustained remission (%)	Proctectomy (%)	Restored (%)
Yamamoto <i>et al</i> <sup>125</sup>	31	103 (13–332)	26	68	10
Bell <i>et al</i> <sup>126</sup>	34	ns	ns	53	ns
Guillem <i>et al</i> <sup>126</sup>	28	72 (24–252)	50	51	ns
Reh <i>et al</i> <sup>127</sup>	13	60	30	15	30

FU, follow-up; ns, not stated.





**Figure 5** Treatment algorithm for perianal fistulising Crohn's disease. AB, antibiotics; ADA, adalimumab; AF, advancement flap; D, drainage; I, incision; IFX, infliximab; IS, immunosuppressants; LIFT, ligation of the intersphincteric fistula tract.

**Discussion** In complicated, therapy refractory perianal disease a defunctioning stoma should be considered. Based on retrospective data, early remission rates are quite high (up to 81%); however, sustained remission can only be achieved in 26–50% of cases (table 6). Most patients with a stoma ultimately require proctectomy and intestinal continuity can only be restored in a minority of patients.<sup>26</sup> The only study that was conducted in the era of biologicals showed a reduced need for completion proctectomy and a relatively higher rate of restoration. Main risks of proctectomy include damage to the pelvic nerves, presacral abscesses, and delayed perineal wound healing. Overall, the use of a diverting stoma should be reserved for patients who have uncontrollable sepsis and tissue destruction, or for patients who have failed conservative therapy. Alternatively, in selected patients, permanent faecal diversion can be avoided by coloanal pull-through or Turnbull-Cutait abdominoanal pull-through procedures, provided that the colon and the anus are intact.

## CONCLUSIONS

Optimal management of pCD requires a multidisciplinary approach. Diagnostic accuracy is usually achieved by a combination of modalities. Surgical drainage of sepsis is the first line

therapy before initiating immunosuppressive treatment. Antibiotics and thiopurines are recommended as adjunctive treatments in Crohn's fistulas. Of all available anti-TNF agents, the efficacy of infliximab is best documented. Anti-TNF can be used as first line medical treatment, optionally in combination with antibiotics and/or thiopurines. Oral tacrolimus is an option in therapy refractory patients in an attempt to avoid surgical stoma. Definitive surgical repair of fistulas, including fistulotomy, MAF, LIFT, plug and glue, is only of consideration in the absence of luminal inflammation. Proctectomy with permanent stoma is the last resort for severe, therapy refractory disease. A combined medical and surgical treatment algorithm is proposed in figure 5.

## Author affiliations

<sup>1</sup>Department of Gastroenterology and Hepatology, Academic Medical Center, University of Amsterdam, Amsterdam, The Netherlands

<sup>2</sup>Robarts Research Institute, Amsterdam, The Netherlands

<sup>3</sup>Department of Surgery, Academic Medical Center, University of Amsterdam, Amsterdam, The Netherlands

<sup>4</sup>St. Vincent's Hospital and University of Melbourne, Melbourne, Australia

<sup>5</sup>Department of Radiology, Academic Medical Center, University of Amsterdam, Amsterdam, The Netherlands

<sup>6</sup>Robarts Research Institute, London, Ontario, Canada

<sup>7</sup>University of Western Ontario, London, Ontario, Canada

<sup>8</sup>Department of Medicine and Therapeutics, Institute of Digestive Disease, Prince of Wales Hospital, Chinese University of Hong Kong, Hong Kong, Hong Kong

<sup>9</sup>Department of Gastroenterology, Hospital Clinic Barcelona, IDIBAPS, CIBERehd, Barcelona, Spain

<sup>10</sup>Department of Gastroenterology, University of Leuven, Leuven, Belgium

<sup>11</sup>Department of Gastroenterology, Shanghai Tenth People's Hospital, Tongji University, Shanghai, China

<sup>12</sup>APRG, Imperial College, London, UK

<sup>13</sup>IBD Unit, St. Mark's Hospital, London, UK

<sup>14</sup>Robarts Research Institute, San Diego, CA, USA

<sup>15</sup>Division of Gastroenterology, University of California San Diego, La Jolla, California, USA

**Acknowledgements** We thank Adam Baker from the University of Western Ontario for his help in conducting the literature search.

**Collaborators** On behalf of the WCOG Working Party: Guillaume Bouguen: Robarts Research Institute, Amsterdam, The Netherlands, London, Ontario, Canada and San Diego, California, USA, and Service des Maladies de l'Appareil Digestif et INSERM U991, Centre Hospitalier Universitaire Pontchiallou et Université de Rennes 1, Rennes, France; Andreas Sturm: Department of Gastroenterology, Krankenhaus Waldfriede, Charité Universitätsmedizin, Berlin, Germany; Andre D'Hoore: Department of Surgery, University of Leuven, Leuven, Belgium; David Laharie: CHU de Bordeaux, Hôpital Haut-Lévêque, Bordeaux, France; Brian Feagan: Robarts Research Institute, Amsterdam, The Netherlands, London, Ontario, Canada and San Diego, California, USA and University of Western Ontario, London, Ontario, Canada; William Sandborn: Robarts Research Institute, Amsterdam, The Netherlands, London, Ontario, Canada and San Diego, California, USA and Division of Gastroenterology, University of California San Diego, La Jolla, California, USA; Bruce Sands: Mont Sinai Medical Center, New York, New York, USA; Jean-Frederic Colombel: Mont Sinai Medical Center, New York, New York, USA.

**Contributors** KG performed systematic literature searches, drafted statements and algorithms and drafted the supporting text for the manuscript. WAB contributed with surgical aspects on finalising statements about classification and surgical treatment, revised the algorithm on management and the supporting text on surgical treatment. MAK contributed with practical aspects on improving all statements, revised the algorithms and the supporting text. JS contributed to optimising statements and the algorithm on diagnosis and carefully revised the corresponding supporting text. RK performed systematic literature searches and drafted statements on diagnosis. SCN, JP, GvA, ZL and AH contributed to optimising statements and algorithms during the whole preparation process and carefully revised the supporting text. BGL performed systematic literature searches, drafted statements on medical treatment and drafted the corresponding supporting text. GD'H took the initiative for this Expert Consensus, supervised each step of the process, and made final revisions of the supporting text.

**Funding** Financial support was provided by a standard grant for Working Party Report from the World Gastroenterology Organization (WGO) and Robarts Research Institute. The proposal was initially developed and supported by the International Organization for the study of Inflammatory Bowel Diseases (IOIBD) and the European Society of Coloproctology (ESCP). The pharmaceutical industry was excluded from all stages of the process.

**Competing interests** KBG reports having received speakers' honoraria from MSD. JS has a consultancy agreement with Robarts Clinical Trials. RK and ZL have no conflicts of interest to declare. JP reports grants and personal fees from Abbvie and MSD, and personal fees from BMS, Boehringer-Ingelheim, BMS, Janssen, Roche-Genentech, Novo Nordisk, Nutrition Science Partners, Pfizer, Tygenix, and Topivert. SCN reports having received speakers' honoraria from Janssen and Ferring Pharmaceuticals. She has received research grants from Janssen and Ferring Hong Kong. AH has received consulting fees from Abbott Laboratories/AbbVie, Atlantic Healthcare Limited, Bristol Meyers Squibb, Ferring Pharmaceuticals, Shire Pharmaceuticals, Schering Plough Corporation (acquired by Merck), Warner Chilcott UK Limited and Tillotts Pharma. She has received lecture honoraria from Abbott Laboratories/AbbVie, Ferring Pharmaceuticals, Shire Pharmaceuticals, Schering Plough Corporation (acquired by Merck), Warner Chilcott UK Limited. She has received research funding from Abbott Laboratories/AbbVie, Cook Pharmaceutical, MSD. GB has received lecture fees from Abbvie, Ferring, and MSD Pharma. WS reports having received consulting fees from Abbott Laboratories, ActoGenix NV, AGI Therapeutics Inc, Alba Therapeutics Corporation, Albireo, Alfa Wasserman, Amgen, AM-Pharma BV, Anaphore, Astellas Pharma, Athersys, Inc., Atlantic Healthcare Limited, Axcen Pharma (now Aptalis), BioBalance Corporation, Boehringer-Ingelheim Inc, Bristol Meyers Squibb, Cellegene, Celek Pharmaceuticals, Cellerix SL, Cerimon Pharmaceuticals, ChemoCentryx, CoMentis, Cosmo Technologies, Coronado Biosciences, Cytokine Pharmasciences, Eagle Pharmaceuticals, Eisai Medical Research Inc, Elan Pharmaceuticals, EnGene, Inc, Eli Lilly, Enteromedics, Exagen Diagnostics, Inc, Ferring Pharmaceuticals, Flexion Therapeutics, Inc, Funxional Therapeutics Limited, Genzyme Corporation, Genentech

(now Roche), Gilead Sciences, Given Imaging, Glaxo Smith Kline, Human Genome Sciences, Ironwood Pharmaceuticals (previously Microbia Inc), Janssen (previously Centocor), KaloBios Pharmaceuticals, Inc, Lexicon Pharmaceuticals, Lycera Corporation, Meda Pharmaceuticals (previously Alaven Pharmaceuticals), Merck Research Laboratories, MerckSerono, Millennium Pharmaceuticals (subsequently merged with Takeda), Nissin Kyorin Pharmaceuticals Co, Ltd, Novo Nordisk A/S, NPS Pharmaceuticals, Optimer Pharmaceuticals, Oregien Therapeutics, Inc, PDL Biopharma, Pfizer, Procter and Gamble, Prometheus Laboratories, ProtAb Limited, Purgenesis Technologies, Inc, Receptos, Relypsa, Inc, Salient Pharmaceuticals, Salix Pharmaceuticals, Inc, Santarus, Schering Plough Corporation (acquired by Merck), Shire Pharmaceuticals, Sigmoid Pharma Limited, Sirtris Pharmaceuticals, Inc (a GSK company), S.L.A. Pharma (UK) Limited, Targacept, Teva Pharmaceuticals, Therakos, Tillotts Pharma AG (acquired by Zeria Pharmaceutical Co, Ltd), TxCel SA, UCB Pharma, Viamet Pharmaceuticals, Vascular Biogenics Limited (VBL), Warner Chilcott UK Limited, Wyeth (now Pfizer). He has received lecture fees from Abbott Laboratories, Bristol Meyers Squibb, and Janssen (previously Centocor). He has received research support from Abbott Laboratories, Bristol Meyers Squibb, Genentech, Glaxo Smith Kline, Janssen (previously Centocor), Millennium Pharmaceuticals (now Takeda), Novartis, Pfizer, Procter and Gamble Pharmaceuticals, Shire Pharmaceuticals, and UCB Pharma. BGL reports having received consulting fees from Prometheus Labs, and Santarus Inc, speakers' honoraria from Warner Chilcott, and UCB Pharma. GD'H has received consultancy fees from Abbott Laboratories, Actogenix, Boehringer Ingelheim, Centocor, Cosmo Technologies, Engene, Ferring Pharmaceuticals, GlaxoSmithKline, Jansen Biologics, Millennium Pharmaceuticals, Mitsubishi Pharma, Merck Research Laboratories, Novo Nordisk, PDL Biopharma, Pfizer, Schering Plough, SetPoint, Shire Pharmaceuticals, Sigmoid Pharma Ltd, Takeda, Teva, Tillotts Pharma, UCB Pharma; research grants from Abbott Laboratories, Jansen Biologics, Given Imaging, MSD, DrFalk Pharma, Photopill; speaking honoraria from Abbott Laboratories, Jansen Biologics, Tillotts, Tramedico, Ferring, MSD, UCB, Norgine and Shire; stock options from Engene Inc.

**Provenance and peer review** Not commissioned; externally peer reviewed.

## REFERENCES

- Penner A, Crohn BB. Perianal fistulae as a complication of regional ileitis. *Ann Surg* 1938;108:867–73.
- Schwartz DA, Loftus EV Jr, Tremaine WJ, et al. The natural history of fistulizing Crohn's disease in Olmsted County, Minnesota. *Gastroenterology* 2002;122:875–80.
- Hellers G, Bergstrand O, Ewerth S, et al. Occurrence and outcome after primary treatment of anal fistulae in Crohn's disease. *Gut* 1980;21:525–7.
- Bitton A, Buie D, Enns R, et al. Treatment of hospitalized adult patients with severe ulcerative colitis: Toronto consensus statements. *Am J Gastroenterol* 2012;107:179–94; author reply 95.
- Guyatt GH, Cook DJ, Jaeschke R, et al. Grades of recommendation for antithrombotic agents: American College of Chest Physicians Evidence-Based Clinical Practice Guidelines (8th edition). *Chest* 2008;133:1235–315.
- Parks AG, Gordon PH, Hardcastle JD. A classification of fistula-in-ano. *Br J Surg* 1976;63:1–12.
- Buchmann P, Alexander-Williams J. Classification of perianal Crohn's disease. *Clin Gastroenterol* 1980;9:323–30.
- Hughes LE. Clinical classification of perianal Crohn's disease. *Dis Colon Rectum* 1992;35:928–32.
- Morris J, Spencer JA, Ambrose NS. MR imaging classification of perianal fistulas and its implications for patient management. *Radiographics* 2000;20:623–35; discussion 35–7.
- Sandborn WJ, Fazio VW, Feagan BG, et al. American Gastroenterological Association Clinical Practice C. AGA technical review on perianal Crohn's disease. *Gastroenterology* 2003;125:1508–30.
- Present DH, Korelitz BI, Wisch N, et al. Treatment of Crohn's disease with 6-mercaptopurine. A long-term, randomized, double-blind study. *N Engl J Med* 1980;302:981–7.
- Allan A, Linares L, Spooner HA, et al. Clinical index to quantitate symptoms of perianal Crohn's disease. *Dis Colon Rectum* 1992;35:656–61.
- Irvine EJ. Usual therapy improves perianal Crohn's disease as measured by a new disease activity index. McMaster IBD Study Group. *J Clin Gastroenterol* 1995;20:27–32.
- Present DH, Rutgeerts P, Targan S, et al. Infliximab for the treatment of fistulas in patients with Crohn's disease. *N Engl J Med* 1999;340:1398–405.
- Pikarsky AJ, Gervaz P, Wexner SD. Perianal Crohn disease: a new scoring system to evaluate and predict outcome of surgical intervention. *Arch Surg* 2002;137:774–7; discussion 8.
- Van Assche G, Vanbeckvoort D, Bielen D, et al. Magnetic resonance imaging of the effects of infliximab on perianal fistulizing Crohn's disease. *Am J Gastroenterol* 2003;98:332–9.
- Losco A, Viganò C, Conte D, et al. Assessing the activity of perianal Crohn's disease: comparison of clinical indices and computer-assisted anal ultrasound. *Inflamm Bowel Dis* 2009;15:742–9.

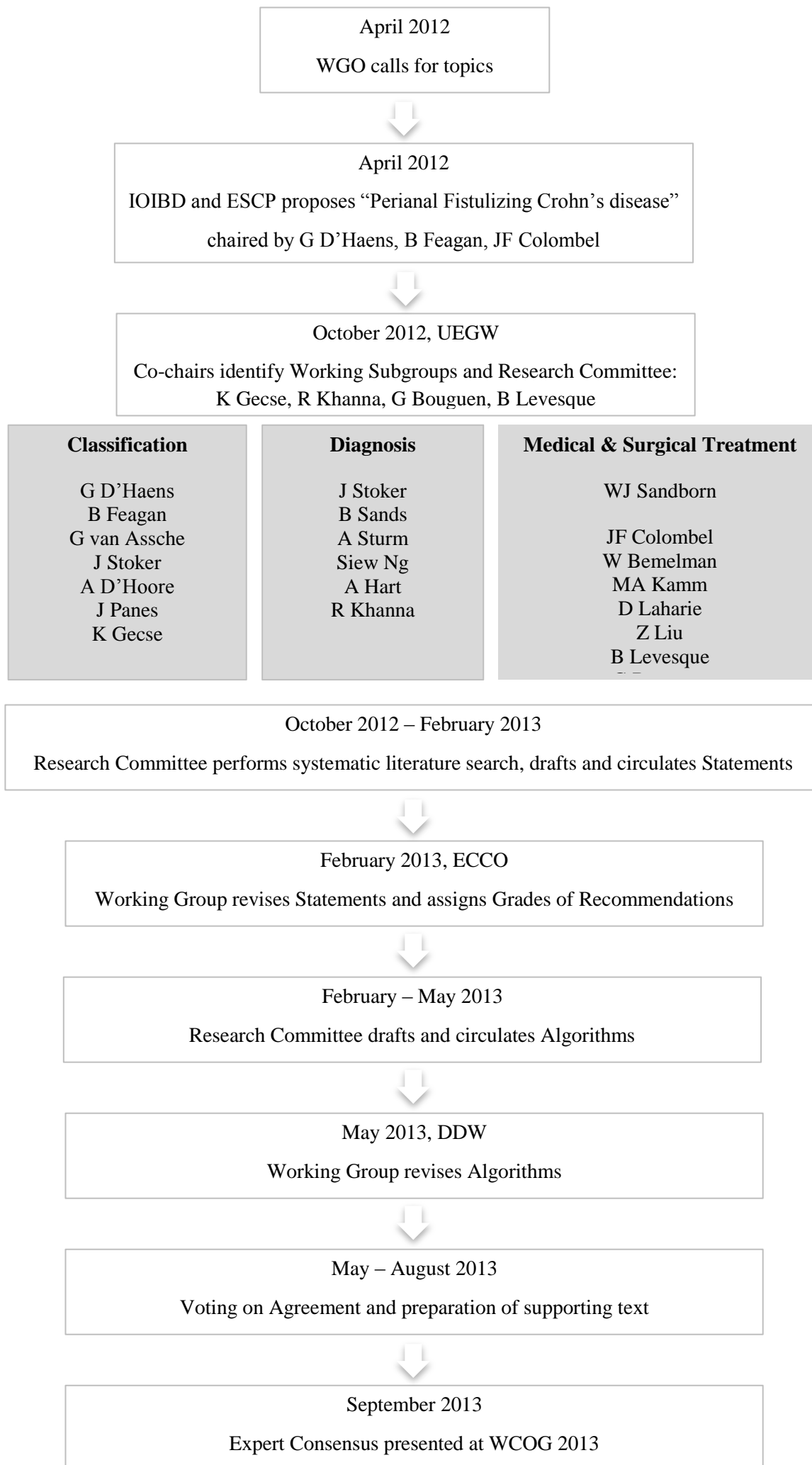
- 18 Sandborn WJ, Present DH, Isaacs KL, *et al.* Tacrolimus for the treatment of fistulas in patients with Crohn's disease: a randomized, placebo-controlled trial. *Gastroenterology* 2003;125:380–8.
- 19 Sands BE, Anderson FH, Bernstein CN, *et al.* Infliximab maintenance therapy for fistulizing Crohn's disease. *N Engl J Med* 2004;350:876–85.
- 20 Colombel JF, Sandborn WJ, Rutgeerts P, *et al.* Adalimumab for maintenance of clinical response and remission in patients with Crohn's disease: the CHARM trial. *Gastroenterology* 2007;132:52–65.
- 21 Tozer P, Ng SC, Siddiqui MR, *et al.* Long-term MRI-guided combined anti-TNF-alpha and thiopurine therapy for Crohn's perianal fistulas. *Inflamm Bowel Dis* 2012;18:1825–34.
- 22 Horsthuis K, Ziech ML, Bipat S, *et al.* Evaluation of an MRI-based score of disease activity in perianal fistulizing Crohn's disease. *Clin Imaging* 2011;35:360–5.
- 23 Savoye-Collet C, Savoye G, Koning E, *et al.* Fistulizing perianal Crohn's disease: contrast-enhanced magnetic resonance imaging assessment at 1 year on maintenance anti-TNF-alpha therapy. *Inflamm Bowel Dis* 2011;17:1751–8.
- 24 Shenoy-Bhangle A, Nimkin K, Goldner D, *et al.* MRI predictors of treatment response for perianal fistulizing Crohn disease in children and young adults. *Pediatr Radiol* 2014;44:23–9.
- 25 Regueiro M. The role of endoscopy in the evaluation of fistulizing Crohn's disease. *Gastrointest Endosc Clin N Am* 2002;12:621–33.
- 26 Bell SJ, Williams AB, Wiesel P, *et al.* The clinical course of fistulating Crohn's disease. *Aliment Pharmacol Ther* 2003;17:1145–51.
- 27 Schwartz DA, Wiersema MJ, Dudiak KM, *et al.* A comparison of endoscopic ultrasound, magnetic resonance imaging, and exam under anesthesia for evaluation of Crohn's perianal fistulas. *Gastroenterology* 2001;121:1064–72.
- 28 Regueiro M, Mardini H. Treatment of perianal fistulizing Crohn's disease with infliximab alone or as an adjunct to exam under anesthesia with seton placement. *Inflamm Bowel Dis* 2003;9:98–103.
- 29 Halligan S, Stoker J. Imaging of fistula in ano. *Radiology* 2006;239:18–33.
- 30 Koelbel G, Schmiedl U, Majer MC, *et al.* Diagnosis of fistulae and sinus tracts in patients with Crohn disease: value of MR imaging. *AJR Am J Roentgenol* 1989;152:999–1003.
- 31 Barker PG, Lunniss PJ, Armstrong P, *et al.* Magnetic resonance imaging of fistula-in-ano: technique, interpretation and accuracy. *Clin Radiol* 1994;49:7–13.
- 32 Haggett PJ, Moore NR, Shearman JD, *et al.* Pelvic and perineal complications of Crohn's disease: assessment using magnetic resonance imaging. *Gut* 1995;36:407–10.
- 33 Bell SJ, Halligan S, Windsor AC, *et al.* Response of fistulating Crohn's disease to infliximab treatment assessed by magnetic resonance imaging. *Aliment Pharmacol Ther* 2003;17:387–93.
- 34 Stoker J, Hussain SM, Van Kempen D, *et al.* Endoanal coil in MR imaging of anal fistulas. *Am J Roentgenol* 1996;166:360–2.
- 35 Law PJ, Bartram CI. Anal endosonography: technique and normal anatomy. *Gastrointest Radiol* 1989;14:349–53.
- 36 Van Outryve MJ, Pelckmans PA, Michiels PP, *et al.* Value of transrectal ultrasonography in Crohn's disease. *Gastroenterology* 1991;101:1171–7.
- 37 Tio TL, Mulder CJ, Wijers OB, *et al.* Endosonography of peri-anal and peri-colorectal fistula and/or abscess in Crohn's disease. *Gastrointest Endosc* 1990;36:331–6.
- 38 Cheong DM, Nogueras JJ, Wexner SD, *et al.* Anal endosonography for recurrent anal fistulas: image enhancement with hydrogen peroxide. *Dis Colon Rectum* 1993;36:1158–60.
- 39 Navarro-Luna A, Garcia-Domingo MI, Rius-Macias J, *et al.* Ultrasound study of anal fistulas with hydrogen peroxide enhancement. *Dis Colon Rectum* 2004;47:108–14.
- 40 Di Nardo R, Drudi FM, Marziale P, *et al.* [Role of color Doppler echography in the visualization of perianal fistulae with injections of physiologic solutions]. *Radiol Med* 2000;100:235–9.
- 41 West RL, Dwarkasing S, Felt-Bersma RJ, *et al.* Hydrogen peroxide-enhanced three-dimensional endoanal ultrasonography and endoanal magnetic resonance imaging in evaluating perianal fistulas: agreement and patient preference. *Eur J Gastroenterol Hepatol* 2004;16:1319–24.
- 42 Zawadzki A, Starck M, Bohe M, *et al.* A unique 3D endoanal ultrasound feature of perianal Crohn's fistula: the 'Crohn ultrasound fistula sign'. *Colorectal Dis* 2012;14:e608–11.
- 43 Campari A, Giovanni M, Tonolini M, *et al.* Accuracy of transperineal ultrasound (TPUS) and magnetic resonance imaging (MRI) in the assessment of perianal Crohn's disease (CD). *Dig Liver Dis* 2011;43:134–55.
- 44 Sahni VA, Ahmad R, Burling D. Which method is best for imaging of perianal fistula? *Abdom Imaging* 2008;33:26–30.
- 45 Orsoni P, Barthet M, Portier F, *et al.* Prospective comparison of endosonography, magnetic resonance imaging and surgical findings in anorectal fistula and abscess complicating Crohn's disease. *Br J Surg* 1999;86:360–4.
- 46 Buchanan GN, Halligan S, Bartram CI, *et al.* Clinical examination, endosonography, and MR imaging in preoperative assessment of fistula in ano: comparison with outcome-based reference standard. *Radiology* 2004;233:674–81.
- 47 Siddiqui MR, Ashrafian H, Tozer P, *et al.* A diagnostic accuracy meta-analysis of endoanal ultrasound and MRI for perianal fistula assessment. *Dis Colon Rectum* 2012;55:576–85.
- 48 Kuipers HC, Schulpen T. Fistulography for fistula-in-ano. Is it useful? *Dis Colon Rectum* 1985;28:103–4.
- 49 Weisman RI, Orsay CP, Pearl RK, *et al.* The role of fistulography in fistula-in-ano. Report of five cases. *Dis Colon Rectum* 1991;34:181–4.
- 50 Nielsen OH, Munck LK. Drug insight: aminosalicylates for the treatment of IBD. *Nat Clin Pract Gastroenterol Hepatol* 2007;4:160–70.
- 51 Jones JH, Lennard-Jones JE. Corticosteroids and corticotrophin in the treatment of Crohn's disease. *Gut* 1966;7:181–7.
- 52 Bernstein LH, Frank MS, Brandt LJ, *et al.* Healing of perineal Crohn's disease with metronidazole. *Gastroenterology* 1980;79:599.
- 53 Brandt LJ, Bernstein LH, Boley SJ, *et al.* Metronidazole therapy for perineal Crohn's disease: a follow-up study. *Gastroenterology* 1982;83:383–7.
- 54 Jakobovits J, Schuster MM. Metronidazole therapy for Crohn's disease and associated fistulae. *Am J Gastroenterol* 1984;79:533–40.
- 55 Thia KT, Mahadevan U, Feagan BG, *et al.* Ciprofloxacin or metronidazole for the treatment of perianal fistulas in patients with Crohn's disease: a randomized, double-blind, placebo-controlled pilot study. *Inflamm Bowel Dis* 2009;15:17–24.
- 56 Maeda Y, Ng SC, Durdey P, *et al.* Randomized clinical trial of metronidazole ointment versus placebo in perianal Crohn's disease. *Br J Surg* 2010;97:1340–7.
- 57 Stringer EE, Nicholson TJ, Armstrong D. Efficacy of topical metronidazole (10 percent) in the treatment of anorectal Crohn's disease. *Dis Colon Rectum* 2005;48:970–4.
- 58 West RL, Woude CJ, Hansen BE, *et al.* Clinical and endosonographic effect of ciprofloxacin on the treatment of perianal fistulae in Crohn's disease with infliximab: a double-blind placebo-controlled study. *Aliment Pharmacol Ther* 2004;18:129–36.
- 59 Dewint P, Hansen BE, Verhey E, *et al.* Adalimumab combined with ciprofloxacin is superior to adalimumab monotherapy in perianal fistula closure in Crohn's disease: a randomised, double-blind, placebo controlled trial (ADAFI). *Gut* 2014;63:292–9.
- 60 Prefontaine E, Macdonald JK, Sutherland LR. Azathioprine or 6-mercaptopurine for induction of remission in Crohn's disease. *Cochrane Database Syst Rev* 2010: CD000545.
- 61 Pearson DC, May GR, Fick GH, *et al.* Azathioprine and 6-mercaptopurine in Crohn disease. A meta-analysis. *Ann Intern Med* 1995;123:132–42.
- 62 DeJaco C, Harter M, Waldhoer T, *et al.* Antibiotics and azathioprine for the treatment of perianal fistulas in Crohn's disease. *Aliment Pharmacol Ther* 2003;18:1113–20.
- 63 Hart AL, Plamondon S, Kamm MA. Topical tacrolimus in the treatment of perianal Crohn's disease: exploratory randomized controlled trial. *Inflamm Bowel Dis* 2007;13:245–53.
- 64 Egan LJ, Sandborn WJ, Tremaine WJ. Clinical outcome following treatment of refractory inflammatory and fistulizing Crohn's disease with intravenous cyclosporine. *Am J Gastroenterol* 1998;93:442–8.
- 65 Hanauer SB, Smith MB. Rapid closure of Crohn's disease fistulas with continuous intravenous cyclosporin A. *Am J Gastroenterol* 1993;88:646–9.
- 66 Present DH, Lichtiger S. Efficacy of cyclosporine in treatment of fistula of Crohn's disease. *Dig Dis Sci* 1994;39:374–80.
- 67 Present DH, Rutgeerts P, Targan S, *et al.* Infliximab for the treatment of fistulas in patients with Crohn's disease. *N Engl J Med* 1999;340:1398–405.
- 68 Sands BE, Anderson FH, Bernstein CN, *et al.* Infliximab maintenance therapy for fistulizing Crohn's disease. *N Engl J Med* 2004;350:876–85.
- 69 Hanauer SB, Sandborn WJ, Rutgeerts P, *et al.* Human anti-tumor necrosis factor monoclonal antibody (adalimumab) in Crohn's disease: the CLASSIC-I trial. *Gastroenterology* 2006;130:323–32.
- 70 Sandborn WJ, Rutgeerts P, Enns R, *et al.* Adalimumab induction therapy for Crohn disease previously treated with infliximab: a randomized trial. *Ann Intern Med* 2007;146:829–38.
- 71 Colombel JF, Schwartz DA, Sandborn WJ, *et al.* Adalimumab for the treatment of fistulas in patients with Crohn's disease. *Gut* 2009;58:940–8.
- 72 Echarri A, Castro J, Barreiro M, *et al.* Evaluation of adalimumab therapy in multidisciplinary strategy for perianal Crohn's disease patients with infliximab failure. *J Crohn's Colitis* 2010;4:654–60.
- 73 Lichtiger S, Binion DG, Wolf DC, *et al.* The CHOICE trial: adalimumab demonstrates safety, fistula healing, improved quality of life and increased work productivity in patients with Crohn's disease who failed prior infliximab therapy. *Aliment Pharmacol Ther* 2010;32:1228–39.
- 74 Tozer P, Ng SC, Siddiqui MR, *et al.* Long-term MRI-guided combined anti-TNF- and thiopurine therapy for Crohn's perianal fistulas. *Inflamm Bowel Dis* 2012;18:1825–34.
- 75 Schreiber S, Lawrance IC, Thomsen OO, *et al.* Randomised clinical trial: certolizumab pegol for fistulas in Crohn's disease—subgroup results from a placebo-controlled study. *Aliment Pharmacol Ther* 2011;33:185–93.
- 76 Ford AC, Sandborn WJ, Khan KJ, *et al.* Efficacy of biological therapies in inflammatory bowel disease: systematic review and meta-analysis. *Am J Gastroenterol* 2011;106:644–59, quiz 60.



- 77 Colombel JF, Sandborn WJ, Reinisch W, *et al.* Infliximab, azathioprine, or combination therapy for Crohn's disease. *N Engl J Med* 2010;362:1383–95.
- 78 Bouguen G, Siproudhis L, Gizard E, *et al.* Long-term outcome of perianal fistulizing Crohn's disease treated with infliximab. *Clin Gastroenterol Hepatol* 2013;8:975–81.
- 79 El-Gazzaz G, Hull T, Church JM. Biological immunomodulators improve the healing rate in surgically treated perianal Crohn's fistulas. *Colorectal Dis* 2012;14:1217–23.
- 80 Solomon MJ. Fistulae and abscesses in symptomatic perianal Crohn's disease. *Int J Colorectal Dis* 1996;11:222–6.
- 81 Hyder SA, Travis SP, Jewell DP, *et al.* Fistulating anal Crohn's disease: results of combined surgical and infliximab treatment. *Dis Colon Rectum* 2006;49:1837–41.
- 82 Buchanan GN, Owen HA, Torkington J, *et al.* Long-term outcome following loose-seton technique for external sphincter preservation in complex anal fistula. *Br J Surg* 2004;91:476–80.
- 83 Parks AG, Stitz RW. The treatment of high fistula-in-ano. *Dis Colon Rectum* 1976;19:487–99.
- 84 Hamalainen KP, Sainio AP. Cutting seton for anal fistulas: high risk of minor control defects. *Dis Colon Rectum* 1997;40:1443–6; discussion 7.
- 85 Tanaka S, Matsuo K, Sasaki T, *et al.* Clinical advantages of combined seton placement and infliximab maintenance therapy for perianal fistulizing Crohn's disease: when and how were the seton drains removed? *Hepatogastroenterology* 2010;57:3–7.
- 86 Nordgren S, Fasth S, Hulthen L. Anal fistulas in Crohn's disease: incidence and outcome of surgical treatment. *Int J Colorectal Dis* 1992;7:214–18.
- 87 Tougeron D, Savoye G, Savoye-Collet C, *et al.* Predicting factors of fistula healing and clinical remission after infliximab-based combined therapy for perianal fistulizing Crohn's disease. *Dig Dis Sci* 2009;54:1746–52.
- 88 Kamm MA, Ng SC. Perianal fistulizing Crohn's disease: a call to action. *Clin Gastroenterol Hepatol* 2008;6:7–10.
- 89 Williams JG, Rothenberger DA, Nemer FD, *et al.* Fistula-in-ano in Crohn's disease. Results of aggressive surgical treatment. *Dis Colon Rectum* 1991;34:378–84.
- 90 Soltani A, Kaiser AM. Endorectal advancement flap for cryptoglandular or Crohn's fistula-in-ano. *Dis Colon Rectum* 2010;53:486–95.
- 91 O'Connor L, Champagne BJ, Ferguson MA, *et al.* Efficacy of anal fistula plug in closure of Crohn's anorectal fistulas. *Dis Colon Rectum* 2006;49:1569–73.
- 92 Ellis CN, Rostas JW, Greiner FG. Long-term outcomes with the use of bioprosthetic plugs for the management of complex anal fistulas. *Dis Colon Rectum* 2010;53:798–802.
- 93 Owen G, Keshava A, Stewart P, *et al.* Plugs unplugged. Anal fistula plug: the Concord experience. *ANZ J Surg* 2010;80:341–3.
- 94 Lawes DA, Efron JE, Abbas M, *et al.* Early experience with the bioabsorbable anal fistula plug. *World J Surg* 2008;32:1157–9.
- 95 Thekkinkattil DK, Botterill I, Ambrose NS, *et al.* Efficacy of the anal fistula plug in complex anorectal fistulae. *Colorectal Dis* 2009;11:584–7.
- 96 Rojanasakul A, Pattanaarun J, Sahakitrungruang C, *et al.* Total anal sphincter saving technique for fistula-in-ano; the ligation of intersphincteric fistula tract. *J Med Assoc Thai* 2007;90:581–6.
- 97 Abcarian AM, Estrada JJ, Park J, *et al.* Ligation of intersphincteric fistula tract: early results of a pilot study. *Dis Colon Rectum* 2012;55:778–82.
- 98 Realis Luc A, Clerico G, Ganio E, *et al.* Lift for complex anal fistulae: the Colorectal Eporediensis Centre's experience. *Tech Coloproctol* 2012;16:82–3.
- 99 Cirocchi R, Santoro A, Trastulli S, *et al.* Meta-analysis of fibrin glue versus surgery for treatment of fistula-in-ano. *Ann Ital Chir* 2010;81:349–56.
- 100 Garcia-Olmo D, Garcia-Arranz M, Herreros D, *et al.* A phase I clinical trial of the treatment of Crohn's fistula by adipose mesenchymal stem cell transplantation. *Dis Colon Rectum* 2005;48:1416–23.
- 101 Ciccocioppo R, Bernardo ME, Sgarrella A, *et al.* Autologous bone marrow-derived mesenchymal stromal cells in the treatment of fistulising Crohn's disease. *Gut* 2011;60:788–98.
- 102 Cho YB, Lee WY, Park KJ, *et al.* Autologous adipose tissue-derived stem cells for the treatment of Crohn's fistula: a phase I clinical study. *Cell Transplant* 2013;22:279–85.
- 103 Garcia-Olmo D, Herreros D, Pascual I, *et al.* Expanded adipose-derived stem cells for the treatment of complex perianal fistula: a phase II clinical trial. *Dis Colon Rectum* 2009;52:79–86.
- 104 Guadalajara H, Herreros D, De-La-Quintana P, *et al.* Long-term follow-up of patients undergoing adipose-derived adult stem cell administration to treat complex perianal fistulas. *Int J Colorectal Dis* 2012;27:595–600.
- 105 Lee WY, Park KJ, Cho YB, *et al.* Autologous adipose tissue-derived stem cells treatment demonstrated favorable and sustainable therapeutic effect for Crohn's fistula. *Stem Cells* 2013;31:2575–81.
- 106 de la Portilla F, Alba F, Garcia-Olmo D, *et al.* Expanded allogeneic adipose-derived stem cells (eASCs) for the treatment of complex perianal fistula in Crohn's disease: results from a multicenter phase I/IIa clinical trial. *Int J Colorectal Dis* 2013;28:313–23.
- 107 Maeda Y, Heyckendorff-Diebold T, Tei TM, *et al.* Gracilis muscle transposition for complex fistula and persistent nonhealing sinus in perianal Crohn's disease. *Inflamm Bowel Dis* 2011;17:583–9.
- 108 Gecse K, Khanna R, Stoker J, *et al.* Fistulizing Crohn's disease: diagnosis and management. *United European Gastroenterol J* 2013;1:206–13.
- 109 Hobbiss JH, Schofield PF. Management of perianal Crohn's disease. *J R Soc Med* 1982;75:414–17.
- 110 Keighley MR, Allan RN. Current status and influence of operation on perianal Crohn's disease. *Int J Colorectal Dis* 1986;1:104–7.
- 111 Halme L, Sainio AP. Factors related to frequency, type, and outcome of anal fistulas in Crohn's disease. *Dis Colon Rectum* 1995;38:55–9.
- 112 Scott HJ, Northover JM. Evaluation of surgery for perianal Crohn's fistulas. *Dis Colon Rectum* 1996;39:1039–43.
- 113 McKee RF, Keenan RA. Perianal Crohn's disease—is it all bad news? *Dis Colon Rectum* 1996;39:136–42.
- 114 Michelassi F, Melis M, Rubin M, *et al.* Surgical treatment of anorectal complications in Crohn's disease. *Surgery* 2000;128:597–603.
- 115 Lozynskyy YS. Treatment algorithms in the case of perianal complications of Crohn's disease. *Dig Dis* 2009;27:565–70.
- 116 van Koperen PJ, Safiruddin F, Bemelman WA, *et al.* Outcome of surgical treatment for fistula in ano in Crohn's disease. *Br J Surg* 2009;96:675–9.
- 117 Grimaud JC, Munoz-Bongrand N, Siproudhis L, *et al.* Fibrin glue is effective in healing perianal fistulas in patients with Crohn's disease. *Gastroenterology* 2010;138:2275–81, 81 e1.
- 118 Lindsey I, Smilgin-Humphreys MM, Cunningham C, *et al.* A randomized, controlled trial of fibrin glue vs. conventional treatment for anal fistula. *Dis Colon Rectum* 2002;45:1608–15.
- 119 Witte ME, Klaase JM, Gerritsen JJ, *et al.* Fibrin glue treatment for simple and complex anal fistulas. *Hepatogastroenterology* 2007;54:1071–3.
- 120 Vitton V, Gasmi M, Barthet M, *et al.* Long-term healing of Crohn's anal fistulas with fibrin glue injection. *Aliment Pharmacol Ther* 2005;21:1453–7.
- 121 de Parades V, Far HS, Etienney I, *et al.* Seton drainage and fibrin glue injection for complex anal fistulas. *Colorectal Dis* 2010;12:459–63.
- 122 Loungnarath R, Dietz DW, Mutch MG, *et al.* Fibrin glue treatment of complex anal fistulas has low success rate. *Dis Colon Rectum* 2004;47:432–6.
- 123 Zmora O, Mizrahi N, Rotholtz N, *et al.* Fibrin glue sealing in the treatment of perineal fistulas. *Dis Colon Rectum* 2003;46:584–9.
- 124 Sentovich SM. Fibrin glue for all anal fistulas. *J Gastrointest Surg* 2001;5:158–61.
- 125 Yamamoto T, Allan RN, Keighley MR. Effect of fecal diversion alone on perianal Crohn's disease. *World J Surg* 2000;24:1258–62; discussion 62–3.
- 126 Guillem JG, Roberts PL, Murray JJ, *et al.* Factors predictive of persistent or recurrent Crohn's disease in excluded rectal segments. *Dis Colon Rectum* 1992;35:768–72.
- 127 Reh G, Sanchez JE, Krieger BR, *et al.* Fecal diversion in perirectal fistulizing Crohn's disease is an underutilized and potentially temporary means of successful treatment. *Am Surg* 2009;75:715–18.

## **Supplementary Material**

### **Supplementary Figure 1. Consensus Process**





**Supplementary Table 1. Level of Agreement and Grades of Recommendation**

<b><i>Level of Agreement</i></b>
<b>A+</b> Agree strongly
<b>A</b> Agree with minor reservation
<b>A-</b> Agree with major reservation
<b>D</b> Disagree with minor reservation
<b>D-</b> Disagree with major reservation
<b>D+</b> Disagree strongly
<b><i>Grades of Recommendation</i></b>
<b>1A</b> Strong recommendation, high-quality evidence
<b>1B</b> Strong recommendation, moderate-quality evidence
<b>1C</b> Strong recommendation, low-quality or very low-quality evidence
<b>2A</b> Weak recommendation, high-quality evidence
<b>2B</b> Weak recommendation, moderate-quality evidence
<b>2C</b> Weak recommendation, low-quality or very low-quality evidence

Adapted from Guyatt et al. and Bitton *et al.*

## **Experimental Therapies**

### ***Medical therapies***

Uncontrolled case series have reported the efficacy of miscellaneous treatments (MMF [9-12], nutritional therapy[13-17], hyperbaric oxygen[18-23], platelet derived growth factor[24,25] and GM-CSF[26]) for the treatment of fistulizing Crohn's disease. Controlled trials are needed to support their use in pCD. Of note, a single short and small placebo-controlled trial randomized 57 patients with perianal Crohn's fistulas to treatment with placebo or oral spherical adsorptive carbon.[27] Upon 8-weeks of follow-up, 8 of 27 patients (29.6%) achieved clinical remission, defined as a closure of all fistulas without any leakage, as compared to 2 of 30 patients (6.7%) in the placebo group.[27] However, a recent RCT including 249 patients failed to confirm the adsorptive carbon.[28] Prospective open-label series and retrospective cohort observed some efficacy of thalidomide particularly after failure of TNF antagonists, however intolerance and side effects to thalidomide were frequent.[29-35] Thus, the evidence level of efficacy of mycophenolate mofetil (MMF), thalidomide, GM-CSF, nutritional therapy and hyperbaric oxygen is low in fistulizing Crohn's disease. Evidence for oral adsorptive carbon microspheres is contradictory, therefore its use is not recommended.

### ***Surgical and endoscopic treatments***

A modification of the loose Seton, called *progressive migration technique* (daily self rotation of the Seton by 360 degrees) has recently been introduced for high transsphincteric fistulas.[36] Although the technique is promising with regard to healing, recurrence and incontinence rates data, especially concerning Crohn's fistulae, are yet insufficient to recommend standard use.[36]

Preliminary data from a recent prospective study showed that flap advancement can be successfully combined with *video-assisted anal fistula treatment* (VAAFT).[37] The technique involves direct visualization of the fistula tracts, potential side tracts and internal openings by a fistuloscope before performing advancement flap repair.

*Local anti-TNF injections* have been proposed for patients who are intolerant or unresponsive to systemic therapy. Two open-label studies have examined the effect of this treatment on perianal fistulizing Crohn's. Perifistular infliximab injection was shown to induce fistula closure in 10 of 15 patients (15-20mg, 3-12 infusions).[38] In another study, of the 11 patients treated with local infliximab (20mg, repeated every 4 weeks) 8

patients achieved clinical response or remission. During follow-up (mean 10.5 months) 4 patients remained in remission.[39] A prospective open-label study showed improvement in all 12 patients and complete cessation of drainage in 9 patients treated with perifistular adalimumab.[40] Combination treatment of fistulectomy and perifistular infliximab injections (20-25mg, every 4-6 weeks until fistula closure, median 5 sessions) resulted in persistent closure in 7 of 8 patients upon 1-year follow-up according to a prospective cohort.[41] Although these reports showed beneficial effect of local biological therapy patient numbers were low and a control group was lacking, therefore further controlled clinical trials are needed to recommend their use in clinical practice.

*Carbon dioxide laser ablation.* In a prospective, single-arm study including 27 Crohn's patients carbon dioxide laser ablation significantly improved perianal fistula drainage.[42] The technique was combined with the placement of noncutting Seton for 6 months and complete healing was reached in 11 patients at the final visit (mean 19 months). This treatment remains highly experimental.

*Over The Scope Clip (OTSC).* The OTSC (Ovesco Endoscopy, Tübingen, Germany) was tested in a porcine model to close internal fistula openings by using a transanal clip applicator.[43] This pilot study demonstrated feasibility, safety and suggested better fistula healing compared to untreated control fistulas. In a single case report on a high transsphincteric fistula, healing was observed and the OTSC was removed eight months after clip closure.[44] Further controlled trials are awaited to evaluate the role of this minimally invasive technique.

## Figure Legends

**Supplementary Figure 1.** Systematic Literature Searches of PubMed and Embase were performed by the Research Committee (KG, RK, GB, BL) in conjunction with the Cochrane Review in IBD team at Western University, London, Ontario, Canada, using the following search terms: Crohn\*, enteritis regional\*, ileitis terminal\*, perianal, anal, perineal, fistul\*, sinus, sinus\*, classsif\*, grade, gradi\*, index, index\*, indice, scale, scale\*, scali\*, score, score\*, scori\*, activity, diagnostic, diagnosi\*, diagnose, image, image\*, ultrasound\*, EUS, magnetic resonance, MR, MRI, endoscop\*, sigmoidoscop\*, proctosigmoidoscop\*, computerized tomography, CT, fistulograph\*, EUA, examination under anaesthesia, antibiotic, immunomodulat\*, immunosuppress\*, biologic, anti-TNF, metronidazole,



ciprofloxacin, amoxicillin, 6-mercaptopurine, azathioprine, thioguanine, tioguanine, cyclosporine, tacrolimus, methotrexate, infliximab, adalimumab, certolizumab, oxygen, carbon, nutrition, mycophenolate mofetil, thalidomide, GM-CSF, surgery, surgery\*, surgi\*, seton, drain\*, fistulotomy, fistulectomy, lay-open, flap, LIFT, bioLIFT, plug, glue, stem cell, stoma, proctectomy. Searches were limited to English language and full papers. Additionally, abstracts from Digestive Disease Week (DDW), United European Gastroenterology Week (UEGW), Annual Meeting of the Radiological Society of North America (RSNA) and European Congress of Radiology (ECR) 2012 and 2013 were also screened. The search initially identified 4680 references. Titles and abstracts were downloaded and two independent committee members reached consensus on which references were the most relevant.

## References on Experimental Treatment

1. Fickert P, Hinterleitner TA, Wenzl HH, et al. Mycophenolate mofetil in patients with Crohn's disease. *American Journal of Gastroenterology* 1998;**93**(12):2529-32.
2. Hafraoui S, Dewit O, Marteau P, et al. [Mycophenolate mofetil in refractory Crohn's disease after failure of treatments by azathioprine or methotrexate]. *Gastroenterol Clin Biol* 2002;**26**(1):17-22.
3. Hassard PV, Vasilias EA, Kam LY, et al. Efficacy of mycophenolate mofetil in patients failing 6-mercaptopurine or azathioprine therapy for Crohn's disease. *Inflammatory bowel diseases* 2000;**6**(1):16-20.
4. Wenzl HH, Hinterleitner TA, Aichbichler BW, et al. Mycophenolate mofetil for Crohn's disease: Short-term efficacy and long-term outcome. *Alimentary Pharmacology and Therapeutics* 2004;**19**(4):427-34.
5. Calam J, Crooks PE, Walker RJ. Elemental diets in the management of Crohn's perianal fistulae. *JPEN J Parenter Enteral Nutr* 1980;**4**(1):4-8.
6. Fukuda Y, Kosaka T, Okui M, et al. Efficacy of nutritional therapy for active Crohn's disease. *Journal of Gastroenterology* 1995;**30**(SUPPL. 8):83-87.
7. Markowitz J, Rosa J, Grancher K, et al. Long-term 6-mercaptopurine treatment in adolescents with Crohn's disease. *Gastroenterology* 1990;**99**(5):1347-51.
8. Russell RI, Hall MJ. Elemental diet therapy in the management of complicated Crohn's disease. *Scottish Medical Journal* 1979;**24**(4):291-95.
9. Tsujikawa T, Araki Y, Makino J, et al. Efficacy of oral adsorbent for treatment of peristomal fistula associated with Crohn's disease. *Journal of Gastroenterology* 2000;**35**(4):296-8.
10. Borody T, Wettstein A, Leis S, et al. Resistant fistulizing crohns disease treated with combination of infliximab, anti-map and hyperbaric oxygen (HBO). *American Journal of Gastroenterology* 2012;**107**:S670.
11. Brady CE, 3rd, Cooley BJ, Davis JC. Healing of severe perineal and cutaneous Crohn's disease with hyperbaric oxygen. *Gastroenterology* 1989;**97**(3):756-60.
12. Brady ICE. Hyperbaric oxygen and perineal Crohn's disease: A follow-up [2]. *Gastroenterology* 1993;**105**(4):1264.

13. Colombel JF, Mathieu D, Bouault JM, et al. Hyperbaric oxygenation in severe perineal Crohn's disease. *Dis Colon Rectum* 1995;**38**(6):609-14.
14. Lavy A, Weisz G, Adir Y, et al. Hyperbaric oxygen for perianal Crohn's disease. *J Clin Gastroenterol* 1994;**19**(3):202-5.
15. Sipahi AM, Damiao AO, de Sousa MM, et al. Hyperbaric oxygen: a new alternative in the treatment of perianal Crohn's disease. *Revista do Hospital das Clinicas* 1996;**51**(5):189-91.
16. Espin E, Calero A, Jimenez LM, et al. Platelet derived growth factors in the treatment of Crohn's disease anal fistula first results. *Colorectal Disease* 2011;**13**:23.
17. Kurtz MP, Svensson E, Heimann TM. Use of platelet-derived growth factor for delayed perineal wound healing in patients with inflammatory bowel disease: a case series. *Ostomy/wound management* 2011;**57**(4):24-31.
18. Magno P, Jimenez CE, Ortiz Z, et al. Recombinant human granulocyte-macrophage colony stimulating factor (sargramostim) as an alternative therapy for fistulizing Crohn's disease. *P R Health Sci J* 2010;**29**(1):60-5.
19. Fukuda Y, Takazoe M, Sugita A, et al. Oral spherical adsorptive carbon for the treatment of intractable anal fistulas in Crohn's disease: a multicenter, randomized, double-blind, placebo-controlled trial. *American Journal of Gastroenterology* 2008;**103**(7):1721-9.
20. Reinisch W, Travis S, Hanauer S, et al. AST-120 (Spherical Carbon Adsorbent) in the Treatment of Perianal Fistulae in Mild-to-Moderate Crohn's Disease: FFAST-1, a Phase 3, Multicenter, Placebo-controlled Study. *Inflamm Bowel Dis* 2014.
21. Bariol C, Meagher AP, Vickers CR, et al. Thalidomide for inflammatory bowel disease: Early studies on the safety and efficacy of thalidomide for symptomatic inflammatory bowel disease. *Journal of Gastroenterology and Hepatology* 2002;**17**(2):135-39.
22. Ehrenpreis ED, Kane SV, Cohen LB, et al. Thalidomide therapy for patients with refractory Crohn's disease: an open-label trial. *Gastroenterology* 1999;**117**(6):1271-7.

23. Felipez LM, Gokhale R, Tierney M, et al. Long-term thalidomide use and outcomes in pediatric patients with refractory Crohn's disease. *Journal of Pediatric Gastroenterology and Nutrition* 2010;**51**:E88.
24. Kane S, Stone LJ, Ehrenpreis E. Thalidomide as "salvage" therapy for patients with delayed hypersensitivity response to infliximab: a case series. *J Clin Gastroenterol* 2002;**35**(2):149-50.
25. Ng SC, Plamondon S, Gupta A, et al. Prospective evaluation of anti-tumor necrosis factor therapy guided by magnetic resonance imaging for Crohn's perineal fistulas. *Am J Gastroenterol* 2009;**104**(12):2973-86.
26. Plamondon S, Ng SC, Kamm MA. Thalidomide in luminal and fistulizing Crohn's disease resistant to standard therapies. *Alimentary Pharmacology and Therapeutics* 2007;**25**(5):557-67.
27. Quin A, Kane S, Ulitsky O. A case of fistulizing Crohn's disease and erythema nodosum managed with adalimumab. *Nature Clinical Practice Gastroenterology and Hepatology* 2008;**5**(5):278-81.
28. Subhas G, Gupta A, Balaraman S, et al. Non-cutting setons for progressive migration of complex fistula tracts: a new spin on an old technique. *Int J Colorectal Dis* 2011;**26**(6):793-8.
29. Schwandner O. Video-assisted anal fistula treatment (VAAFT) combined with advancement flap repair in Crohn's disease. *Tech Coloproctol* 2013;**17**(2):221-5.
30. Poggioli G, Laureti S, Pierangeli F, et al. Local injection of Infliximab for the treatment of perianal Crohn's disease. *Dis Colon Rectum* 2005;**48**(4):768-74.
31. Asteria CR, Ficari F, Bagnoli S, et al. Treatment of perianal fistulas in Crohn's disease by local injection of antibody to TNF-alpha accounts for a favourable clinical response in selected cases: a pilot study. *Scand J Gastroenterol* 2006;**41**(9):1064-72.
32. Tonelli F, Giudici F, Asteria CR. Effectiveness and safety of local adalimumab injection in patients with fistulizing perianal Crohn's disease: a pilot study. *Dis Colon Rectum* 2012;**55**(8):870-5.
33. Alessandrini L, Kohn A, Cosentino R, et al. Local injection of infliximab in severe fistulating perianal Crohn's disease: an open uncontrolled study. *Tech Coloproctol* 2011;**15**(4):407-12.

34. Moy J, Bodzin J. Carbon dioxide laser ablation of perianal fistulas in patients with Crohn's disease: experience with 27 patients. *Am J Surg* 2006;**191**(3):424-7.
35. Prosst RL, Herold A, Joos AK, et al. The anal fistula claw: the OTSC clip for anal fistula closure. *Colorectal Dis* 2012;**14**(9):1112-7.
36. Prosst RL, Ehni W. The OTSC(R) Proctology clip system for anorectal fistula closure: the 'anal fistula claw': case report. *Minim Invasive Ther Allied Technol* 2012;**21**(4):307-12.