

# Can <sup>111</sup>indium autologous mixed leucocyte scanning accurately assess disease extent and activity in Crohn's disease?

R H R PARK, J H MCKILLOP, A DUNCAN, J F MACKENZIE,  
AND R I RUSSELL

*From the Gastroenterology Unit and University Department of Medicine, Royal Infirmary, Glasgow*

**SUMMARY** <sup>111</sup>Indium autologous mixed leucocyte scanning has recently been used for the investigation of Crohn's disease. Nineteen patients had indium scans to assess disease extent and activity. The scans were compared with conventional imaging techniques and indices of disease activity including clinical scores, ESR, CRP, and GI protein loss. In five patients with active disease the scans were negative and overall there was poor correlation between the scan scores and the other indices of disease activity. Indium scanning correctly located extent of disease in only 58% of patients. <sup>111</sup>Indium mixed leucocyte scanning may be more suited for the assessment of disease extent and activity in severely ill patients with Crohn's disease.

<sup>111</sup>Indium autologous leucocyte scanning is a new non-invasive method of assessing disease extent in Crohn's disease and several groups have found it to be as reliable as conventional radiology or endoscopic methods.<sup>1-5</sup> Buxton-Thomas *et al*, however, found that indium scanning, using mixed leucocytes and indium oxine, did not offer sufficient accuracy to replace conventional methods of assessment.<sup>6</sup>

Several authors have also used indium scanning in the assessment of Crohn's disease activity.<sup>1-6</sup> There are many different methods of assessing disease activity including various clinical scoring systems which rely heavily on subjective indices. Laboratory tests, including the measurement of acute phase proteins and gastrointestinal protein loss, offer more objective assessments but are not specific for intestinal inflammation.<sup>8-10</sup> Agreement on the best method of assessing Crohn's disease activity has not been achieved but the Crohn's disease activity index (CDAI) is the most widely used clinical method.<sup>11</sup>

Previous reports have found a good correlation between indium scan activity and the CDAI, and this is improved if faecal indium activity is measured.<sup>12</sup> Only Saverymuttu *et al*, however, have used an alternative method of assessing disease activity other than the CDAI. Forty three patients with inflamma-

tory bowel disease limited to the colon (15 with Crohn's disease) had indium scan and colonoscopy with biopsy and there was good correlation between the histological assessment of disease activity and the scan activity.<sup>5</sup> There have, however, been no other reports of the value of indium scanning in assessing Crohn's disease activity using methods other than the CDAI.

The aims of our study were: (1) to compare the indium scan activity with multiple indices of Crohn's disease activity; (2) to assess the accuracy of indium scanning in determining the location and extent of the disease.

## Methods

### PATIENTS

Nineteen patients with Crohn's disease (16 women, three men, median age 29, range 16-62) who required hospital admission were studied. Four patients had two assessments and therefore 23 sets of results are available. Extent of disease was established using conventional radiology and colonoscopy and limited to the small intestine (six patients), small and large intestines (four), ileocaecal (three), colon (four) and ileocolonic anastomosis (two). Two patients had an ileostomy and one a colostomy. Indium scanning was done within five days of the conventional imaging techniques and before any

Address for correspondence: Dr R I Russell, Gastroenterology Unit, Royal Infirmary, Glasgow G31 2ER.

Received for publication 12 January 1988.

Table 1 Patients' clinical details and disease activity assessment

Patient number	Sex	Age	Drugs	Previous resections	Extent of disease		Disease activity					
					Radiology/endoscopy	Scan	CDAI	MOD CDI	ESR mm/h	CRP mg/l	GI protein loss ml/24h	Scan
1a	F	28	—	—	SI, S/R	RC	206	6	38	41	110	3
b			EN	—	—	—	71	0	10	10	90	1
2	F	28	—	R Hemi	SI	SI, TC, DC	269	4	52	30	60	3
3	F	51	SSZ	—	SI, DC	Neg	250	4	29	16	118	0
4	F	53	SSZ	—	DC, S/R	Neg	440	10	65	79	175	0
5	F	28	—	Colectomy	SI	SI	—	4	34	18	23	2
6a	F	32	—	R Hemi	SI, S/R	SI, S/R	337	6	36	16	295	3
b			EN	—	—	—	196	3	39	35	230	5
7	F	58	—	R Hemi, colostomy	SI, DC	SI, DC	—	6	35	15	147	2
8	F	28	—	Colectomy	SI	Neg	—	4	23	15	195	0
9	M	20	SSZ, Pred	—	DC, S/R	DC, S/R	299	3	46	24	42	5
10	F	29	SSZ, Pred	—	SI	Neg	243	3	20	58	165	0
11a	F	42	—	—	TC, DC, S/R	TC, DC, S/R	384	6	55	93	44	6
b			EN	—	—	—	89	0	15	10	40	1
12	F	62	SSZ	—	RC	RC	160	3	16	11	11	1
13	F	23	Pred	R Hemi	Anastomosis, S/R	S/R	402	8	46	61	72	4
14a	F	35	—	—	RC	RC	170	3	54	15	23	2
b			EN	—	RC	RC	205	3	45	10	45	1
15	M	28	SSZ, Pred	R Hemi	Anastomosis, S/R	S/R	290	5	30	51	42	1
16	M	25	—	R Hemi	SI	SI	154	3	34	28	26	2
17	F	16	—	—	RC, TC	RC, TC	70	1	30	62	39	2
18	F	23	SSZ	—	RC	Neg	160	2	40	48	36	0
19	F	32	SSZ	—	SI	RC	223	4	58	47	116	1

R Hemi – right hemicolectomy; S/R – Sigmoid/rectum; SI – Small intestine; SSZ – Sulphasalazine; RC – Right colon; PRED – Prednisolone; TC – Transverse colon; EN – Enteral nutrition; DC – Descending colon; Neg – Negative scan.

change in therapy. Several patients were taking prednisolone and/or sulphasalazine during the period of disease activity assessment (Table 1).

#### INDIUM SCANNING

Fifty millilitres of venous blood were taken from each patient and mixed with 2000 U heparin and 8 ml hetastarch. This mixture was gravity separated for one hour. The white blood cell layer was separated and centrifuged and resuspended in 10 ml saline, and incubated for 45 minutes with 10–20 MBq <sup>111</sup>indium oxine. Further centrifugation was done to yield the labelled cell button which was resuspended in 10 ml saline and reinjected intravenously. Gamma camera scans were carried out at four hours, anterior images of the abdomen and pelvis being obtained using a wide field of view gamma camera interfaced to a microcomputer.

Using a similar technique of leucocyte scintigraphy for the investigation of intra-abdominal abscesses we found that the physiological activity of the indium labelled leucocytes was satisfactory.<sup>13</sup>

#### DISEASE ACTIVITY INDICES

Disease activity was assessed using two clinical scores: the Crohn's disease activity index (CDAI),

and a modified Crohn's disease index (MOD CDI) based on the Bristol simple index<sup>14</sup> but changing the scoring for stool frequency to 0=no loose stools per day, 1=less than or equal to three per day, 2=greater than three per day and for stoma patients 0=normal stoma output, 1=increased output, 2=greatly increased and very loose output; erythrocyte sedimentation rate (ESR); C-reactive protein (CRP); <sup>51</sup>CrCl<sub>3</sub> GI protein loss test<sup>10,15</sup>; and <sup>111</sup>indium autologous mixed leucocyte scan.

The indium scan activity score was calculated by dividing the scanned area into five segments, the small intestine, right colon, transverse colon, descending colon, and sigmoid colon/rectum, and for each segment an activity score of 0=no activity, 1≤marrow activity, 2≤liver activity, 3≤splenic activity, 4>splenic activity was allocated and summed to give a theoretical maximum score of 20. Each scan was scored blindly by a nuclear medicine physician (JHMCK).

#### STATISTICAL ANALYSIS

The Spearman rank correlation coefficient (rs) was calculated for the indium scan activity scores and the other indices of disease activity, and only p values <0.05 were considered to be significant.

Table 2 Disease activity assessment

	Median	Range
CDAI	215	70-440
MOD CDI	4	0-10
ESR	36	10-65 mm/h
CRP	28	10-93 mg/l
CrCl <sub>3</sub> protein loss	60	11-255 ml/24 h
Indium scan	2	0-6

(Normal values or values indicating quiescent disease CDAI <150, MOD CDI <2, ESR <20 mm/h, CRP <10 mg/l, CrCl<sub>3</sub> protein loss <25 ml/24 h, scan score 0.)

**Results**

All patients had technically satisfactory indium scans with no pooling of leucocytes in the lungs.

**DISEASE ACTIVITY**

Twenty three sets of results are available (Table 1) and are summarised in Table 2. The CDAI was not calculated for the three stoma patients. There were no significant correlations between the indium scan activity scores and the other indices of disease activity - CDAI (rs=0.25, p>0.1), MOD CDI (rs=0.27, p>0.1), ESR (rs=0.4, p>0.5), CRP (rs=0.2, p>0.01), and CrCl<sub>3</sub> GI protein loss test (rs=0.04, p>0.1) (Figs 1-5).

**DISEASE LOCATION**

Indium scanning showed correct location of disease in 58% of patients (Table 3). In five patients the scans were negative despite extensive disease in three patients. Extent of disease was underestimated in

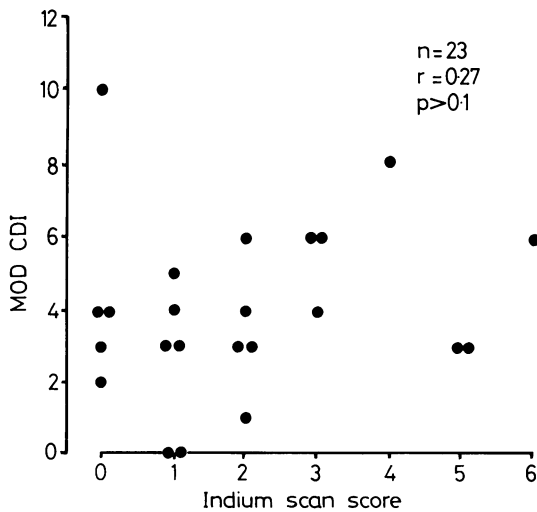


Fig. 1 Comparison of indium scan score and MOD CDI.

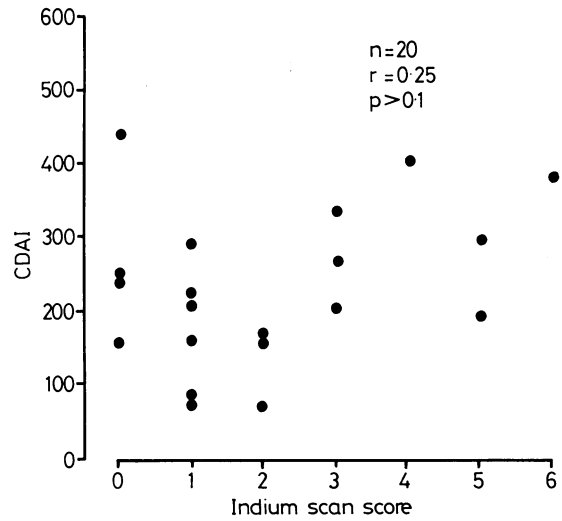


Fig. 2 Comparison of indium scan score and CDAI.

one patient with small and large intestinal disease. In two patients with small intestinal disease alone the scans were reported as showing small and large intestinal disease (patient 2) and only right colonic disease in patient 19. Radiology but not colonoscopy had been performed on patient 2 and both investigations on the other patient.

**Discussion**

Our study did not confirm previous reports of the value of indium scanning in the assessment of disease activity and extent in patients with Crohn's

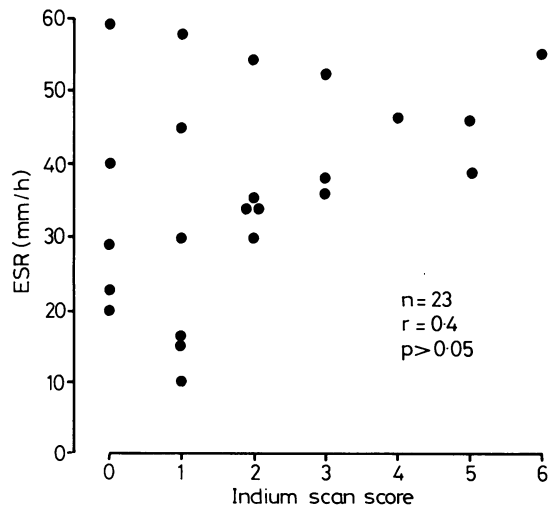


Fig. 3 Comparison of indium scan score and ESR.

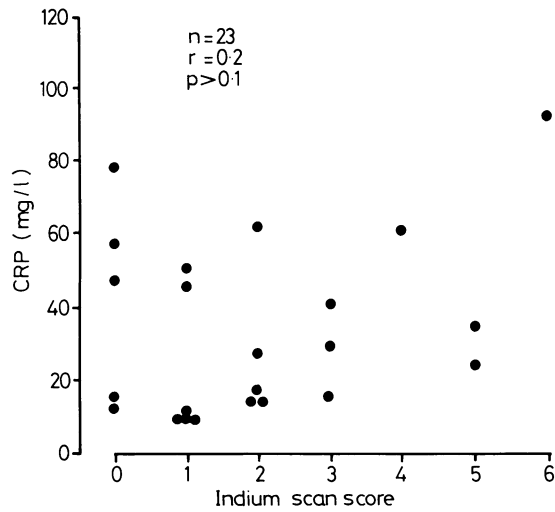


Fig. 4 Comparison of indium scan score and CRP.

disease.<sup>1-5,12</sup> We found that the indium scan activity scores did not correlate with the other disease activity indices and five patients with unequivocally active disease indices and five patients with unequivocally active disease had negative scans. Indium scanning correctly located extent of disease in 58% of our patients. As we have mentioned earlier at present there is not an ideal gold standard for assessing disease activity in Crohn's disease. It was not the purpose of this study to solve this problem but to compare the performance of indium scanning with other commonly used indices. We would not consider

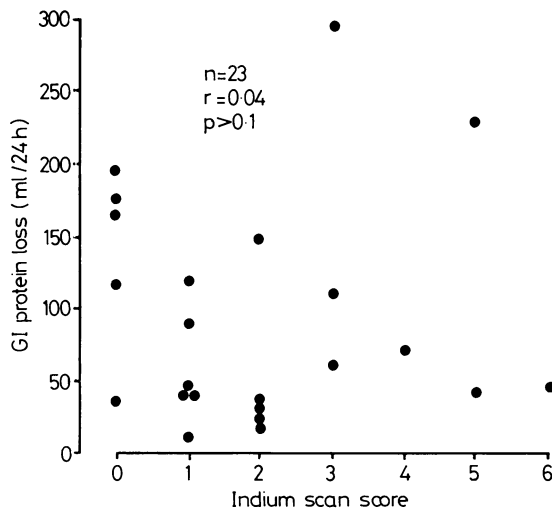


Fig. 5 Comparison of indium scan score and GI protein loss.

Table 3 Location of disease by indium scan

	Correct	Incorrect	Negative
Small intestine (6)	2	2	2
Small and large intestines (4)	2	1	1
Ileocaecal (3)	2		1
Colonic (4)	3		1
Ileo-colonic anastomosis (2)	2		

Patient numbers in parenthesis.

GI protein loss to be the ideal marker as it is not specific for intestinal inflammation. In fact two of our patients (patients 1, 11) had rather conflicting results when their GI protein loss was measured serially in comparison with the other disease activity indices. It is apparent that when using only one method, whether clinical scores or laboratory test, assessment of Crohn's disease activity can be extremely difficult. In our own experience from this study we were disappointed with the performance of indium scanning, especially when five patients had negative scans.

Two possible reasons could explain this discrepancy: poor scan technique or an actual limitation of indium mixed leucocyte scanning in detecting active inflammatory bowel disease. In every case our scan appeared to be technically satisfactory with approximately 70% average labelling efficiency of leucocytes which is considered to be adequate and comparable with other groups' results.<sup>4,5</sup> Scanning technique may be improved slightly by using pure granulocyte preparations and substituting indium troponolate for indium oxine as the chelating agent.<sup>4,5</sup> Unfortunately, preparation for the pure granulocyte scans is much more complicated and outwith the routine facilities of a nuclear medicine department. Indium troponolate is not yet widely available, and indium oxine mixed leucocyte scintigraphy is still the most widely used method. Datz *et al* found that leucocytes labelled by either oxine or tropolone had similar physiological activity in a study comparing both methods in the detection of occult infection.<sup>16</sup> We are therefore confident that our indium mixed leucocyte scans were technically satisfactory and the poor correlation with the other disease indices is because of the limitation of the mixed leucocyte scan in detecting active inflammatory bowel disease. As mentioned earlier studies using indium troponolate pure granulocyte scans have had better results and this type of scan may be more sensitive in detecting inflammatory bowel disease.

Faecal indium activity may offer a more accurate method of disease activity assessment.<sup>12</sup> In fact many patients with apparently quiescent disease on clinical scores have raised faecal indium excretion.<sup>17</sup> The

limitation of this technique is the requirement for complete stool collection and processing.

From our study there are reasonable grounds to suggest that indium oxine mixed leucocyte scintigraphy has considerable limitations in the assessment of disease extent and activity in Crohn's disease and we routinely use conventional radiology and colonoscopy. We do believe, however, that indium oxine mixed leucocyte scanning does have a part to play in the overall assessment of patients with Crohn's disease especially when faced with severely ill patients or patients in whom an intra-abdominal abscess is suspected.

## References

- 1 Segal AW, Ensell J, Munro JM, Sarner M. Indium 111 tagged leucocytes in the diagnosis of inflammatory bowel disease. *Lancet* 1981; ii: 230-2.
- 2 Stein DT, Gray GM, Gregory PB, Anderson M, Goodwin DA, McDougall IR. Location and activity of ulcerative and Crohn's colitis by indium 111 leukocyte scan. *Gastroenterology* 1983; **84**: 388-93.
- 3 Saverymuttu SH, Peters AM, Hodgson HJ, Chadwick VS, Lavender JP. Indium 111 autologous leucocyte scanning: comparison with radiology for imaging the colon in inflammatory bowel disease. *Br Med J* 1982; **285**: 255-7.
- 4 Saverymuttu SH, Lavender JP, Hodgson HJF, Chadwick VS. Assessment of disease activity in inflammatory bowel disease: a new approach using 111 In granulocyte scanning. *Br Med J* 1983; **287**: 1751-3.
- 5 Saverymuttu SH, Camilleri M, Rees H, Lavender JP, Hodgson HJF, Chadwick VS. Indium 111-granulocyte scanning in the assessment of disease extent and disease activity in inflammatory bowel disease. *Gastroenterology* 1986; **90**: 1121-8.
- 6 Buxton-Thomas MS, Dickinson RJ, Maltby P, Hunter JO, Wraight EP. Evaluation of indium scintigraphy in patients with active inflammatory bowel disease. *Gut* 1984; **25**: 1372-5.
- 7 Chapman RWG, Jewell DP. Assessment of activity. In: Jewell DP, Shepherd HA, eds. *Topics in gastroenterology*. No 11. Oxford: Blackwell Scientific Publications, 1983.
- 8 Andre C, Descos L, Landais P, Fermanian J. Assessment of appropriate laboratory measurements to supplement the Crohn's disease activity index. *Gut* 1981; **22**: 571-4.
- 9 Fagan EA, Dyck RF, Maton PN, et al. Serum levels of C-reactive protein in Crohn's disease and ulcerative colitis. *Eur J Clin Invest* 1982; **12**: 351-9.
- 10 Logan RFA, Gillon J, Ferrington C, Ferguson A. Reduction of gastrointestinal protein loss by elemental diet in Crohn's disease of the small bowel. *Gut* 1981; **22**: 383-7.
- 11 Best WR, Beckett JM, Singleton JW, Kern F. Development of a Crohn's disease activity index. *Gastroenterology* 1976; **70**: 439-44.
- 12 Saverymuttu SH, Peters AM, Lavender JP, Pepys MB, Hodgson HJF, Chadwick VS. Quantitative faecal indium 111-labelled leukocyte excretion in the assessment of disease in Crohn's disease. *Gastroenterology* 1983; **85**: 1333-9.
- 13 Baba AA, Anderson JR, McKillop JH, Cuthbert GF, Neilson W, Gray HW. Do white cell scans assist patient management? *Nuclear Med Commun* 1986; **7**: 277-8.
- 14 Harvey RF, Bradshaw JM. A simple index of Crohn's disease activity. *Lancet* 1980; i: 514.
- 15 Van Tongeren JHM, Reichert WJ. Demonstration of protein losing gastroenteropathy: the quantitative estimation of gastrointestinal protein loss using 51Cr labelled plasma proteins. *Clin Chim Acta* 1966; **14**: 42-8.
- 16 Datz FL, Bedont RA, Baker WJ, Alazraki NP, Taylor A. No difference in sensitivity for occult infection between tropolone - and oxine - labelled indium 111 leucocytes. *J Nuclear Med* 1985; **26**: 469-73.
- 17 Saverymuttu SH. Clinical remission in Crohn's disease - assessment using faecal 111 In granulocyte excretion. *Digestion* 1986; **33**: 74-9.