

CASE REPORTS

IgA nephropathy in non-cirrhotic portal hypertension

C Babbs, T W Warnes, H B Torrance, F W Ballardie

Abstract

Renal glomerular changes are a well recognised complication of cirrhosis¹⁻³ and are frequently characterised by mesangial IgA deposition.⁴⁻⁸ We report a patient with non-cirrhotic portal hypertension who developed IgA nephropathy and a nephrotic syndrome with renal histological changes classically associated with cirrhosis. Splenectomy with resection of a splenic artery aneurysm resulted in remission of the nephrotic syndrome. This case illustrates the factors which contribute to the pathogenesis of IgA nephropathy in liver disease.

Case report

A 4 year old white boy was admitted to hospital after a haematemesis and was found on examination to have splenomegaly. He had been a normal full term delivery and there was no history of umbilical sepsis. Liver function tests and liver biopsy were normal. Splenoportography showed an obstruction to the flow of contrast at the hilum of the liver, and an extensive collateral circulation. Oesophageal transection was required at the age of 10 years because of recurrent variceal bleeding.

In 1986, aged 30, he presented to hospital because of intermittent ankle swelling for two years and abdominal distension for two weeks. No other significant past history was noted and he denied taking regular medication. There was no personal or family history of renal disease. Examination showed pedal and sacral oedema but no evidence of heart failure. There were no stigmata of chronic liver disease. The abdomen was distended with ascites, the spleen enlarged, and a pulsatile mass was palpated in the left upper quadrant. Investigations showed haemoglobin 106 g/l, platelets $49 \times 10^9/l$, prothrombin time 15.5 s (control 14.5), bilirubin 17 $\mu\text{mol/l}$ (normal $<22 \mu\text{mol/l}$), alanine transaminase 20 U/l (normal 5-40), alkaline phosphatase 119 U/l (normal 70-330), albumin 22 g/l, globulins 16 g/l (IgG 2.7, IgA 2.15, IgM 1.25), blood urea 4.6 mmol/l (normal 3.5-7.4), and serum creatinine 68 $\mu\text{mol/l}$ (normal <110). The 24 hour urinary protein excretion was 7.03 g and creatinine clearance 109 ml/min.

Upper gastrointestinal endoscopy showed gross oesophageal varices. Ultrasonography confirmed the presence of ascites and splenomegaly; the liver and kidneys were normal.

Mesenteric angiography identified the pulsatile mass as a large splenic artery aneurysm and showed an extensive venous collateral circulation.

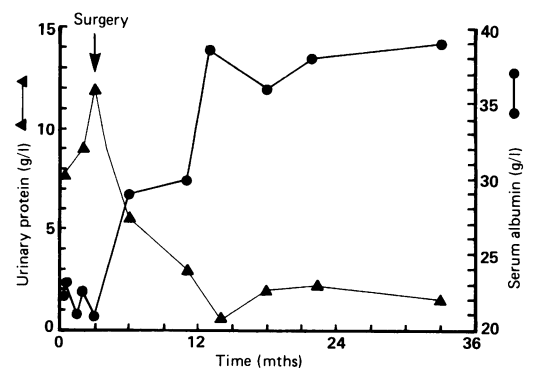
Since the aneurysm was clinically enlarging and was associated with increasing upper abdominal pain, laparotomy was undertaken. At operation the liver was macroscopically normal; the spleen was massively enlarged and pulsatile, and a huge aneurysm was found arising from the origin of the splenic artery. Splenectomy with distal ligation of the aneurysm was performed and renal and liver biopsy specimens were taken.

Microscopically the liver was entirely normal. The renal glomeruli showed moderate mesangial expansion and excess matrix, and the capillary basement membrane showed focal thickening. Immunofluorescence showed diffuse granular deposits predominantly of IgA, as well as IgM and C1q. The changes were those of a mesangial proliferative glomerulopathy associated with IgA and IgM deposition, typical of the IgA nephropathy associated with cirrhosis.

After operation there was a striking and progressive fall in urinary protein excretion with remission of the nephrotic syndrome (Figure). In addition, the haematuria cleared, with a fall in urinary red cell content from $500 \times 10^6/24$ hours preoperatively to normal ($<1 \times 10^6/24$ hours). There was no further gastrointestinal bleeding, and a pronounced reduction in the size of the oesophageal varices was noted at follow up endoscopy.

Discussion

IgA nephropathy is an important cause of end stage kidney disease and may be primary



Sequential changes in serum albumin and urinary protein excretion after splenectomy and resection of splenic artery aneurysm.

Liver Unit, University
Department of
Gastroenterology
C Babbs
T W Warnes

Department of Surgical
Gastroenterology
H B Torrance

Department of Renal
Medicine, Manchester
Royal Infirmary,
Manchester M13 9XJ
F W Ballardie

Correspondence to:
Dr C Babbs, Department of
Medicine, North Manchester
General Hospital, Delaunays
Road, Crumpsall, Manchester
M8 6RB.

Accepted for publication
19 March 1990

(Berger's disease) or secondary to other conditions including hepatobiliary disorders.⁹ Renal IgA deposition in cirrhosis was first reported in 1970 and has since been widely recognised, being found in between 33% and 90% of cases in different series.⁴⁻⁸ Similar changes have also been reported in patients with advanced liver disease due to cystic fibrosis¹⁰ and in experimental cirrhosis.¹¹ Although the cirrhosis associated IgA nephropathy is often clinically silent, it may lead to microscopic haematuria but it is doubtful whether macroscopic haematuria occurs. Haematuria is less common than in patients with primary IgA nephropathy.^{5,12} Proteinuria into the nephrotic range, as seen in the present case, has been reported in between 1.6% and 14% of patients with cirrhosis^{7,13} and was found in 11 of 34 patients with overt glomerulonephritis and IgA deposition in association with alcoholic liver disease.⁵

Although a number of clinical and immunopathological features distinguish primary IgA nephropathy from that associated with liver disease, suggesting that they are distinct entities,¹⁴ the pathogenesis of the latter remains uncertain. Current evidence suggests that liver disease related nephropathy is mediated by immune complexes with IgA derived from mucosal associated plasma cells.^{9,15} Glomerular deposits are of IgA subclass 2, the predominant form of mucosal IgA, and contain secretory component as distinct from deposits in primary IgA nephropathy where IgA subclass 1 predominates.¹⁵ Definitive experiments, however, with isotopically labelled antigens or IgA have not been carried out in humans. The primary disease is characterised by hypersensitivity to many common exogenous antigens, and IgA antibodies with specificity for ubiquitous food and bacterial antigens have been found in patients' sera. Increased responsiveness of IgA isotype antibodies to environmental antigens in patients with primary IgA nephropathy is evidence for a fundamental regulatory defect in the immune system.¹⁵ In liver disease associated IgA nephropathy, however, the nature of the antigen may be less important than the integrity of the mechanisms which normally regulate antigen entry and removal,¹⁶ and in cirrhosis it has been suggested that impaired clearance of immune complexes by hepatic Kupffer cells may allow them access to the systemic circulation and subsequent deposition in the kidney.^{11,12} Shunting of portal venous blood to the systemic circulation, however, thereby by passing the liver, has been shown to increase renal IgA deposition in mice infected with schistosomiasis¹⁷ and in a patient with portal vein thrombosis and a lienorenal shunt.¹⁶ In addition, Laurent *et al* reported a case of IgA mesangial glomerulonephritis and alcoholic steatosis, in whom proteinuria and haematuria resolved after the creation of a portocaval shunt which reduced portal pressure from 30 to 18 cm H₂O.¹⁸ Thus the

importance of portosystemic shunting in the development of IgA nephropathy in cirrhosis is controversial.

The present case shows that IgA nephropathy, histologically identical to that seen in cirrhosis, may occur with non-cirrhotic portal hypertension and a morphologically normal liver. The important feature of the present case is the striking remission of the nephrotic syndrome and haematuria after surgery. The pulsatile spleen and large splenic artery aneurysm suggest that the spleen was acting as an arteriovenous fistula which was contributing to the portal hypertension,¹⁹ particularly since splenectomy and resection of the aneurysm was associated with an appreciable reduction in the size of the oesophageal varices. The remission of the nephrotic syndrome after alteration of the splanchnic haemodynamics provides support for the hypothesis that this nephropathy is causally related to shunting of immune complexes past the liver rather than impaired liver cell function and therefore contributes to our understanding of the pathogenesis of IgA nephropathy in liver disease.

We thank Dr S Sonkadi for helpful discussion.

- 1 Bloodworth TMB Jr, Sommers SC. 'Cirrhotic glomerulosclerosis', a renal lesion associated with hepatic cirrhosis. *Lab Invest* 1959; 8: 962-78.
- 2 Fisher ER, Hellstrom HR. The membranous and proliferative glomerulonephritis of hepatic cirrhosis. *Am J Clin Pathol* 1959; 32: 48-55.
- 3 Jones WT, Rao DRG, Braunstein H. The renal glomerulus in cirrhosis of the liver. *Am J Pathol* 1961; 39: 393-404.
- 4 Callard P, Feldman G, Prandi P, *et al*. Immune complex type glomerulonephritis in cirrhosis of the liver. *Am J Pathol* 1975; 80: 329-40.
- 5 Nochy D, Callard P, Bellon B, *et al*. Association of overt glomerulonephritis and liver disease: a study of 34 patients. *Clin Nephrol* 1976; 6: 422-7.
- 6 Berger J, Yaneva H, Nabarra B. Glomerular changes in patients with cirrhosis of the liver. *Adv Nephrol* 1977; 7: 3-14.
- 7 Nakamoto Y, Iida H, Kobayashi K, *et al*. Hepatic glomerulonephritis. Characteristics of hepatic IgA glomerulonephritis as the major part. *Virchows Arch (A)* 1981; 392: 45-54.
- 8 Sinniah R. Heterogeneous IgA glomerulonephropathy in liver cirrhosis. *Histopathology* 1984; 8: 947-62.
- 9 Emancipator SN, Gallo GR, Lamm ME. IgA nephropathy: perspectives on pathogenesis and classification. *Clin Nephrol* 1985; 24: 161-79.
- 10 Abramowsky CR, Swinehart GL, Dahms BB. IgA associated glomerular deposits in liver disease: studies in cystic fibrosis as a human model. *Lab Invest* 1983; 48: 1A.
- 11 Gormly AA, Smith PS, Seymour AE, Clarkson AR, Woodroffe AJ. IgA glomerular deposits in experimental cirrhosis. *Am J Pathol* 1981; 104: 50-4.
- 12 Newell GC. Cirrhotic glomerulonephritis: incidence, morphology, clinical features and pathogenesis. *Am J Kidney Dis* 1987; 9: 183-90.
- 13 Eknayan G. Glomerular abnormalities in liver disease. In: Epstein M, ed. *The kidney in liver disease*. New York: Elsevier, 1983: 119-45.
- 14 Ballardie FW, Brenchley PEC, Williams S, O'Donoghue DJ. Autoimmunity in IgA nephropathy. *Lancet* 1988; ii: 587-92.
- 15 Ballardie FW. IgA nephropathies and Henoch Schonlein purpura. In: Pusey CD, ed. *Immunology of renal disease*. Dordrecht: Kluwer Academic (in press).
- 16 Woodroffe AJ, Gormly AA, McKenzie PE, *et al*. Immunologic studies in IgA nephropathy. *Kidney Int* 1980; 18: 366-74.
- 17 Van Marck EAE, Deelder AM, Gigase PLJ. Effect of partial portal vein ligation on immune glomerular deposits in *Schistosoma mansoni*-infected mice. *Br J Exp Pathol* 1977; 58: 412-7.
- 18 Laurent J, Lagrue G, Bruneau C, Kazandjian M. Does portal hypertension play a role in IgA mesangial glomerulonephritis (IgG GN)? [Abstract]. *Kidney Int* 1986; 30: 640.
- 19 Johnston GW, Gibson JB. Portal hypertension resulting from splenic arteriovenous fistulae. *Gut* 1965; 6: 500-2.