

# Subtypes of intestinal metaplasia and *Helicobacter pylori*

M E Craanen, P Blok, W Dekker, J Ferwerda, G N J Tytgat

## Abstract

To determine whether there is a relationship between the presence of *H pylori* and the various subtypes of intestinal metaplasia in the gastric antrum, 2274 antral gastroscopic biopsies from 533 patients were examined. *H pylori* was found in 289 patients. Intestinal metaplasia in general was found in 135 patients. Type I intestinal metaplasia was found in 133 patients (98.5%), type II in 106 patients (78.5%) and type III in 21 patients (15.6%). Ninety eight of these 135 patients (72.6%) were *H pylori* positive and 37 patients (27.4%) were *H pylori* negative. No statistically significant difference was found in the prevalence of type I and II intestinal metaplasia between the intestinal metaplasia positive and *H pylori* positive and intestinal metaplasia negative and *H pylori* negative patients. Type III intestinal metaplasia was found less often in the intestinal metaplasia positive and *H pylori* positive patients (11.2%) as compared with intestinal metaplasia positive and *H pylori* negative patients (27%) ( $p < 0.05$ ). In contrast with type I and II intestinal metaplasia type III intestinal metaplasia was found more often in moderate/severe intestinal metaplasia than in mild intestinal metaplasia ( $p < 0.02$ ). Within the group of patients with moderate/severe intestinal metaplasia, type III was found less often in the *H pylori* positive patients ( $p < 0.05$ ). We suggest that the gastric milieu for *H pylori* is less appropriate in type III intestinal metaplasia positive patients. As type III intestinal metaplasia might be regarded as a marker of possibly increased gastric cancer risk, the lower prevalence of *H pylori* in these type III intestinal metaplasia positive patients might be the result of severe changes in mucosal architecture.

There is overwhelming evidence that infection with *Helicobacter pylori* causes chronic active gastritis, which invariably involves the gastric antrum.<sup>1-3</sup> Although acute gastritis has been described in volunteers after ingestion of *H pylori*,<sup>4,5</sup> this condition is rarely encountered and biopsied in routine clinical practice. Eradication of *H pylori* may lead to rapid reversion of the histological abnormalities found in *H pylori* related gastritis.<sup>3,6</sup> Failure to eradicate *H pylori* totally, however, yields only temporary improvement of the histological picture. This, in turn, may eventually lead to the progression of chronic active gastritis to chronic gastritis with a variable degree of atrophy.

Chronic atrophic gastritis and its accompan-

ing lesion, intestinal metaplasia are widely recognised as being the most prevalent precursors of intestinal type gastric carcinoma.<sup>7</sup> Subtypes of intestinal metaplasia have been identified based upon histological, ultrastructural, enzyme, and mucin histochemical characteristics. Some of the latter studies have suggested that a sulphomucin secreting, incomplete intestinal metaplasia subtype is particularly closely linked to intestinal type gastric carcinoma and may therefore be a marker of increased gastric cancer risk.<sup>8-13</sup> In another study evidence was found for a strong association between the presence of intestinal metaplasia in general and *H pylori* in the gastric antral mucosa.<sup>14</sup> We undertook this study in order to investigate further the relationship between the presence of *H pylori* and the various subtypes of intestinal metaplasia in the gastric antral mucosa.

## Patients

### METHODS

All patients were referred to the St Elisabeth's of Groote Gasthuis on clinical grounds for upper gastrointestinal endoscopy between December 1988 and June 1990. Endoscopy was carried out after an overnight fast. The endoscopes (Olympus GIF Q10,Q20) were cleaned with detergent, disinfected with 70% ethanol and rinsed with sterile water after each examination. Patients requiring emergency endoscopy or with previous gastric surgery were excluded.

Patients with antral abnormalities, varying from mild erythema of the mucosa to full blown endoscopic gastritis, gastric ulcer and carcinoma were included. The number of antral biopsies taken depended on the diagnosis made by the endoscopists. Biopsies were taken at 3 cm from the pylorus in mild erythema of the antral mucosa and in cases where there was severe endoscopic erythematous/exudative gastritis with or without erosions. Where gastric ulcer and carcinoma were present, biopsies were taken from the lesions and from the adjacent mucosa within 1 cm of the lesions along the lesser and greater curvature within 4 cm from the pylorus. All biopsies were fixed in 10% formalin, embedded in paraffin and cut at 5  $\mu$ m. Routine staining with haematoxylin and eosin (H&E) was performed for histopathologic diagnosis and detection of *H pylori*. Where it was doubtful whether *H pylori* was present, additional Giemsa staining was carried out. *H pylori* was judged to be absent where both staining methods were negative for *H pylori*.

The extent of intestinal metaplasia as well as

Department of Internal Medicine, St Elisabeth's of Groote Gasthuis, Boerhaavelaan, Haarlem, The Netherlands  
M E Craanen  
W Dekker  
J Ferwerda

Department of Pathology, Public Health Laboratory, Haarlem, The Netherlands  
P Blok

Department of Gastroenterology and Hepatology Academic Medical Centre, Amsterdam, The Netherlands  
G N J Tytgat

Correspondence to: M E Craanen, Department of Gastroenterology and Hepatology, Academic Medical Centre, Meibergdreef 9, 1105 AZ, Amsterdam, The Netherlands.

Accepted for publication 12 August 1991

the prevalence of its subtypes was assessed independently by two of the authors (MC/PB). The extent of distribution of intestinal metaplasia was graded as follows: (1) none (-); (2) mild degree (+), consisting of a few tubules to one third of the total area biopsied; (3) moderate degree (++), consisting of one third to two thirds of the total area biopsied; (4) severe degree (+++); consisting of two thirds or more of the total area biopsied. Biopsies showing intestinal metaplasia were serially sectioned and stained with: (1) alcian blue pH 2.5/periodic acid-Schiff (AB pH 2.5/PAS); (2) high iron diamine/alcian blue pH 2.5 (HID/AB pH 2.5) in order to identify subtypes of intestinal metaplasia.<sup>15 16</sup> Subtypes of intestinal metaplasia were classified as described by Filipe.<sup>17</sup>

Type I intestinal metaplasia is characterised by the presence of goblet cells secreting acid sialomucins and sometimes sulphomucins, Paneth cells and mature, non-mucous secreting, absorptive cells. Type II is characterised by the presence of goblet cells secreting sialomucins and sometimes sulphomucins, almost complete absence of Paneth cells and replacement of absorptive cells by columnar mucous cells secreting non-sulphated mucins, and type III resembles type II intestinal metaplasia in most respects but the columnar mucous cells secrete predominantly sulphomucins.

#### STATISTICAL ANALYSIS

The  $\chi^2$  correct test and two tailed Student's *t* test were used in the statistical analysis of the data collected when appropriate.

#### Results

A total of 2274 biopsies was examined from 533 patients. Intestinal metaplasia was found in 135 patients (25.3%) and *H pylori* was found in

289 patients (54.2%) (Table I). In the group of 135 intestinal metaplasia positive patients, type I was found in 133 patients (98.5%), type II in 106 patients (78.5%) and type III in 21 patients (15.6%). Ninety eight of these 135 patients (72.6%) were *H pylori* positive and 37 patients (27.4%) were *H pylori* negative. Although the prevalence of type III intestinal metaplasia, in contrast with type I and II, increased with age, the difference in mean age between patients with type I, type II, and type III intestinal metaplasia (type I: 66 (14.1) years; type II intestinal metaplasia: 66.5 (13.1) years; type III intestinal metaplasia: 71 (12.9) years) did not reach statistical significance ( $0.05 \leq p \leq 0.1$ ). For age related prevalence of intestinal metaplasia, intestinal metaplasia subtypes and *H pylori*, see Table II.

#### RELATIONSHIP BETWEEN *H PYLORI* AND SUBTYPES OF INTESTINAL METAPLASIA (N=135)

No significant difference in prevalence of type I and II intestinal metaplasia was found between the *H pylori* positive patients (n=98) and the *H pylori* negative patients (n=37) – namely, type I intestinal metaplasia: 99% (97/98) v 97.3% (36/37) and type II 76.5% (75/98) v 83.9% (31/37). In contrast, the prevalence of type III was significantly lower in the *H pylori* positive patients than in the *H pylori* negative patients (11.2% (11/98) v 27% (10/37) –  $p < 0.05$ ).

Mild intestinal metaplasia was found in 103 patients (76.3%), moderate/severe intestinal metaplasia was found in 32 patients (23.7%). Although moderate/severe intestinal metaplasia was found more often in the *H pylori* negative group (32.4%) than in the *H pylori* positive group (20.4%), this difference was not statistically significant ( $0.2 < p \leq 0.3$ ). No significant difference was found in the prevalence of type I and II intestinal metaplasia between mild and moderate/severe intestinal metaplasia (type I: 98% v 100%, type II: 75.7% v 87.5%). Type III was found more often in cases of moderate/severe intestinal metaplasia (31.3%) than in cases of mild intestinal metaplasia (10.7%) ( $p < 0.02$ ). Moreover, in the group of patients with moderate/severe intestinal metaplasia (n=32) type III was found more often in *H pylori* negative patients (seven of 12) than in *H pylori* positive patients (three of 20) ( $p < 0.05$ ).

#### Discussion

Based on observations in populations with a high risk of developing gastric carcinoma, Correa postulated that intestinal type gastric carcinoma might be the end result of a long process of sequential histological changes. It is assumed that chronic active gastritis may progress to chronic gastritis with variable degree of atrophy. On this atrophic background, intestinal metaplasia sets in and finally dysplasia and carcinoma develop.<sup>18 19</sup> The possibly precancerous nature of chronic gastritis with severe atrophy is supported by the findings of Sipponen *et al.* They showed that in patients with chronic antral gastritis with severe atrophy, the relative risk of gastric carcinoma is increased 18 fold. The

TABLE I Characteristics of patients according to histological diagnosis (n=533)

Histological diagnosis	Patients (n)	Mean age (SD)	Mean no. (SD)	Patients (n) IM+ (% n)	Patients (n) HP+ (% n)
Normal	126	51.6 (17.7)	2.9 (1.8)	0 (0%)	2 (1.6%)
Erosion	26	60.0 (15.7)	3.2 (2.2)	1 (3.9%)	12 (46.1%)
Gastritis	298	58.4 (16.3)	3.6 (2.8)	88 (29.5%)	228 (76.5%)
Gastric ulcer	67	63.8 (15.8)	8.7 (3.8)	37 (55.2%)	47 (70.2%)
Gastric cancer					
Intestinal type	8	77.5 (6.5)	8.9 (2.5)	8 (100%)	0 (0%)
Diffuse type	8	57.9 (11)	12.4 (4.1)	1 (12.5%)	0 (0%)
	533			135 (25.3%)	289 (54.2%)

IM+ = Intestinal metaplasia positive.  
HP+ = *H pylori* positive.

TABLE II Prevalence of intestinal metaplasia, intestinal metaplasia subtypes and *H pylori* according to age (n=533)

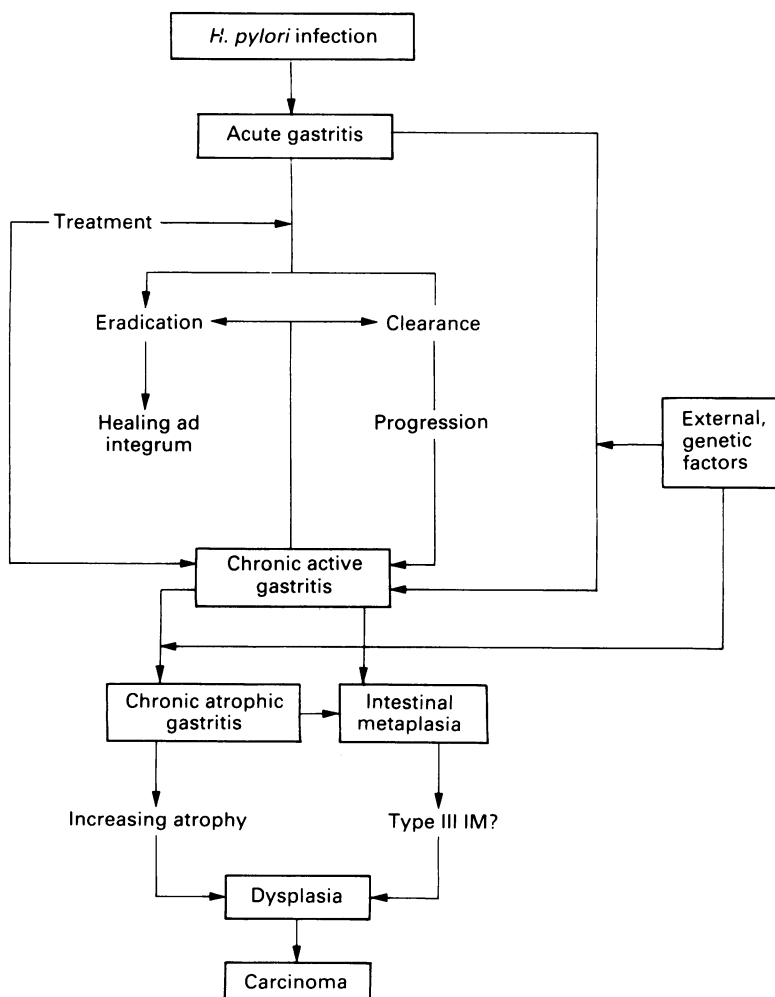
Age group (yr)	Patients (n)	HP+ pts (n) (% n)	IM+ pts (n) (% n)	Percentage in IM+ patients		
				Type I	Type II	Type III
<20	2	0 (0%)	0 (0%)	0%	0%	0%
20-29	34	12 (35.3%)	1 (2.9%)	100%	0%	0%
30-39	41	21 (51.2%)	3 (7.3%)	100%	66.6%	0%
40-49	86	43 (50%)	13 (15.1%)	100%	76.9%	7.7%
50-59	106	69 (65.1%)	25 (23.6%)	100%	76%	8%
60-69	114	66 (57.9%)	28 (24.6%)	92.8%	85.7%	14.3%
70-79	92	52 (56.5%)	38 (41.3%)	100%	81.6%	18.4%
≥80	58	26 (44.8%)	27 (46.6%)	100%	74.1%	22.2%
	533	289 (54.2%)	135 (25.3%)			

IM+ = Intestinal metaplasia positive.  
HP+ = *H pylori* positive.

cumulative cancer risk within 10 years of diagnosis was reported to be 8.7% for the age group 50–54 years.<sup>20</sup>

Numerous studies have emphasised the existence of an aetiopathogenetic relationship between intestinal metaplasia and intestinal type gastric carcinoma. Our finding that the majority of the patients with benign gastric ulcer were intestinal metaplasia positive is in agreement with the results reported by others.<sup>21,22</sup> These observations clearly limit the use of intestinal metaplasia in general as an indicator of possibly increased gastric cancer risk. It has been shown, however, that sulphomucin secreting incomplete intestinal metaplasia subtype, that is, type III intestinal metaplasia, is found significantly more often in the mucosa surrounding intestinal type gastric carcinoma than in the mucosa surrounding either diffuse type carcinoma or benign gastric ulcer.<sup>8–13,23</sup> This observation not only holds true for advanced carcinomas but for early carcinomas as well.<sup>24</sup> Additional evidence from other studies has led to the assumption that only type III intestinal metaplasia might be regarded as a marker of increased gastric cancer risk.<sup>25–27</sup> In this study, type III intestinal metaplasia, in contrast with type I and II, was found more often in moderate/severe intestinal metaplasia than in mild intestinal metaplasia. Moreover, the prevalence of this intestinal metaplasia subtype increased with age. Similar findings were reported by Sipponen *et al.*<sup>27</sup> These data suggest

Figure: Hypothetical pathogenesis of intestinal type gastric carcinoma.



that type III intestinal metaplasia might be the result of longstanding and persistent mucosal injury. Interestingly, in a six year follow up study of subtypes of intestinal metaplasia, type III was reported to be related to prolonged injury and chronicity, to delayed ulcer healing and frequent ulcer relapse.<sup>28</sup>

At present, there is still much debate whether or not *H. pylori* and intestinal metaplasia are related. In the classifications of chronic gastritis by Whitehead,<sup>29</sup> Cheli and Giacosa<sup>30</sup> and Wyatt and Dixon,<sup>31</sup> intestinal metaplasia is considered more or less a sequel to inflammation and part of a progressive process. This leaves room for the concept that intestinal metaplasia might be a result of *H. pylori* related gastritis. In contrast, Correa<sup>32,33</sup> and Yardley<sup>34,35</sup> propose that the finding of intestinal metaplasia in gastric biopsies indicate an aetiology for gastritis distinct from *H. pylori*. They suggest that intestinal metaplasia is the result of exogenous and/or dietary factors<sup>36,37</sup> other than *H. pylori* infection. Kekki *et al.*, however, showed in their longitudinal study that non-atrophic and non-metaplastic chronic gastritis can evolve into chronic atrophic gastritis with intestinal metaplasia.<sup>38</sup> In an earlier study we reported that intestinal metaplasia was found more often in *H. pylori* positive patients than in negative patients.<sup>14</sup> Therefore, because the possibility remains that *H. pylori* related chronic active gastritis may evolve into chronic gastritis with a variable degree of atrophy and intestinal metaplasia, we further investigated whether a different relationship could be found between *H. pylori* and the various intestinal metaplasia subtypes.

Type III intestinal metaplasia was found less often in *H. pylori* positive patients as compared with *H. pylori* negative patients. Although the overall degree of intestinal metaplasia in the latter two groups was not significantly different, type III intestinal metaplasia was found less often in *H. pylori* positive patients with moderate/severe intestinal metaplasia than in *H. pylori* negative patients with moderate/severe intestinal metaplasia. These results suggest that in type III intestinal metaplasia positive patients the gastric milieu has become increasingly inhospitable for *H. pylori*. It has been reported that this intestinal metaplasia subtype was found more often in the absence of appreciable inflammation and was rarely found in severe active gastritis.<sup>28</sup> We found that the prevalence of *H. pylori* decreases in patients aged  $\geq 60$  years, whereas the prevalence of intestinal metaplasia in general and subtype III in particular, increases with age. All these data further support the concept of increasing inhospitality of the gastric milieu for *H. pylori*, as intestinal metaplasia represents an inhospitable site for this microorganism.

We believe that at least some of the intestinal type carcinomas might be the late result of *H. pylori* infection as depicted in the Figure. The process of gastroduodenal carcinogenesis is multifactorial involving genetic factors and exogenous carcinogens. Recent studies have shown that the *H. pylori* serum antibody prevalence in populations with contrasting cancer risks is significantly higher in populations with a high cancer risk.<sup>39,40</sup> Because there are also populations with a high

prevalence of *H pylori* infection and a low gastric cancer risk,<sup>41</sup> it is clear that there must be other factors at work in the process of gastroduodenal carcinogenesis. It may well be that *H pylori* acts as a promoter in the latter process as suggested by Scott *et al*<sup>42</sup> and Correa.<sup>43</sup> In view of their reports, the treatment of *H pylori* related gastritis, leading to eradication of the microorganism, might assist in removing a potential risk factor in gastric cancer prone patients. The fact that all eight patients with intestinal type carcinoma in our study were *H pylori* negative, is not necessarily contradictory to their postulate. It could merely reflect the inhospitable milieu for *H pylori* in these patients. It is of interest that five of these eight patients were type III intestinal metaplasia positive.<sup>44</sup>

In conclusion we believe that this is the first study addressing the distribution of intestinal metaplasia subtypes in relation to *H pylori*. We suggest that the negative relationship between the presence of type III intestinal metaplasia and *H pylori* is caused by the altered gastric milieu in type III intestinal metaplasia positive patients. At present, through discovery of *H pylori* as the leading cause of gastric inflammation, much attention is directed to the long term consequences of gastric inflammation. We think that investigations should also monitor intestinal metaplasia and its subtypes in long term follow up studies with and without eradication of *H pylori*. This might lead to a better knowledge of the mechanisms involved in the development of intestinal type carcinoma. Because no real progress has been made in the early detection of gastric carcinoma, this would be of paramount importance.

- 1 Warren JR, Marshall BJ. Unidentified curved bacilli on gastric epithelium in active chronic gastritis. *Lancet* 1983; **i**: 1273-5.
- 2 Blaser MJ. Gastric Campylobacter-like organism, gastritis and peptic ulcer disease. *Gastroenterology* 1987; **93**: 371-83.
- 3 Rauws EAJ, Langenberg W, Houthoff HJ, Zanen HC, Tytgat GNJ. Campylobacter pyloridis-associated chronic active antral gastritis: a prospective study of its prevalence and the effects of anti-bacterial and anti-ulcer treatment. *Gastroenterology* 1988; **94**: 33-40.
- 4 Marshall BJ, Armstrong JA, McGeachie DB, Glancy RJ. Attempt to fulfil Koch's postulates for pyloric Campylobacter. *Med J Aust* 1985; **142**: 436-9.
- 5 Morris A, Nicholson G. Ingestion of Campylobacter pyloridis causes gastritis and raised fasting gastric pH. *Am J Gastroenterol* 1987; **82**: 192-9.
- 6 Dooley CP, McKenna D, Humphreys H, Bourke S, Keane CT, Sweeney E, *et al*. Histological gastritis in duodenal ulcer. *Am J Gastroenterol* 1988; **83**: 278-82.
- 7 Correa P. Precursors of gastric and esophageal cancer. *Cancer* 1982; **50**: 2554-65.
- 8 Huang CB, Xu J, Huang JF, Meng XY. Sulphomucin colonic type intestinal metaplasia and carcinoma in the stomach. *Cancer* 1986; **57**: 1370-5.
- 9 Jass JR, Filipe MI. A variant of intestinal metaplasia associated with gastric carcinoma: a histochemical study. *Histopathology* 1979; **3**: 191-9.
- 10 Jass JR. Role of intestinal metaplasia in the histogenesis of gastric carcinoma. *J Clin Pathol* 1980; **33**: 801-10.
- 11 Jass JR, Filipe MI. The mucin profiles of normal gastric mucosa, intestinal metaplasia and its variants and gastric carcinoma. *Histochem J* 1981; **13**: 931-9.
- 12 Segura DI, Montero C. Histochemical characterization of different types of intestinal metaplasia in gastric mucosa. *Cancer* 1983; **52**: 498-503.
- 13 Heilmann KL, Hopker WW. Loss of differentiation in intestinal metaplasia in cancerous stomachs. A comparative morphologic study. *Pathol Res Pract* 1979; **164**: 249-58.
- 14 Craanen ME, Dekker W, Blok P, Ferwerda J, Tytgat GNJ. Intestinal metaplasia and Helicobacter pylori: an endoscopic-biopsied study of the gastric antrum. *Gut* 1992; **33**: 16-20.
- 15 Mowry RW. The special value of methods that color both acidic and vicinal hydroxyl groups in the histochemical study of mucins: with revised directions for the colloidal iron stain, the use of alcian blue 8GX and their combinations with the PAS reaction. *Ann NY Acad Sci* 1963; **106**: 402-23.
- 16 Spicer SS. Diamine methods for differentiating mucosubstances histochemically. *J Histochem Cytochem* 1965; **13**: 211-34.
- 17 Filipe MI. Histochemistry of intestinal mucins. In: Whitehead R, ed. *Gastrointestinal and oesophageal pathology*. 1st ed, Edinburgh: Churchill Livingstone, 1989: 71.
- 18 Correa P, Cuello C, Duque E, Burbano LC, Garcia FC, Bolanos O, *et al*. Gastric cancer in Columbia. III. Natural history of precursor lesions. *J Natl Cancer Inst* 1976; **57**: 1027-35.
- 19 Correa P. A human model of gastric carcinogenesis. *Cancer Res* 1988; **48**: 1319-26.
- 20 Sipponen P, Kekki M, Haapakoski J, Ihamakki T, Siurala M. Gastric cancer risk in chronic atrophic gastritis: statistical calculations of cross sectional data. *Int J Cancer* 1985; **35**: 173-7.
- 21 Stemmermann GN, Hayashi T. Intestinal metaplasia of the gastric mucosa: a gross and microscopic study of its distribution in various disease states. *J Natl Cancer Inst* 1968; **41**: 627-34.
- 22 Meister H, Holubarsch CH, Haferkamp O, Schlag P. Gastritis, intestinal metaplasia and dysplasia versus benign ulcer in stomach and duodenum and gastric carcinoma: A histopathological study. *Pathol Res Pract* 1979; **164**: 256-69.
- 23 Filipe MI, Potet F, Bogomoletz WV, Dawson PA, Fabiani B, Chauveinc P, *et al*. Incomplete sulphomucin-secreting intestinal metaplasia for gastric cancer. Preliminary data from a prospective study from three centres. *Gut* 1985; **26**: 1319-26.
- 24 Hirota T, Okada T, Itabashi M, Yoshida H, Matsukura N, Kitaoka H, *et al*. Significance of intestinal metaplasia as a precancerous condition of the stomach. In: Ming SC, ed. *Precursors of gastric cancer*. New York: Praeger Publications, 1984: 179-93.
- 25 Jass JR, Filipe MI. Sulphomucins and precancerous lesions of the human stomach. *Histopathology* 1980; **4**: 271-9.
- 26 Day DW, Morson BC. Gastric cancer. In: Anthony PP, Woolf N, eds. *Recent advances in histopathology*. Edinburgh: Churchill Livingstone, 1978; **10**: 159-78.
- 27 Sipponen P, Seppala K, Varis K, Hjelt L, Ihamakki T, Kekki M, *et al*. Intestinal metaplasia with colonic-type sulphomucins in the gastric mucosa; its association with gastric carcinoma. *Acta Pathol Microbiol Scand* 1980; **88**: 217-24.
- 28 Silva S, Filipe MI, Pinho A. Variants of intestinal metaplasia in the evolution of chronic atrophic gastritis and gastric ulcer. A follow up study. *Gut* 1990; **31**: 1097-105.
- 29 Whitehead R, Truelove SC, Gear MWL. The histological diagnosis of chronic gastritis in fiberoptic gastroscopy biopsy specimens. *J Clin Pathol* 1972; **25**: 1-11.
- 30 Cheli R, Giacosa A. Chronic atrophic gastritis and gastric mucosal atrophy - one and the same. *Gastrointest Endosc* 1983; **29**: 23-5.
- 31 Wyatt JL, Dixon MF. Chronic gastritis - a pathogenetic approach. *J Pathol* 1988; **154**: 113-24.
- 32 Correa P. The epidemiology and pathogenesis of chronic gastritis: three etiologic entities. *Front Gastrointest Res* 1980; **6**: 98-108.
- 33 Correa P. Chronic gastritis: A clinico-pathological classification. *Am J Gastroenterol* 1988; **83**: 504-9.
- 34 Paull G, Yardley JM. Pathology of C. pylori-associated gastric and esophageal lesions. In: Blaser MJ, ed. *Campylobacter pylori in gastritis and peptic ulcer disease*. New York: Igaku-Shoin, 1989: 73-97.
- 35 Yardley JH. Pathology of chronic gastritis and duodenitis. In: Goldman H, Appelman HD, eds. *Gastrointestinal pathology*. Baltimore: Williams and Wilkins, 1990: 69-143.
- 36 Nomura A, Yamakawa H, Ishidate T, Kamiyama S, Masuda H, Stemmermann GN, *et al*. Intestinal metaplasia in Japan: Association with diet. *J Natl Cancer Inst* 1982; **68**: 401-5.
- 37 Fontham E, Zavala D, Correa P, Rodriguez E, Hunter F, Haenszel W, *et al*. Diet and chronic atrophic gastritis: A case-control study. *J Natl Cancer Inst* 1986; **76**: 621-7.
- 38 Kekki M, Siurala M, Varis K, Sipponen P, Sistonen P, Nevanlinna RH. Classification principles and genetics of chronic gastritis. *Scand J Gastroenterol* 1987; **22** (suppl 141): 1-28.
- 39 Correa P, Fox J, Fontham E, Ruiz B, Lin Y, Zavala D, *et al*. Helicobacter pylori and gastric carcinoma. *Cancer* 1990; **66**: 2569-74.
- 40 Sitas F, Forman D, Yarnell JWG, Burr ML, Elwood PC, Pedley S, *et al*. Helicobacter pylori infection rates in relation to age and social class in a population of Welsh men. *Gut* 1991; **32**: 25-8.
- 41 Olive C, Michault A, Brassens-Rabbe MP, Megraud F. Seroprevalence of Campylobacter pylori in Reunion Island. *Klin Wochenschr* 1989; **67**: 52. [Abstract].
- 42 Scott N, Lansdown M, Diamant R, Rathbone B, Murday V, Wyatt JI, *et al*. Helicobacter gastritis and intestinal metaplasia in a gastric cancer family. (Letter) *Lancet* 1990; **335**: 728.
- 43 Correa P, Ruiz B. Campylobacter pylori and gastric cancer. In: Rathbone BJ, Heatley RV, eds. *Campylobacter pylori and gastroduodenal disease*. Oxford: Blackwell Scientific, 1989: 139-45.
- 44 Craanen ME, Blok P, Dekker W, Ferwerda J, Tytgat GNJ. Prevalence of subtypes of intestinal metaplasia in gastric antral mucosa. *Dig Dis Sci* 1991; **36**: 1529-36.