

# Assessment of proliferation of squamous, Barrett's and gastric mucosa in patients with columnar lined Barrett's oesophagus

S Y Iftikhar, R J C Steele, S Watson, P D James, K Dilks, J D Hardcastle

## Abstract

There is no satisfactory biomarker yet available for predicting the likelihood of pre-malignant changes or carcinoma developing in Barrett's or columnar lined oesophagus. In this study we have evaluated the proliferation of squamous epithelium, columnar epithelium from columnar lined oesophagus and gastric columnar epithelium from 23 Barrett's patients using positive immunoreactivity with the mouse monoclonal antibody Ki67 (which recognises an antigen associated with proliferative cells) with a view to using this parameter as a biomarker. Squamous epithelium had significantly higher Ki67 immunostaining as compared with columnar epithelium from columnar lined oesophagus (when examining the tissue with greater than 15% cells staining positive for Ki67, Fisher's exact test  $p=0.004$ ) but there was no difference found between the epithelium from the columnar lined oesophagus and gastric columnar epithelium. There was no correlation between histological inflammation and Ki67 immunoreactivity of Barrett's mucosa, and the Ki67 immunostaining of two patients with dysplasia was no different from the rest of the group. There was, however, a significant correlation between the Ki67 immunoreactivity of columnar epithelium from columnar lined oesophagus and columnar epithelium from the stomach (correlation coefficient=0.44,  $p=0.03$ ) suggesting that epithelium from columnar lined oesophagus behaves in a similar fashion to gastric epithelium.

Cell renewal in intestinal epithelium is an orderly sequential process proceeding from proliferation of cells in the basal layer through maturation of the daughter cells to formation of the epithelial cells lining the intestinal mucosa. This pattern is altered in pathological states, which can be characterised by an increased intestinal cell turnover rate.<sup>1,2</sup> For example, colonic epithelium in ulcerative colitis is characterised by an increase in the proportion of epithelial cells synthesising DNA,<sup>2,3</sup> and upward expansion of the proliferative zone.<sup>1-3</sup>

Gastrooesophageal refluxate causes cell damage in the oesophageal mucosa and the consequent reparative response also results in just such proliferative alterations. In some patients with chronic gastrooesophageal reflux, metaplastic change in the oesophageal mucosa also occurs and squamous is replaced by columnar epithelium<sup>4,5</sup> resulting in 'Barrett's or columnar lined oesophagus'. This columnar

epithelium has the potential for malignant change,<sup>6,7</sup> but although attempts have been made to detect such transformation at a premalignant stage, histological dysplasia remains the only reliable index to date.<sup>8</sup> It is of interest, however, that in Barrett's epithelium, dysplasia is sometimes associated with aneuploidy, and occasionally aneuploidy is seen in the absence of dysplasia. It has therefore been suggested that ploidy status may be a marker for malignant changes which precedes the development of histological abnormalities.<sup>9</sup>

The proliferative activity of cells has been evaluated in several pathological conditions,<sup>10-12</sup> and thymidine labelling index,<sup>13</sup> bromodeoxyuridine *in situ* labelling,<sup>14-16</sup> DNA flow cytometry,<sup>17</sup> and Ki67 immunohistochemistry have been used to quantify the mitotic index in malignant<sup>11,18,19</sup> and benign disease.<sup>20-22</sup> This approach has not, however, been evaluated in columnar lined oesophagus.

Ki67 is a mouse monoclonal antibody that recognises a nuclear antigen which is expressed in all phases of the cell cycle except G0 (the quiescent phase), and is therefore associated with cell proliferation.<sup>10,23</sup> The existence of such an antigen was originally suggested by Stein and colleagues<sup>24</sup> and subsequently Ki67 was obtained in studies aimed at the production of monoclonal antibodies to nuclear antigens specific to Sternberg-Reed cells in Hodgkins disease.<sup>25</sup> Proliferative activity (Cell kinetics and mitotic index) gives reliable information on stem cell proliferation, and hence is used widely in the assessment of tumour response to various treatments. It is also particularly important as a prognostic index in tumours such as lymphoma, in which chemotherapy and radiotherapy are the main modalities of treatment.<sup>26</sup> Proliferative index has also been evaluated in other malignancies.<sup>25-28</sup>

The pattern of epithelial proliferation in Barrett's epithelium is similar to that in other gastrointestinal mucosa,<sup>29</sup> but, Herbst and his colleagues<sup>30</sup> have shown that incorporation of thymidine in adenocarcinoma associated with columnar lined oesophagus is similar to that in adjacent non-neoplastic columnar lined oesophagus, implying that surface labelling of non-neoplastic columnar lined oesophagus may be indicative of future development of carcinoma. It is therefore possible that proliferative index as measured by Ki67 immunoreactivity may be of value in predicting malignant change.

In this study Ki67 immunoreactivity in columnar epithelium of Barrett's oesophagus, has been compared with that in normal oesophageal squamous and gastric epithelium from the

Department of Surgery,  
University Hospital,  
Nottingham  
S Y Iftikhar  
R J C Steele  
J D Hardcastle

Cancer Research  
Campaign, University of  
Nottingham  
S Watson  
K Dilks

Department of  
Pathology, University  
Hospital, Nottingham  
P D James

Correspondence to:  
Mr S Y Iftikhar, Department  
of Surgery, University  
Hospital, Nottingham  
NG7 2UH.

Accepted for publication  
16 September 1991

same patients. In addition, the proliferative immunoreactivity of the Barrett's epithelium has been compared with ploidy status as assessed by DNA image cytometry in order to evaluate its role as a possible biomarker for premalignant change.

## Methods

### PATIENTS

Twenty three patients with a median age of 57.5 years (range 42–76) and with a histological diagnosis of Barrett's oesophagus were entered into this study. The mean length of columnar lined oesophagus in this group was 7.0 (2.5) cm.

### MEASUREMENT OF CELL PROLIFERATION WITH Ki67 MONOCLONAL ANTIBODY

Endoscopic biopsies of columnar epithelium from columnar lined oesophagus, gastric epithelium, and normal squamous oesophageal mucosa were taken from each patient. Multiple biopsies from different areas of each epithelium were taken and representative samples were processed for routine histology. The biopsy material for study was disaggregated enzymatically with collagenase to achieve a single cell suspension.<sup>31</sup> The cell suspension was then fixed (10 minutes, 1% paraformaldehyde 4°C, followed by 10 minutes 70% ethanol, at 4°C). Dissaggregation was checked microscopically as single cells are required for the flow cytometric assessment, and few cell clumps were present.

One hundred microlitres of the mouse monoclonal antibody, Ki67 (Dakopatts, Bucks, UK) at 1:10 dilution was added to  $2 \times 10^5$  cells and incubated for five minutes at 30°C followed by 55 minutes at room temperature (22°C). The cells were washed and antibody binding was detected with an antimouse fluorescein isothiocyanate conjugate (Dakopatts) used at a 1:80 dilution (0.5 ml/ $2 \times 10^5$  cells) with an incubation period of 30 minutes at room temperature. Cells were analysed on a fluorescence activated cell sorter<sup>32</sup> and the mean linear fluorescence/cell and percentage positive cells/population were analysed. Normal mouse monoclonal (irrelevant) antibody was used as a primary substitution antibody control, and fluorescence achieved with this control was subtracted from that achieved with Ki67 stained cells. In addition, the primary antibody was omitted to determine levels of endogenous fluorescence which was generally negligible.

The size of the gate was selected for epithelial cell populations stained with an anticytokeratin monoclonal antibody and gating set so that all low fluorescence cells were excluded but high

fluorescence cells included. Only cells staining red with propidium iodine were analysed, thus red blood cells and effete cells were excluded from the analysis. Further gating was achieved at the computer evaluation and this allowed exclusion of lymphocytes and cell clumps, so that the only potential contaminating cell type was stromal (5% of cell population in gastric specimens). 30 000 cells were counted per analysis and duplicate samples from each biopsy were analysed.

### DNA IMAGE CYTOMETRY

Nuclear DNA analysis was performed using a Seescan 'Solitaire Plus' image processing system which has integrated hardware and software for rapid interactive nuclear DNA measurement. Slides were visualised by a Leitz Dialux 20 E B microscope (modified for stable illumination) fitted with a black and white charge coupled device (linear resolution) calibrated camera inputted into the computer. Calibration for DNA analysis was achieved using known standards (chick erythrocyte cells) and biopsies with known DNA values from a previous study.<sup>9</sup>

An internal diploid standard (2c) for each biopsy was produced by counting at least 20 lymphocytes (coefficient of variation range 5 to 15, mean 9.5). The DNA content of at least 50 epithelial cells per biopsy was determined, and nuclei were selected preferentially if they appeared morphologically large or atypical. Nuclei could be measured individually and touching nuclei in close proximity could be separated and measured by outlining the nuclei with the aid of a 'mouse'. At least two levelled sections from each biopsy were examined. Aneuploid cells were identified where the DNA content exceeded 5c and abnormal measurements were repeated at least three times and confirmed blind by two independent observers. The practical protocol in this study was otherwise identical to that previously published.<sup>9</sup>

## Results

### HISTOLOGY

Fourteen of the 23 sets of biopsies from the Barrett's epithelium had specialised epithelium, 12 had fundic and 21 had junctional epithelium whereas six had all three types of epithelium. Four of the 23 subjects had histological evidence of inflammation in the columnar epithelium and two were diagnosed as having low grade dysplasia. In addition the squamous and columnar nature of each upper oesophageal and gastric biopsy was confirmed by histology.

### Ki67 IMMUNOSTAINING

The mean % cells staining positive for Ki67 in squamous epithelium was 15.14 (12.70) with a median of 11.60 (range 0–48.30), whereas mean % cells staining in oesophageal columnar and gastric epithelium was 8.92 (9.43) and 11.90 (12.60) respectively. The median values for columnar and gastric epithelium were 6.20 (range 0–35.60) and 7.40 (0–43.20) respectively

TABLE I *Ki67 immunoreactivity of squamous, Barrett's and gastric mucosa in columnar lined oesophagus patients*

|                     | Squamous epithelium | Barrett's epithelium | Gastric epithelium |
|---------------------|---------------------|----------------------|--------------------|
| Mean                | 15.14               | 8.92                 | 11.90              |
| +SD                 | 12.70               | 9.43                 | 12.60              |
| Range               | 0–48.30             | 0–35.60              | 0–43.20            |
| Median              | 11.60               | 6.20                 | 7.40               |
| Mann Whitney U-test | NS                  | NS                   |                    |

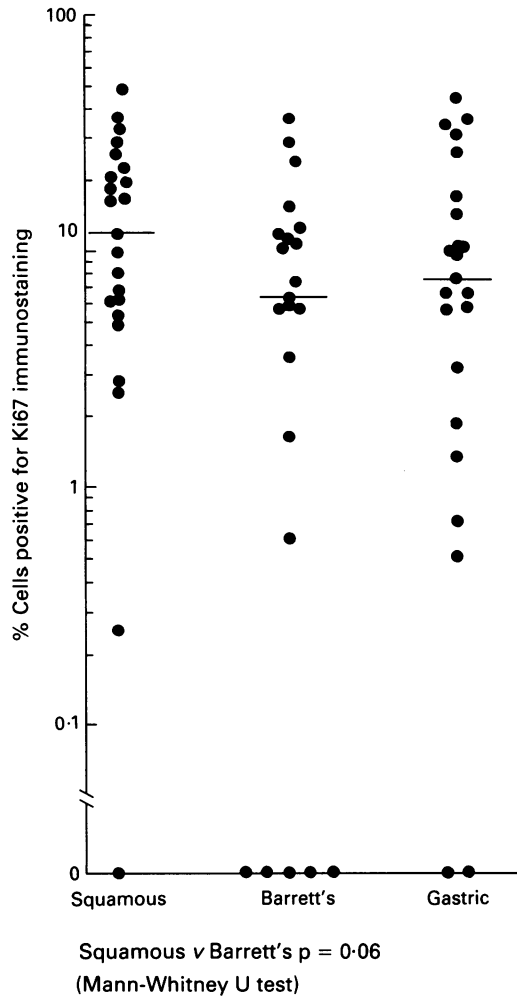


Figure 1: Comparison of Ki67 immunostaining of squamous, Barrett's and gastric columnar epithelium in patients with Barrett's oesophagus.

TABLE II Ki67 immunoreactivity in squamous, Barrett's and gastric mucosa

| Cells staining positive for Ki67 (%) | Squamous mucosa (n=23) | Barrett's mucosa (n=23) | Gastric mucosa (n=23) |
|--------------------------------------|------------------------|-------------------------|-----------------------|
| 1 <5                                 | 5                      | 8                       | 7                     |
| 2 5-15                               | 7                      | 13                      | 10                    |
| 3 16-25                              | 6                      | 0                       | 2                     |
| 4 26-50                              | 5                      | 2                       | 4                     |

Fisher exact test.  
Squamous v Barrett's. p=0.004 Df=1  
(3 & 4) (3 & 4)

(Table I, individual results shown in Figure 1). When compared using the Mann Whitney U-test there was no significant difference found between % cells staining positive for Ki67 in squamous epithelium, columnar epithelium from Barrett's oesophagus and gastric epithelium. When the percentage of cells staining positive for Ki67 monoclonal antibody was subdivided into four groups, however – that is, <5% cells staining positive, 5–15% cells staining positive, 16–25% cells staining positive and 26–50% staining positive, a significantly higher number of squamous epithelia displayed more than 15% of cells staining as compared to Barrett's epithelium (Fisher's Exact test p=0.004, df=1) (Table II). No statistical difference was found when squamous and gastric epithelium or Barrett's and gastric epithelium were compared with each other. There was no correlation found between the proliferation (as assessed by Ki67 immunoreactivity) of squamous and Barrett's epithelium. A statistically significant positive correlation, however, between Barrett's and gastric epithelium was found (Fig 2).

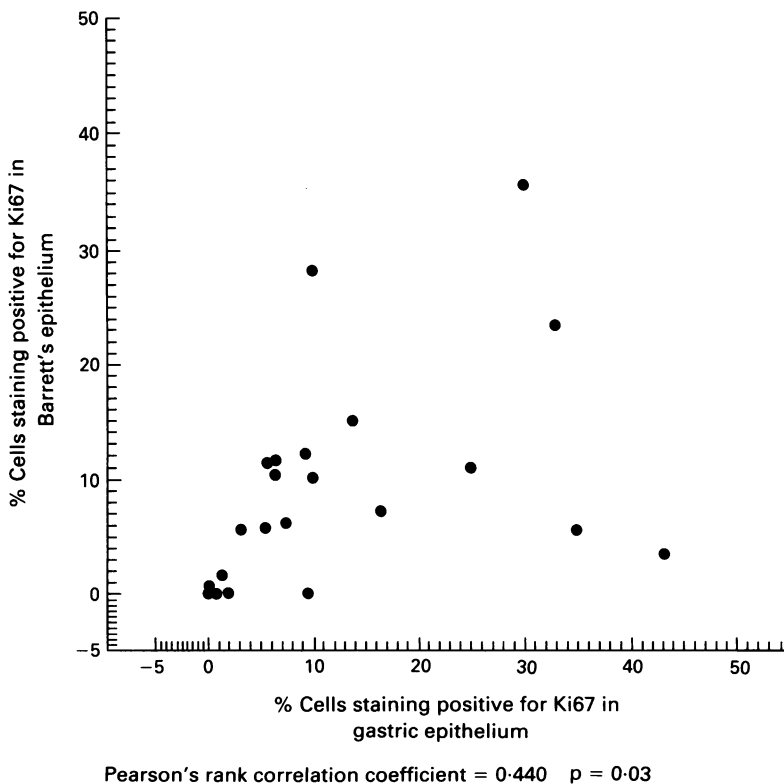


Figure 2: Correlation between Ki67 immunostaining of Barrett's and gastric epithelium in patients with Barrett's oesophagus.

DNA IMAGE CYTOMETRY

Twenty one sets of biopsies of histologically benign columnar epithelium from columnar lined oesophagus of 21 patients and one set of biopsy from a dysplastic columnar epithelium from columnar lined oesophagus showed a normal DNA profile. One patient with dysplasia, however, was found to have aneuploid cells.

CORRELATION OF PLOIDY AND INFLAMMATION WITH Ki67 IMMUNOREACTIVITY

The one patient with aneuploid cells had a Ki67 immunoreactivity value of 5.6%. This was not markedly different to the Ki67 immunostaining of its respective squamous and gastric epithelium. Four patients who had histological evidence of inflammation in the columnar lined oesophagus did not have raised Ki67 immunostaining of their columnar epithelium as compared with their squamous or gastric epithelium.

Discussion

Several attempts have been made to identify a biomarker which may identify a subgroup of patients with Barrett's oesophagus who are likely to develop carcinoma. Sulphomucin secretion has been investigated but has been found to be a

common feature of columnar lined oesophagus and not sufficiently discriminatory to detect a subgroup of patients at high risk of malignant change.<sup>33</sup> Similarly, differences in ornithine decarboxylase activity in non-dysplastic and dysplastic epithelium of columnar lined oesophagus has not been observed.<sup>34</sup>

To date, several methods for the assessment of cellular proliferation have been used in an attempt to quantify various stages of the cell cycle and to relate these to the biological behaviour of the cell.<sup>35</sup> In the present study, the Ki67 mouse monoclonal antibody has been used to determine the level of proliferation of squamous, columnar and gastric epithelium from patients with Barrett's oesophagus. The squamous epithelium in these patients had a higher level of proliferation than the Barrett's epithelium, a finding in contrast with that of Herbst and his colleagues<sup>30</sup> who showed by the indirect method of in vitro thymidine labelling that cell turnover was much slower in the squamous epithelium as compared with Barrett's epithelium of patients with columnar lined oesophagus.

No previous attempts have been made to compare the proliferation of Barrett's epithelium and gastric epithelium obtained from the same patients. In this study no difference between the proliferation of Barrett's epithelium and gastric epithelium was found. One possible explanation of higher Ki67 immunostaining in squamous mucosa in these patients may be that this epithelium bears the brunt of gastrooesophageal reflux whereas Barrett's epithelium is more akin to gastric epithelium and can withstand the harmful effect of gastric juice. The Ki67 staining of normal squamous epithelium has not been studied, however, and although there is evidence that in ulcerative colitis subjects there is abnormal cell renewal<sup>1</sup> and higher proliferation in inflamed mucosa, the inflamed Barrett's mucosa in this study did not exhibit enhanced levels of Ki67 immunostaining.

No correlation between the Ki67 immunostaining of the squamous and columnar epithelium from columnar lined oesophagus subjects was found, but a significant positive correlation was found between the Barrett's epithelium and gastric epithelium. This is in concordance with the findings of Herbst and his colleagues<sup>30</sup> and Pellish and his colleagues<sup>29</sup> who also found that cell turnover of oesophageal columnar epithelium was similar to other columnar epithelium of the gastrointestinal tract. This significant correlation of the proliferative indices of the oesophageal and gastric columnar epithelium, however, does raise the question as to what extent patients with Barrett's oesophagus are prone to gastric dysplasia and adenocarcinoma. No such evaluation has yet been possible but studies are required to answer this question.

In this study it has been shown that squamous epithelium has a higher proliferative index than Barrett's epithelium in columnar lined oesophagus patients and that oesophageal columnar epithelium behaves in similar fashion to gastric columnar epithelium. Owing to small numbers of dysplastic or aneuploid biopsies, however, it has not been possible in this study to show that

Ki67 immunostaining is related to these histological or cytometric features. In addition any value that it may have as a biomarker or in defining a subgroup of patients who may be prone to future development of dysplasia or adenocarcinoma in their columnar lined oesophagus can only be investigated by prolonged follow up.

- Bleiberg H, Mainguet P, Galand P, Cheetien J, Dupont-Mairesse N, *et al.* Cell renewal in the human rectum 'in vitro' autoradiographic study on active ulcerative colitis. *Gastroenterology* 1970; **58**: 851-5.
- Eastwood LG, Trier JS. Epithelial cell renewal in cultured rectal biopsies in ulcerative colitis. *Gastroenterology* 1973; **64**: 383-90.
- Serafini EP, Kirk AP, Chambers TJ. Rate and pattern of epithelial cell proliferation in ulcerative colitis. *Gut* 1981; **22**: 648.
- Gillen P, Keeling P, Byrne PJ, West AB, Hennessy TPJ. Experimental columnar metaplasia in the canine oesophagus. *Br J Surg* 1988; **75**: 113-5.
- Monnier P, Fontcollet C, Savary M, Ollyo JB. Barrett's oesophagus or columnar epithelium of the lower oesophagus. *Clin Gastroenterol* 1987; **1**: 769-89.
- Cameron AJ, Ott BJ, Payne WS. The incidence of adenocarcinoma in a columnar lined Barrett's oesophagus. *N Engl J Med* 1985; **313**: 857-9.
- Spechler SJ, Robbins AH, Rubins HA, Vincent ME, Heeren T, Doos WG, *et al.* Adenocarcinoma and Barrett's oesophagus: an over-rated risk. *Gastroenterology* 1984; **87**: 927-33.
- Reid BJ, Weinstein WM, Lewin KJ, Haggitt RC, Van Deventer G, Den Besten L, *et al.* Endoscopic biopsy can detect high grade dysplasia or early adenocarcinoma in Barrett's oesophagus without grossly recognisable neoplastic lesions. *Gastroenterology* 1988; **94**: 81-90.
- James PD, Atkinson MA. Value of DNA image cytometry in the prediction of malignant change in Barrett's oesophagus. *Gut* 1989; **30**: 899-905.
- Gerdes J, Lemke H, Baisch H, Waeker HH, Schwab V, Stein H. Cell cycle analysis of a cell proliferation associated human nuclear antigen defined by the monoclonal antibody Ki67. *J Immunol* 1984; **133**: 1710-5.
- Gerdes J, Lelle RJ, Pickartz H, Heidenreich Schwarting R, Kurtsiefer L, *et al.* Growth fraction in breast cancers determined in situ with monoclonal antibody Ki67. *J Clin Pathol* 1986; **39**: 977-80.
- Gatter KC, Dunnill MS, Gerdes J, Stein H, Mason DY. New approach to assessing lung tumours in man. *J Clin Pathol* 1986; **39**: 590-3.
- Mayer JS, Connor RE. In vitro labelling of tissues with tritiated thymidine for autoradiographic detection of S-phase nuclei. *Stain Technol* 1977; **52**: 185.
- Gratzner HG. Monoclonal antibody to 5-bromo and 5-iododeoxyuridine: a new reagent for detection of DNA replication. *Science* 1983; **218**: 474.
- Dolbear FA, Gratzner HG, Pallavicini MG, Gray W. Flow cytometric measurement of total DNA content and incorporated Bromodeoxyuridine. *Proc Natl Acad Sci* 1983; **80**: 5573.
- Wilson GD, McNally NJ, Dische S, Saunders MJ, Des Rochers C, Lewis AA, *et al.* Measurement of cell kinetics in human tumours in vivo using bromodeoxyuridine incorporation and flow cytometry. *Br J Cancer* 1988; **58**: 423-31.
- Walker RA, Camplejohn RS. Comparison of monoclonal antibody Ki67 reactivity with grade and DNA flowcytometry of breast cancer. *Br J Cancer* 1988; **57**: 281-3.
- Barnard NJ, Hall PA, Lemoine NR, Kadar P. Proliferative index in breast carcinoma determined in situ by Ki67 immunostaining and its relationship to clinical and pathological variables. *J Pathol* 1987; **152**: 287-95.
- McGurrin JF, Doria MI, Dawson PJ, Karrison T, Stein HO, Franklin WA. Assessment of tumour kinetics by immunohistochemistry in carcinoma of the breast. *Cancer* 1987; **59**: 1744-50.
- Hall PA, Richards MA, Gregory WM, D'Ardenne AJ, Lister TA, Stansfeld AG. The prognostic value of Ki67 immunostaining in non-Hodgkin's lymphoma. *J Pathol* 1988; **154**: 223-36.
- Franklin WA, McDonald GB, Stein HO, Galler KC, Jewell DP, Mason DY, *et al.* Immunohistological demonstration of abnormal crypt cell kinetics in ulcerative colitis. *Human Pathol* 1985; **16**: 1129-32.
- Lelle RJ, Heidenreich W, Stanch G, Wecke I. Determination of growth fraction in benign breast disease (BBD) with monoclonal antibody. *J Cancer Res Clin Oncol* 1987; **113**: 73-7.
- Gerdes J, Schwab V, Lemke H, Stein H. Production of a mouse monoclonal antibody reactive with a human nuclear antigen associated with cell proliferation. *Int J Cancer* 1983; **31**: 13-20.
- Stein H, Gerdes J, Kirchner H, Diehl V, Schaadt M, Bonk A, *et al.* Immunohistological analysis of Hodgkin's and Steinberg-Reed cells: Detection of a new antigen and evidence of selective IgG uptake in the absence of B-cell, T-cell and histocytic markers. *J Cancer Res Clin Oncol* 1981; **101**: 125-34.
- Lieb LM, Lisco H. In vitro uptake of tritiated thymidine by carcinoma of the human colon. *Cancer Res* 1966; **26**: 733-40.
- Bleiberg H, Galand P. In vivo autoradiographic determination

- of cell kinetic parameters in adenocarcinomas and adjacent healthy mucosa of the human colon and rectum. *Cancer Res* 1976; **36**: 325-8.
- 27 Leshner S, Schiffer LM, Phanse M. Human colonic tumour kinetics. Potential for therapy. *Cancer* 1977; **40**: 2706-9.
- 28 Meyer JS, Prioleau PG. S-phase fractions of colo-rectal carcinomas related to pathologic and clinical features. *Cancer* 1981; **48**: 1221-8.
- 29 Pellish LJ, Hermos JA, Eastwood GL. Cell proliferation in three types of Barrett's epithelium. *Gut* 1980; **21**: 26-31.
- 30 Herbst JJ, Berenson MM, McCloskey DW, Wiser WC. Cell proliferation in esophageal columnar epithelium (Barrett's esophagus). *Gastroenterology* 1978; **75**: 683-7.
- 31 Watson SA, Durrant LG, Crosbie JD, Morris DL. The in vitro growth response of primary human colorectal and gastric cells to gastrin. *Int J Cancer* 1989; **43**: 692-6.
- 32 Armitage NC, Robins RA, Evans DF, Turner DR, Baldwin RW, Hardcastle JD. The influence of tumour cell DNA abnormality on survival in colorectal cancer. *Br J Surg* 1985; **72**: 828-30.
- 33 Haggitt RC, Reid BJ, Rabinovitch PS, Rubin CE. Barrett's oesophagus. Correlation between mucin histochemistry, flow cytometry and histologic diagnosis for predicting increased cancer risk. *Am J Pathol* 1988; **131**: 53-61.
- 34 Garewal HS, Gerner EW, Sampliner RE, Roe D. Ornithine decarboxylase and polyamine levels in columnar upper gastrointestinal mucosa in patients with Barrett's oesophagus. *Cancer Res* 1988; **48**: 3288-91.
- 35 Quinn CM, Wright NA. The clinical assessment of proliferation and growth in human tumours: evaluation of methods and application as prognostic variables. *J Pathol* 1990; **160**: 93-102.