

# Immunocytochemical localisation of parietal cells and G cells in the developing human stomach

E J Kelly, M Lagopoulos, J N Primrose

## Abstract

Previous studies on the distribution of parietal cells and G cells in normal adult stomachs have shown that in about 20% of specimens parietal cells extended to the pylorus. This study aimed to examine the distribution of parietal cells and G cells in the body and antrum of the developing human stomach in relation to anatomical landmarks, using histological and immunocytochemical methods. In all 15 fetal stomachs examined, parietal cells extended to the pylorus and expressed intrinsic factor and hydrogen-potassium-ATPase activity from week 13 of gestation. By contrast, in only one of the five infant stomachs did parietal cells extend to the pylorus: this is identical to the distribution in the adult. G cells developed in the antrum from 18 weeks' gestation and their distribution did not differ between the fetal and infant stomachs. These findings indicate that parietal cells disappear from the antrum of the stomach in the third trimester of pregnancy, but this process fails to occur in approximately 20% of the population.

(Gut 1993; 34: 1057-1059)

The specialised cells of the stomach, including the parietal cell (responsible for gastric acid and intrinsic factor secretion) and the G cell (gastrin producing), have been the subject of considerable study in both normal subjects and in those with peptic ulcer disease. In adults there seem to be two anatomically distinct types of stomach. In the first type, parietal cells are found within the corpus and G cells within the antrum, with a transitional zone on the antrum-corpora boundary containing both cell types (80% of the population). In the second, parietal cells extend to the pylorus, but G cells are also present in the antrum (20% of the population). This type of stomach has been referred to as having an 'acid antrum'.<sup>1</sup> Both types of stomach are seen in patients with duodenal ulcer disease<sup>2,3</sup> and this is relevant to the surgical treatment of the condition since patients with acid antra may be inadequately treated by highly selective vagotomy.<sup>2</sup>

Surprisingly, the origin of these two distinct types of stomach is unknown. In this study we have mapped the location of parietal cells and G cells in the developing human stomach, using specific immunocytochemistry, in order to determine whether there are two distinct populations in the fetus or whether a change in distribution of parietal cells and G cells occurs during fetal and postnatal life.

## Methods

Fifteen fetal and five infant stomachs were

obtained from the University Departments of Pathology and Obstetrics and Gynaecology, St James's University Hospital, Leeds. The specimens resulted from therapeutic abortions, miscarriages, and cot deaths. The ages of the fetuses and babies are listed in Table I. The maturity of fetuses is given in weeks of gestation since the last menstrual period and was confirmed by antenatal ultrasound assessment and fetal foot length measurements. Infants who were studied after unexplained sudden infant death were all born at term and their ages are given as weeks of postnatal life.

The specimens were immersed in buffered formalin for a minimum of four days. The distal pylorus and the anatomical antrum-corpora boundary (indicated by the point where the nerve of Latarjet crossed the lesser curvature) were marked with indian ink on both sides of the specimens. Two adjacent strips containing mucosa from the corpus, antrum, and pylorus were then cut from the anterior and posterior aspects, resulting in four strips from each specimen. Sections, 8  $\mu$  thick, were stained using haematoxylin and eosin and the peroxidase anti-peroxidase technique of Sternberger.<sup>4</sup>

Intrinsic factor and hydrogen-potassium ATPase activity were mapped using murine monoclonal antibodies (Dr Smolka, University of South Carolina, Charleston, South Carolina, USA) and gastrin activity was mapped using a rabbit antiserum to human gastrin (Dako, High Wycombe). The second antibodies were raised in goat and swine respectively (Sigma, Poole) and complemented with rabbit and mouse peroxidase anti-peroxidase complexes (Sigma). The sections were stained with 3,3 diamino benzidine and counterstained with methyl green.

A negative control, in which the primary antibody was omitted, was performed for all sections. The sections stained for intrinsic factor and gastrin also had negative controls in which their antisera were incubated with their respective antigens (Sigma).

All sections were viewed under a Leitz Dialux 20 EB microscope using  $\times 50$  and  $\times 100$  objectives. The sections stained with haematoxylin and eosin and those stained for gastrin had the point at which the parietal cells stopped distally and the point at which the G cells stopped proximally marked on the surface of the slides.

As the stomachs varied greatly in size, data were normalised. This was done by using the pylorus and the anatomical antrum-corpora boundary as reference points. Histological findings were related to these anatomical landmarks. The density of both cell types within the antrum of each specimen was determined by calculating the number of each cell type per high power field. Ten measurements were made indepen-

Departments of Anatomy and Surgery, University of Leeds and St James's University Hospital, Leeds

E J Kelly  
M Lagopoulos  
J N Primrose

Correspondence to:  
Mr E J Kelly, Neonatal Unit,  
St James's University  
Hospital, Beckett Street,  
Leeds LS9 7TF.

Accepted for publication  
24 November 1992

The ages of the fetuses and babies from whom the specimens were taken

Age (wk)	No of specimens
<b>Gestational age:</b>	
13	1
15	1
18	2
19	4
20	3
21	2
24	1
26	1
<b>Postnatal age:</b>	
2	1
4	1
10	1
13	1
21	1

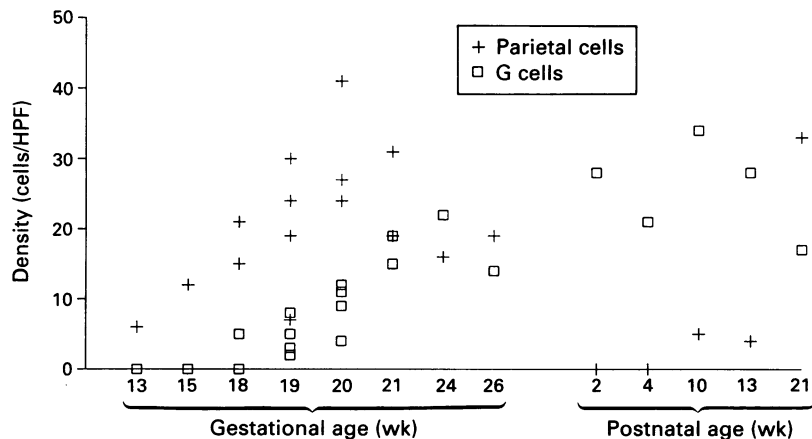


Figure 1: The density (cells per high power field (HPF)) of parietal cells and G cells in both fetal and infant stomachs.

dently by two observers on each specimen and the mean was calculated.

Statistical analysis of the data was performed using the Mann-Whitney U test for non-parametric data and Spearman's rank order correlation.

## Results

### PARIETAL CELLS

Parietal cells were detected in all stomachs on slides stained with haematoxylin and eosin, from 13 weeks of gestation to 21 postnatal weeks. There was a difference in the distribution of parietal cells between the fetal and infant specimens. In all of the fetal specimens parietal cells were noted to extend from the body, through the antrum, to the pyloric region of the stomach. In the five infant stomachs studied, however, extension of parietal cells into the antrum was much more limited. In one case parietal cells were found to extend to the pylorus, in two they extended through 20 and 22% of the antrum respectively, and in the remaining two infant specimens no parietal cells were found in the antrum. There was great diversity in the density of parietal cells between specimens of different maturities (Fig 1). Intrinsic factor and hydrogen-potassium ATPase activity were found in all specimens, including those of 13 and 15 weeks' gestation. The location of this activity corresponded precisely with the location of parietal cells as determined by haematoxylin and eosin staining (Fig 2).

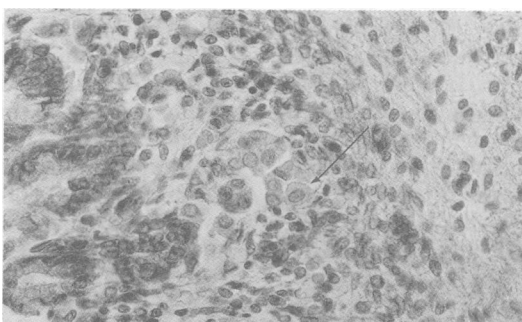


Figure 2: Haematoxylin and eosin stained specimen from a 15 week fetus (original magnification  $\times 500$ ). A typical parietal cell is indicated (arrow).

### G CELLS

G cells could not be detected in the fetuses of 13 and 15 weeks' gestation. By contrast, specimens from 18 gestational weeks showed gastrin activity (Fig 3), although at this stage cells were sparse. The number of G cells then increased appreciably until 24 weeks of gestation (Fig 1). At all maturities G cells were limited, to the anatomical antrum, and their distribution within the antrum did not differ between the fetal and infant specimens ( $p=0.42$ ).

Regression analysis of the density of G cells and parietal cells showed that there was a significant negative correlation between G cells and parietal cells,  $\rho = -0.52$  ( $p=0.04$ ).

None of the negative controls in which the primary antibody was omitted showed any staining after the application of 3,3 diamino benzidine. This was also true when gastrin and intrinsic factor were incubated together with their respective antibodies.

## Discussion

This study shows that parietal cells, with their specialised functions of acid and intrinsic factor secretion, are present from 13 weeks of gestation, and at this stage these cells occupy the whole stomach. Our results, therefore, agree with those of previous investigators who have noted that parietal cells are present in fetal stomachs from 11 gestational weeks' as differentiated epithelial cells which represent adult parietal cells in both structure and histochemical staining.<sup>6</sup> By contrast, the G cells are not detectable until 18 weeks of gestation and develop entirely within the anatomical antrum. Interestingly, this is the period in which parietal cells disappear from the same anatomical site in most subjects. Previous studies in the adult have shown that where the parietal cells retain their 'embryological' distribution, the G cells are relatively sparse.<sup>7</sup> It is interesting to speculate that in the fetus the G cells may, by a means yet to be identified, lead to the disappearance of parietal cells in their immediate vicinity. This is supported by our observation that the G cell and parietal cell densities were negatively correlated.

Hydrogen-potassium ATPase, necessary for the secretion of hydrogen ions, is present from the 13th gestational week in a functional form. The timing of active hydrogen ion secretion, however, remains unknown. Gastric acid has been shown during the first hour of life in both

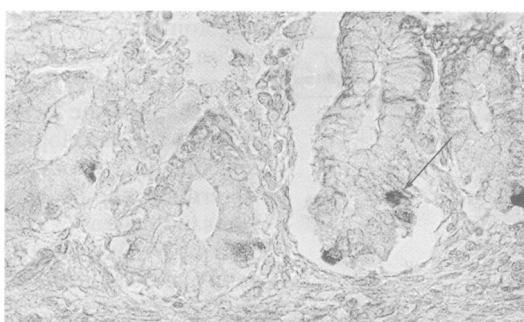


Figure 3: Immunocytochemical localisation of gastrin in a fetus of gestational age 18 weeks (original magnification  $\times 500$ ). The G cells are indicated (arrow).

term and preterm infants of more than 32 weeks gestation.<sup>8</sup> No data are available on acid secretion by more immature infants.

In 1971, using a radioimmunoassay technique on homogenised tissue, Schwarz and Weber<sup>9</sup> suggested that intrinsic factor may be present in fetal stomachs from at least 13 weeks of gestation. We have shown, using immunohistochemistry, that intrinsic factor is present in parietal cells from 13 weeks of gestation. This does not merely indicate that the framework for intrinsic factor production is in place but that it is being produced actively by the parietal cell from the end of the first trimester.

G cells have been found in the duodenum from 10 gestational weeks and in much lower numbers in the antrum from 19 gestational weeks.<sup>10</sup> This agrees with our localisation of gastrin producing cells from 18 gestational weeks. The role of peptide hormones produced by endocrine cells in fetal development is incompletely understood at present in both experimental animals and humans. It seems probable, however, that since factors such as gastrin are being produced by the developing stomach from about 18 gestational weeks,<sup>11</sup> they may have a role in the development of the gastrointestinal tract. This is consistent with observations of Schulkes *et al* on fetal sheep in which gastrin has been detected in the gastric juices at a time when the intragastric acidity is low. The authors argue that 'gastrin in fetal juice could have a unique role in the in utero development of the gastrointestinal tract'.<sup>12</sup> Indeed, if the developing human fetus provides some of its own nutrition,<sup>13</sup> digestive enzymes may need to be synthesised and secreted during interuterine life.

From the small number of neonatal stomachs examined, it seems that the distribution of parietal cells remains constant after birth, and so it appears reasonable to assume that a definite change in distribution of parietal cells must occur during the third trimester. This period coincides with the development of G cells within

the antrum. Circulating gastrin is trophic to parietal cells,<sup>14</sup> but its paracrine effects are unknown. It may be that the high local concentrations of gastrin, or another factor produced by the G cell, is responsible for the loss of parietal cells. Alternatively, the development of G cells and the loss of parietal cells may be the result of other, as yet unidentified, factors. Why the process fails in 20% of the population is unclear but it has been noted that in patients with acid antra, G cells are qualitatively sparse.<sup>5</sup> Further understanding of the processes and growth factors involved in gastric epithelial development in the fetus may allow the exact mechanisms to be elucidated.

The authors wish to thank Dr Adam Smolka, Department of Anatomy, University of South Carolina for the generous gift of antibodies to intrinsic factor and H<sup>+</sup>/K<sup>+</sup> ATPase.

- 1 Derbyshire SA, Lagopoulos M, Lee T, Primrose JN. Distribution of the vagus nerve to the human pyloric antrum and possible surgical implications. *Clin Anat* 1990; 3: 25-31.
- 2 Simms JM, Bird NC, Johnson AG. An unusual acid antrum. *Br J Surg* 1985; 72: 12.
- 3 Rogers MJ, Lagopoulos M, Primrose JN. Is the antrum clinically important after highly selective vagotomy for duodenal ulcer disease? *Br J Surg* 1988; 75: 1249.
- 4 Sternberger LA. *Immunocytochemistry*. 2nd ed. New York: J Wiley & Sons, 1979.
- 5 Salenius P. On the ontogenesis of the human gastric epithelial cells. *Acta Anat (Basel)* 1962; 46: 1-76.
- 6 Norura Y. On the submicroscopic morphogenesis of parietal cells in the gastric gland of the human foetus. *Z Anat Entwicklungsgeschichte (Berlin)* 1966; 125: 316-22.
- 7 Naik KS, Lagopoulos M, Primrose JN. Distribution of antral G cells in relation to the parietal cells of the stomach and anatomical boundaries. *Clin Anat* 1990; 3: 17-24.
- 8 Euler AR, Bryne WJ, Meis PJ, Leake RD, Ament ME. Basal and pentagastrin stimulated acid secretion in newborn human infants. *Pediatric Res* 1979; 13: 36-7.
- 9 Schwarz M, Weber J. Gastric intrinsic factor in the human foetus. *Scand J Gastroenterol* 1971; 9 (suppl): 57-9.
- 10 Larsson LI, Hakanson R, Sjöberg NO, Sundler F. Fluorescence histochemistry of the gastrin cell in fetal and adult man. *Gastroenterology* 1975; 68: 1152-9.
- 11 Hirsh-Marie H, Loislilier F, Touboul JP, Burtin P. Immunochemical study and cellular localization of human pepsinogens during ontogenesis and in gastric cancer. *Lab Invest* 1976; 34: 623-32.
- 12 Schulkes A, Chick P, Hardy KJ. Presence and stability of gastrin in the gastric juice of fetal sheep. *Clin Exp Pharmacol Physiol* 1984; 11: 45-52.
- 13 Friis-Hausen B. Body water metabolism in early infancy. *Acta Paediatr Scand* 1982; 296: 44-8.
- 14 Johnston LR. The trophic action of gastrointestinal hormones. *Gastroenterology* 1976; 72: 278-87.