

# Induction of intestinal lesions in nu/nu mice induced by transfer of lymphocytes from syngeneic mice infected with murine retrovirus

K Suzuki, T Narita, R Yui, K Ohtsuka, S Inada, T Kimura, Y Okada, M Makino, T Mizuochi, H Asakura, M Fujiwara

## Abstract

**Background**—Murine leukemia virus, LP-BM5, induces severe immunodeficiency with abnormal lymphoproliferation in susceptible C57BL/6 mice. In a previous study, it was shown that a Sjögren's syndrome-like systemic exocrinopathy is induced in the virus infected mice.

**Aims**—To examine lymphocyte functions of the virus infected mice.

**Methods**—Four-week old mice were inoculated with the virus and their spleen cells were transferred into syngeneic nu/nu mice. Their organs were examined by light and electron microscopy. Phenotypes of the colon infiltrating cells were examined by flow cytometry.

**Results**—All nu/nu recipients had died by six weeks after cell transfer, showing running disease like cachexia with diarrhoea and anal bleeding. Histopathological examination revealed that systemic exocrinopathy was adoptively transferable and that the colon became thickened due to mononuclear cell infiltration into the mucosal and submucosal layer with hyperplasia of intestinal epithelial cells. No virus particles were found in the colon. Flow cytometric analyses revealed that most of the infiltrating CD4+ T cells showed CD45RB<sup>low</sup>. No intestinal lesions were observed in the virus infected mice nor in nu/nu mice inoculated with normal lymphocytes.

**Conclusion**—Lymphocytes of the virus infected mice induced colitis and hyperplasia of intestinal epithelial cells as well as systemic exocrinopathy in nu/nu mice. Our experimental system may give some insight into intestinal lesions associated with virus infection.

(Gut 1997; 41: 221–228)

Keywords: murine leukemia virus; nude mice; enterocolitis; colitogenic cells

Immunodeficient states are frequently accompanied by autoimmune-like phenomena.<sup>1–3</sup> For example, patients with AIDS are reported to carry various autoantibodies such as antinuclear antibodies or rheumatoid factor<sup>4</sup> and show signs of Sjögren's syndrome-like exocrinopathy or systemic lupus erythematosus (SLE) like symptoms.<sup>5</sup> Conversely, patients with Sjögren's syndrome or SLE demonstrate immunodeficient phenomena due to T and B cell dysfunctions.<sup>6,7</sup> Immunodeficiency and autoimmunity are thus not contradictory phenomena but are associated with each other owing to dysregulation of the immune system.

The retrovirus known as LP-BM5 is a murine leukaemia virus and is known to induce profound immunodeficiency with splenomegaly and generalised lymphadenopathy in susceptible mice—for example, the C57BL/6 (B6) strain.<sup>8,9</sup> The virus infected mice show some resemblance to humans with AIDS and they have been studied as a murine model of AIDS (MAIDS).<sup>10</sup>

As reported previously, during the course of our studies on systemic lesions of mice infected with LP-BM5, we found that systemic exocrinopathy resembling Sjögren's syndrome was induced.<sup>11</sup> We assume that a population of autoreactive lymphocytes in the virus infected mice might be activated and acquire the capacity to induce the exocrinopathy. In order to analyse the functions of lymphocytes of MAIDS mice, we attempted to transfer spleen cells of the virus infected B6 mice into B6 nu/nu mice. The nude mice are not susceptible to LP-BM5 due to absence of mature T lymphocytes and they do not show any symptoms or histological lesions following inoculation of the virus.<sup>12</sup> In these studies we found unexpected inflammatory intestinal lesions in the recipient nu/nu mice which seem to be unique. The purpose of this paper is to report our findings and discuss the developmental mechanism of the disease with special reference to autoimmune colitis.

**Methods**

**ANIMALS**

Female C57BL/6 (B6) mice were purchased from Charles River Japan, Atsugi, Kanagawa. B6 nu/nu mice were kindly provided by Dr Norimitsu Satoh (Division of Comparative Biology, Niigata University School of Medicine, Niigata, Japan). All mice were maintained at the Animal Center for Biomedical Research, Faculty of Medicine, the University of Tokyo, under specific pathogen free conditions. All animal experiments were performed according to the "Guide for Animal Experimentation" of the Faculty of Medicine, University of Tokyo.

## Methods

### ANIMALS

Female C57BL/6 (B6) mice were purchased from Charles River Japan, Atsugi, Kanagawa. B6 nu/nu mice were kindly provided by Dr Norimitsu Satoh (Division of Comparative Biology, Niigata University School of Medicine, Niigata, Japan). All mice were maintained at the Animal Center for Biomedical Research, Faculty of Medicine, the University of Tokyo, under specific pathogen free conditions. All animal experiments were performed according to the "Guide for Animal Experimentation" of the Faculty of Medicine, University of Tokyo.

### VIRUS

Murine leukemia virus LP-BM5 was prepared from the supernatant of cloned G6 cells

Animal Center for Biomedical Research, Faculty of Medicine, University of Tokyo, Tokyo, Japan

K Suzuki  
S Inada  
T Kimura  
M Fujiwara

Third Department of Internal Medicine, Niigata University School of Medicine, Niigata, Japan

K Ohtsuka  
H Asakura

Research Laboratory, Zenyaku Kogyo Company Ltd, Tokyo, Japan

T Narita  
R Yui

Department of Bacterial and Blood Products, National Institute of Health, Tokyo, Japan

Y Okada  
M Makino  
T Mizuochi

Correspondence to: Dr Michio Fujiwara, Animal Center for Biomedical Research, Faculty of Medicine, University of Tokyo, Hongo 7-3-1, Tokyo 113, Japan.

Accepted for publication 28 January 1997

infected with the retrovirus. Twenty four hour culture supernatant of G6 cells contained approximately  $5 \times 10^4$  plaque forming units per ml of ecotropic virus as determined by XC plaque assay. Aliquots containing the virus were stored at  $-80^\circ\text{C}$  until use. For the infection, four week old B6 mice were inoculated intraperitoneally with 0.2 ml of the stock solution of LP-BM5.

#### MONOCLONAL ANTIBODIES

For flow cytometric analyses, the following monoclonal antibodies were used: anti-CD3 (clone 145-2C11, IgG), anti-L3T4 (clone GK1.5, IgG2b), anti-Lyt-2 (clone 53-6.7, IgG2a), anti-B220 (clone RA3-6B2, IgG2a), anti-Mac-1 (clone M-70.15, IgG2b), anti-I-A<sup>b,k</sup> (clone MIH 040-100, IgG2a), anti-H-2K<sup>b</sup> (clone MIH 030-11B, IgG2a), and anti-CD45RB (clone 16A, IgG2a).

#### PREPARATION OF SPLEEN CELL SUSPENSION FOR CELL TRANSFER EXPERIMENT

Mice were anaesthetised with ether and sacrificed by total exsanguination through cardiac puncture. To obtain splenic mononuclear cells, pieces of spleen were pressed through 200 gauge stainless steel mesh and cells were suspended in Eagle's minimum essential medium (MEM). After washing twice in MEM, the cell suspension was injected intravenously into nu/nu mice at a dose of  $5 \times 10^7$ .

#### PREPARATION OF CELLS FOR FLOW CYTOMETRIC ANALYSES

Spleen cell suspension was prepared as described above except that cells were washed once and treated with  $\text{NH}_4\text{Cl}$  buffer to lyse erythrocytes. The cells were then suspended in MEM supplemented with 2% fetal calf serum. Lymph node cells were obtained in the same way by forcing the axillary and inguinal lymph nodes through 200 gauge steel mesh.

Lamina propria lymphocytes (LPL) were collected from the intestines according to the method described previously<sup>13-15</sup> with some modifications. Briefly, the colon was removed and flushed with phosphate buffered saline (PBS) to eliminate luminal contents. Mesentery and Peyer's patch or lymphoid follicles were then resected. The intestines were opened longitudinally and cut into fragments 1-2 cm long. These fragments were incubated for 15 minutes in 20 ml  $\text{Ca}^{2+}$  and  $\text{Mg}^{2+}$  free Hanks' balanced salt solution containing 5 mM EDTA in a  $37^\circ\text{C}$  shaking water bath. The supernatant was collected and spun down, and pelleted cells were washed with PBS. This procedure for collecting LPL was repeated twice. Pellet containing intestinal intraepithelial lymphocytes (IEL) was resuspended, passed through a glass wool column to remove aggregates and dead cells and washed twice in PBS before use. Gut fragments, after removal of epithelia, were incubated in 25 ml PBS containing 2% fetal calf serum and treated with collagenase at 0.15 mg/ml for 75 minutes in a  $37^\circ\text{C}$  shaking water bath. The treated materials were collected and filtered through steel mesh. LPL were isolated by Ficoll-Isopaque density

gradient centrifugation and collected from the interface. Cells were washed twice with PBS before use.

The surface phenotypes of LPL were analysed using the dye labelled monoclonal antibodies described earlier with a FACScan (Becton Dickinson).

#### HISTOPATHOLOGICAL EXAMINATION

Tissue samples were taken from small intestine, colon, rectum, salivary and lacrimal glands, pancreas, liver, thyroid gland, spleen, thymus, and kidneys, fixed in 10% buffered formalin and then embedded in paraffin wax blocks. Sections of 4  $\mu\text{m}$  thickness were made in the usual way and stained with haematoxylin and eosin. Stained sections were examined under a light microscope.

#### ELECTRON MICROSCOPIC ANALYSIS

Mice were perfused through the heart with physiological saline and subsequently with 2.5% glutaraldehyde in phosphate buffer at pH 7.4. Tissue blocks were post-fixed with 1% osmium tetroxide in 1.8% potassium ferrocyanide, dehydrated, and embedded in Araldite. Ultrathin sections were prepared and examined under an electron microscope (Hitachi H-7000, Hitachi, Ibaraki).

#### STATISTICAL ANALYSIS

Statistical analysis was performed by Student's *t* test for the comparison of each variable appearing in table 1.

## Results

B6 mice were inoculated with LP-BM5 intraperitoneally and examined at four week intervals for 16 weeks for splenomegaly and histopathological changes as described previously.<sup>11</sup> Spleen cells were obtained four, eight, and 12 weeks after virus inoculation for cell transfer; similar findings were obtained in the nu/nu hosts irrespective of the source of spleen cells, except that the appearance of typical symptoms was delayed by about four weeks in the recipients injected with fourth week spleen cells. The reason for the delayed appearance might simply be due to the time required for the increase in the colitogenic T cell population in both donors and recipients.

Virus inoculated mice at the eighth week consistently showed splenomegaly and typical histopathological changes, and spleen cells from these mice induced typical symptoms in the inoculated nu/nu hosts. The results obtained under these conditions are described later. As a control, nu/nu mice inoculated with

TABLE 1 Cell yields from colon of nu/nu mice that were inoculated with spleen cells from mice with MAIDS

	Cell yields/mouse from colon of nu/nu mice	
	IEL	LPL
MAIDS → B6nu/nu	$2.8 \times 10^4 \ddagger$	$1.5 \times 10^{6*}$
B6 → B6nu/nu	$3.5 \times 10^4 \ddagger$	$0.7 \times 10^{6*}$

Student's *t* test: \* $p=0.0543$ ,  $\ddagger p=0.7363$ .

the same dose of spleen cells from age matched normal B6 mice were examined. Untreated and LP-BM5 injected nu/nu mice also served as controls.

Figure 1 shows the flow cytometric patterns of the inoculum spleen cell population. The contents of T cells in virus infected and untreated spleen cells were 33% and 51%, respectively, and those of B cells were 8% and 38%, respectively (figs 1A and 1B). The ratio of CD4+ and CD8+ T cells was 20:5 in virus infected mice and 22:12 in untreated mice (figs 1C and 1D). From these results, we conclude that the difference in the number of T cells might be marginal in our experimental system.

We also attempted to transfer the nylon wool column passed spleen cell population and obtained comparable results in the recipients to those in mice which received whole spleen cells. In a different experiment, we transferred spleen cells from *Corynebacterium parvum* injected mice into nu/nu mice. No pathological changes were observed in the recipients.

Figure 2 shows the survival of mice inoculated with spleen cells. The data were obtained from seven mice in each group collected from two or three experiments. All B6 nu/nu mice

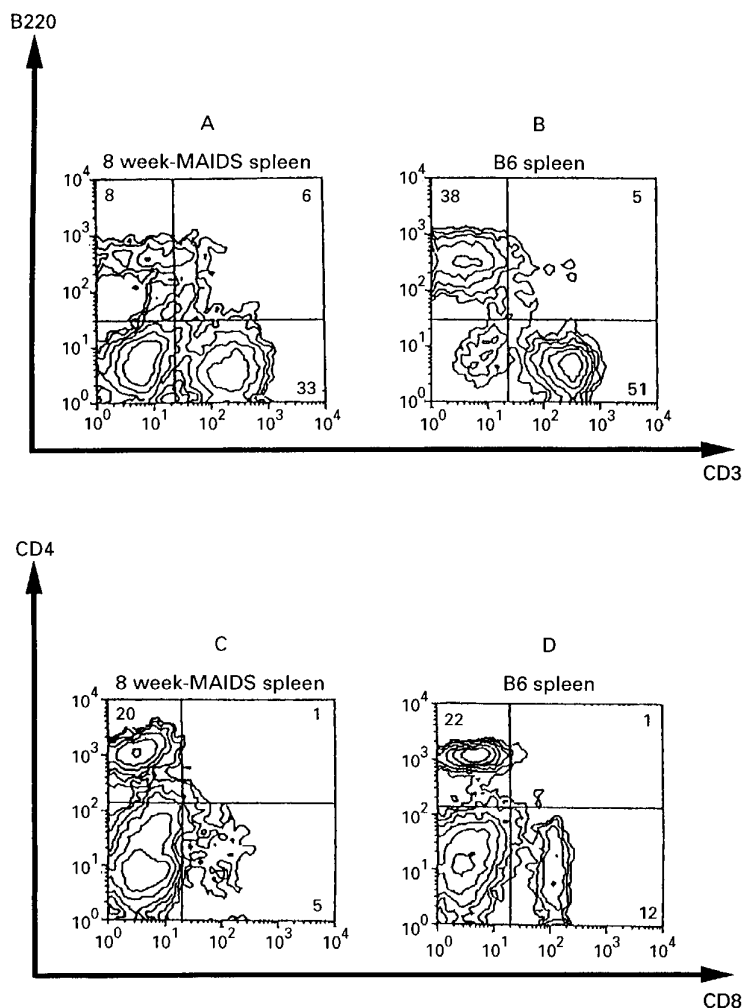


Figure 1: Flow cytometric analyses of spleen cells. A and C: spleen cells of mice infected with LP-BM5 eight weeks previously; B and D: untreated B6 spleen cells. Spleen cells were doubly stained with either FITC-anti-CD3 and PE-anti-B220 (A,B) or FITC-anti-CD4 and PE-anti-CD8 (C,D).

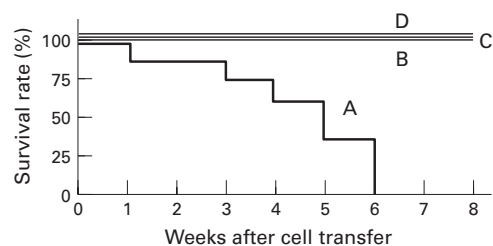


Figure 2: Survival rate of B6 nu/nu mice inoculated with MAIDS spleen cells and control groups of mice. A: B6 nu/nu mice inoculated with MAIDS spleen cells; B: B6 nu/nu mice inoculated with untreated B6 spleen cells; C: B6 nu/nu mice infected with LP-BM5; D: untreated B6 nu/nu mice. Seven mice were used in each group and data were collected from two or three repeated experiments.

inoculated with spleen cells from the virus infected mice had died six weeks after cell transfer. They began to show runting disease-like symptoms with lean hunchback, diarrhoea, anal prolapse, and bleeding at about the 15th day (figs 3B and 3C). None of these symptoms appeared in untreated and LP-BM5 infected nu/nu mice or control B6 nu/nu mice infected with normal B6 spleen cells throughout the 10 week observation period (fig 3A).

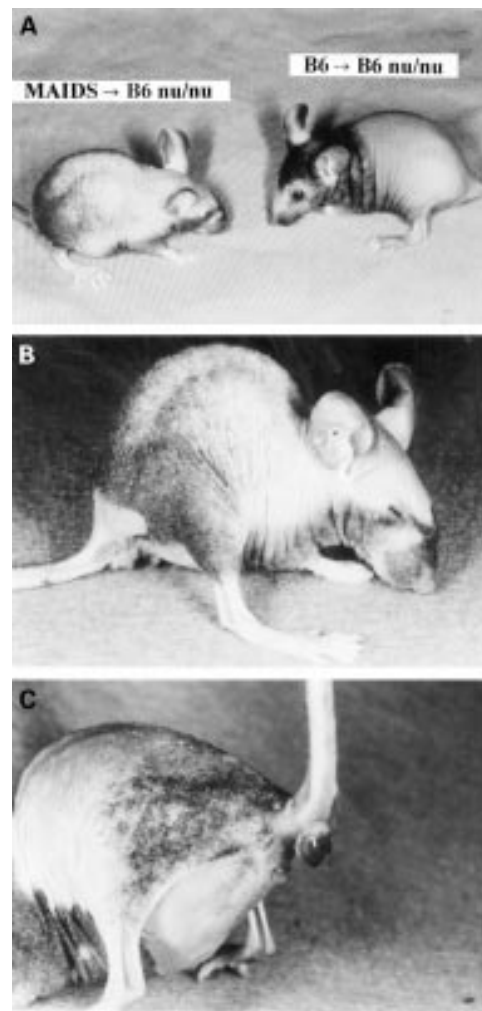


Figure 3: Runting disease-like appearance of B6 nu/nu mice. A: gross appearance of a nu/nu mouse which received MAIDS spleen cells compared with B6 nu/nu mice which received syngeneic spleen cells; B: typical hunchback of a nu/nu mouse which received MAIDS spleen cells; C: mouse which shows anal prolapse and anal bleeding.

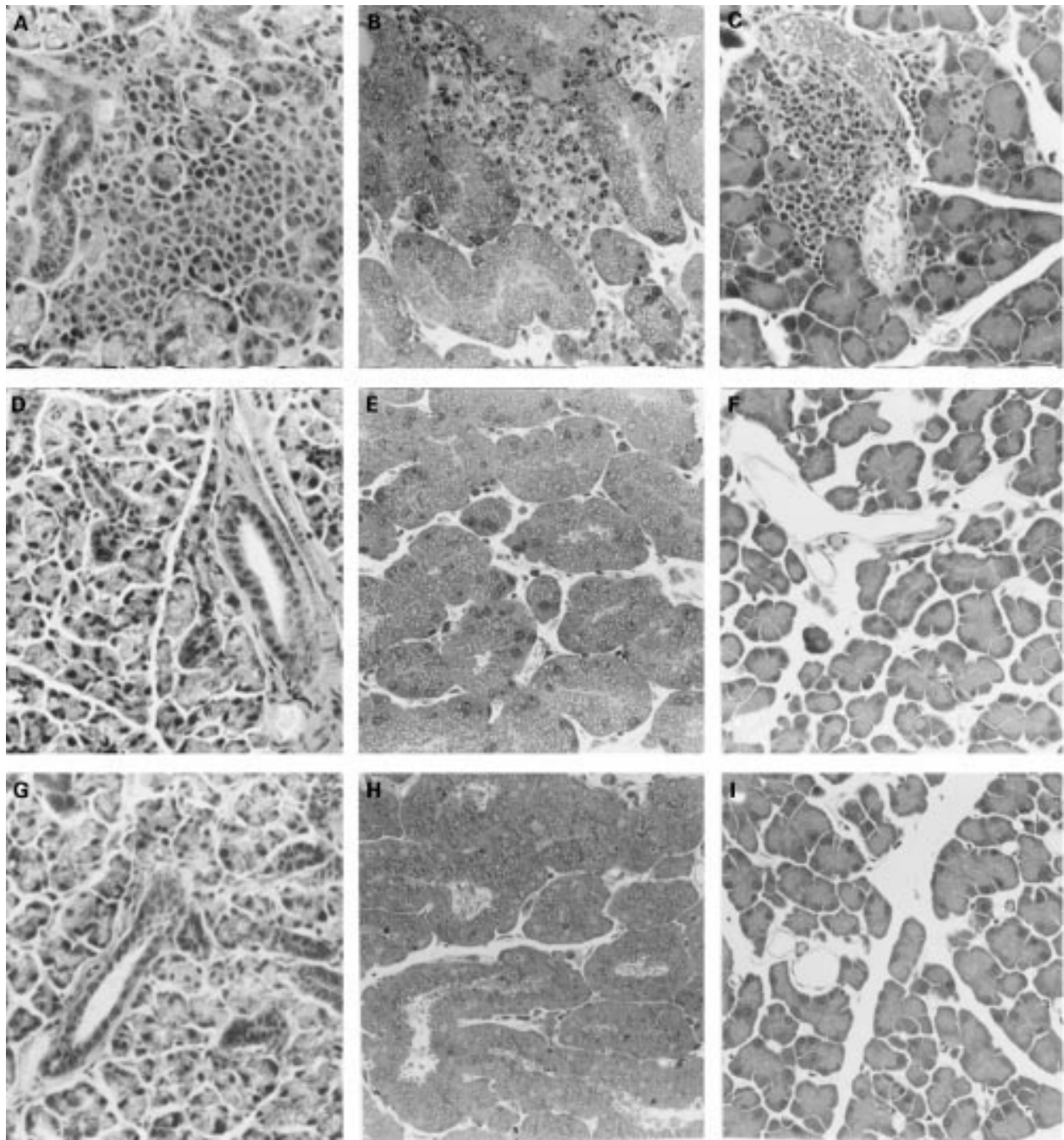


Figure 4: Sjögren's syndrome-like exocrinopathy in B6 nu/nu mice inoculated with MAIDS spleen cells. A–C: Sjögren's syndrome-like exocrinopathy in salivary gland (A), lacrimal gland (B), and pancreas (C); D–I: controls; no pathological lesions are observed in these organs of nu/nu mice inoculated with untreated B6 spleen cells (D, salivary gland; E, lacrimal gland; F, pancreas) nor in uninoculated mice (G, salivary gland; H, lacrimal gland; I, pancreas). (Haematoxylin and eosin; original magnification:  $\times 160$ .)

In another experiment, samples were obtained from four or five mice at four weeks post-transfer for histopathological examination. At necropsy, generalised lymphadenopathy and splenomegaly were conspicuous findings. Histopathological studies revealed that lymphocytic infiltration occurred in systemic exocrine glands such as submandibular (fig 4A) and lacrimal glands (fig 4B), pancreas (fig 4C), liver, lung, and kidneys in the nu/nu mice inoculated with spleen cells of MAIDS mice. These pathological lesions were identical to those seen in the donor MAIDS mice. No specified pathological lesions

were detected in B6 nu/nu mice inoculated with normal B6 spleen cells (figs 4D–F), untreated nu/nu mice (figs 4G–I), or nu/nu mice inoculated with LP-BM5 (not shown).

Intestinal tracts were examined to investigate the cause of the anal bleeding. Macroscopically, the colon and rectum were notably swollen and erosions were detected. Blood was leaking through the erosions into the intestinal lumen. Walls of the small intestine were also thickened and Peyer's patches were slightly swollen, but neither erosions nor ulcers were observed.

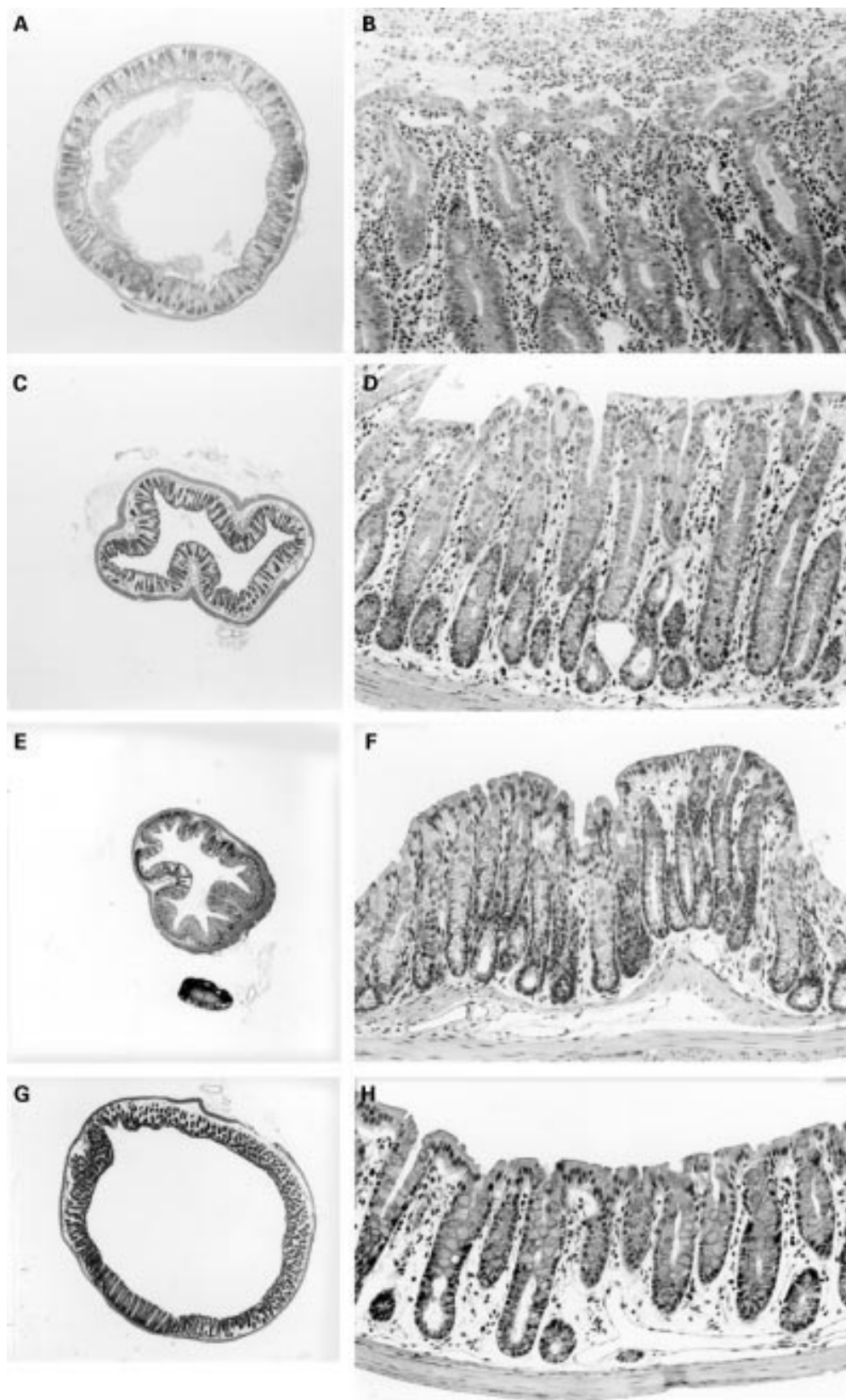


Figure 5: Occurrence of severe colitis in B6 nu/nu mice inoculated with MAIDS spleen cells. A,B: B6 nu/nu mice inoculated with MAIDS spleen cells. Colitis with thickened walls and hyperplasia of the epithelial cells are observed; C–H: controls; colons of B6 nu/nu mice inoculated with B6 spleen cells (C,D), those of untreated B6 nu/nu mice (E,F), and B6 nu/nu mice infected with LP-BM5 (G,H). (Haematoxylin and eosin; original magnifications: A,C,E,G:  $\times 16$ ; B,D,F,H:  $\times 160$ .)

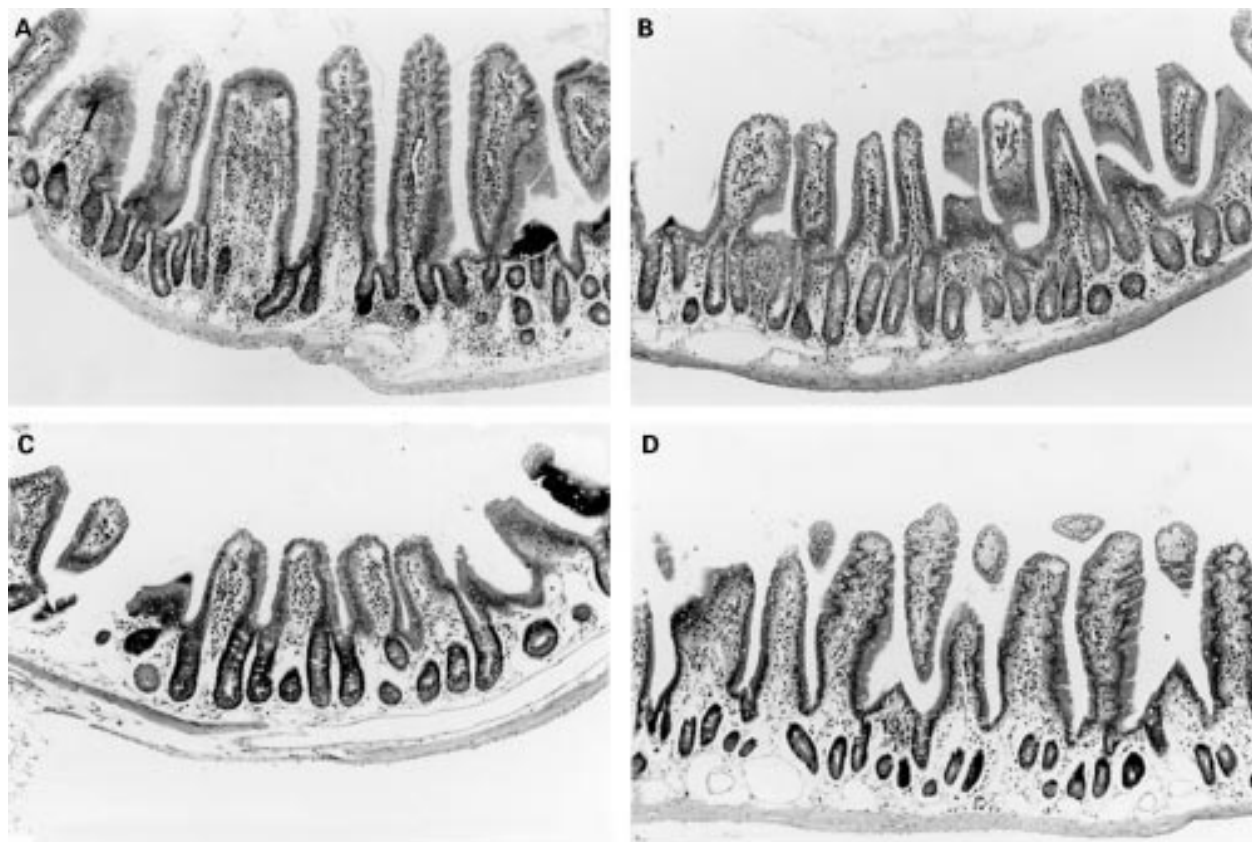


Figure 6: Occurrence of intestinal lesions in B6 nu/nu mice inoculated with MAIDS spleen cells. A: thickened intestinal wall in B6 nu/nu mice inoculated with MAIDS spleen cells. Cellular infiltration is localised in the lamina propria and submucosa of the small intestine. Epithelial cell hyperplasia is also observed but neither erosion nor ulcer is observed; B–D: controls; small intestines of B6 nu/nu mice inoculated with B6 spleen cells (B), untreated B6 nu/nu mice (C), and B6 nu/nu mice infected with LP-BM5 (D). (Haematoxylin and eosin; original magnification:  $\times 120$ .)

By light microscopy, mononuclear cell infiltration was observed in the mucosal and submucosal layer of the intestines but not in the proper muscular layer, subserosa, or serosa (figs 5A and 5B and 6A). The infiltrating cells were composed of lymphocytes, plasma cells, macrophages, and neutrophils (figs 5A and 5B and 6). Hyperplasia of the intestinal epithelial cells was also observed but disruption of mucosal epithelial cells occurred rarely. These lesions were not observed in control B6 nu/nu that were inoculated with normal B6 spleen cells (figs 5C and 5D and 6B) nor in untreated and virus infected nu/nu mice (figs 5E–H and 6C and 6D). Small and large intestines of untreated nu/nu mice were very thin and few lymphocytes were present in the lamina propria (figs 5E and 6C).

We also examined the colon and small intestine by electron microscopy. Results were identical to those observed under the light microscope. Figure 7 shows a typical lesion of the rectum of a nu/nu mouse inoculated with MAIDS spleen cells

Electron microscopy showed no virus particles in the intestines of nu/nu mice inoculated with spleen cells from the virus infected mice, nor in those of nu/nu mice inoculated with untreated B6 spleen cells. No viral particles were found in the intestines of nude mice, irrespective of the inoculation of LP-BM5.

Phenotypes of the lymphocytes present in the colon were analysed by flow cytometry.

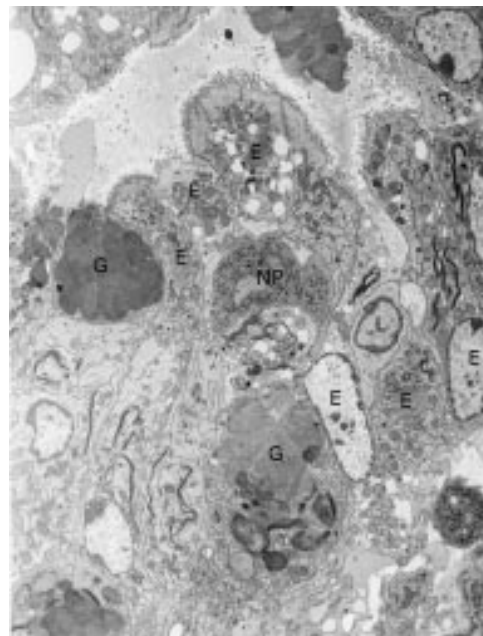


Figure 7: Electron microscopy findings of colitis in a B6 nu/nu mouse inoculated with MAIDS spleen cells. Colonic epithelial cells are injured by infiltrating lymphocytes, macrophages, and neutrophils. No virus particles are detected. Original magnification:  $\times 3000$ . E, epithelial cells; G, goblet cells; L, lymphocyte; NP, neutrophil.

Cellularity of iIEL and LPL was increased in nu/nu mice inoculated with spleen cells of MAIDS mice compared with those inoculated

with untreated B6 spleen cells. Statistically, however, there was no significant difference in cellularity between the two groups (table 1).

As shown in fig 8A, CD3<sup>+</sup> T cells predominated over B220<sup>+</sup> B cells in both iIEL and LPL of nu/nu mice inoculated with spleen cells from LP-BM5 infected B6 mice. A predominance of CD3<sup>+</sup> T cells over B220<sup>+</sup> cells was also observed in both iIEL and LPL of nu/nu mice inoculated with untreated spleen cells (fig 8A).

Intestinal T cells were examined with respect to their expression of CD4 and CD8 molecules. As shown in fig 8B, CD4<sup>+</sup> T cells predominated in both iIEL and LPL of nu/nu mice inoculated with spleen cells from LP-BM5 infected mice. In control nu/nu mice inoculated with normal B6 spleen cells, CD8<sup>+</sup> cells predominated over CD4<sup>+</sup> cells in iIEL, but CD4<sup>+</sup> cells were predominant in LPL. Few cells were present in LPL of untreated nu/nu mice and we could not collect sufficient cells for flow cytometric analyses.

CD45RB is a marker whose expression is considered to be associated with activated T cells at the effector phase.<sup>16</sup> In addition, expression of this marker is used to distinguish between memory and naive CD4<sup>+</sup> T cells. Most CD4<sup>+</sup> cells of the iIEL and LPL were CD45RB<sup>low</sup> (fig 8C), suggesting that they might contain memory cells to induce colitis.

### Discussion

In this study, we confirmed the occurrence of systemic exocrinopathy resembling Sjögren's syndrome in B6 nu/nu mice adoptively inoculated with spleen cells of mice infected with LP-BM5, as was observed in the virus infected euthymic B6 mice.<sup>11</sup> In addition, we found peculiar inflammatory intestinal lesions in these hosts. We transferred nylon column passed spleen cells of MAIDS mice and observed the same colitis in the recipient nu/nu mice. Therefore, we assume that the T cell population of MAIDS mice is responsible for the induction of colitis in our experimental system.

All mice were maintained under specific pathogen free conditions and no obvious symptoms of infection were observed in their intestines. The symptoms of runting disease, colitis, and systemic exocrinopathy were not observed in untreated and LP-BM5 infected nu/nu mice or those inoculated with normal spleen cells. We assume that the intestinal lesions of these nu/nu mice were not merely induced by infectious agents, including LP-BM5, but developed through reactions of transferred autoreactive T lymphocytes which had been activated against some unidentified target antigen(s) of intestinal organs of B6 mice.

During the development of MAIDS, polyclonal proliferation of both T and B lymphocytes is known to be induced at a relatively early phase followed by gradually progressing severe immunodeficiency.<sup>8-10 17 18</sup> We suppose that among these polyclonally activated lymphocytes, autoreactive T cell clones might be generated, which have an ability to induce Sjögren's syndrome-like systemic exocrinopathy.<sup>11</sup> As colitis was observed only in B6 nu/nu mice inoculated with lymphocytes from MAIDS




Figure 8: Flow cytometry analyses of iIEL and LPL of colon of B6 nu/nu mice inoculated with MAIDS spleen cells. iIEL and LPL of B6 nu/nu mice inoculated with either MAIDS or untreated B6 spleen cells were stained with the following fluorescent dye labelled antibodies: A: FITC-anti-CD3 and PE-anti-B220; B: FITC-anti-CD4 and PE-anti-CD8; C: PE-anti-CD4 and FITC-anti-CD45RB.

mice, we assume that colitogenic lymphocytes acquired reactivity in nu/nu hosts. These lymphocytes could not induce colitis in the virus

infected euthymic B6 mice, probably due to suppression of their function. The colitogenic lymphocytes might expand clonally and respond to the target antigens in the nu/nu hosts.

Recently, several reports have been issued indicating that CD4<sup>+</sup> T cells which express a high level of CD45RB induce wasting disease and also colitis when transferred into congenic severe combined immunodeficient (SCID) mice, and that the development of the disease is prevented by the cotransfer of purified CD4<sup>+</sup> T cells.<sup>19-21</sup> In this experimental system, autoreactive CD4<sup>+</sup> T cell clones are believed to exist in the CD45RB<sup>high</sup> population which could induce inflammatory intestinal disease in the recipient mice. It is supposed that purified CD45RB<sup>low</sup> CD4<sup>+</sup> T cells might be functioning as regulatory T cells which protect against development of the disease. Ulcerative colitis-like lesions were also reported to occur in interleukin-2 gene targeted mice.<sup>22,23</sup> In these mice, both CD4<sup>+</sup> and CD8<sup>+</sup> T cells of LPL were CD44 and CD69 positive, indicating that they were activated. Imbalance of Th1 and Th2 CD4<sup>+</sup> cells is believed to be a possible cause of the development of some autoimmune diseases.<sup>24</sup> According to the hypothesis, Th1 type cells may be effectors for colitis and Th2 type ones may inhibit its development in the SCID mice model. Histopathologically, intestinal lesions described in this paper resemble those of the SCID model. However, most of the transferred T cells of MAIDS spleen cells were CD45RB<sup>low</sup> as reported by others,<sup>17,18</sup> and the LPL of the nu/nu mice with colitis were also CD45RB<sup>low</sup> as shown in this paper. In our experimental system, Th2 type CD4<sup>+</sup> T cells may play a key role in disease progression. We are now analysing the nature of these cells with special reference to cytokine production.

B6 mice inoculated with MAIDS lymphocytes showed the same symptoms as the donor, but no signs of intestinal lesions. Thus, one possibility for the occurrence of intestinal lesions in nu/nu hosts might be lack of a population of lymphocytes which protect or suppress the development of colitis by autoreactive lymphocytes. For example, iIEL of nude mice are composed of only  $\gamma\delta$ T cells lacking the  $\alpha\beta$ T cell receptor. Fujihashi *et al*<sup>25</sup> have shown that iIEL with  $\gamma\delta$ T cell receptors have a contrasuppressor function. On the other hand,  $\alpha\beta$ T cell receptors bearing iIEL which nude mice lack may play a protective role in development of the colitis. The colitogenic lymphocytes of the LP-BM5 infected mice, once transferred into nu/nu mice, might recognise thus far unknown target antigens and become activated to destruct presumed target cells. Identification of these target antigens and the character of colitogenic lymphocytes, including T cell receptor usage, should be studied further.

In summary, lymphocytes of MAIDS mice, when transferred into syngeneic nu/nu mice, could induce colitis and hyperplasia of the intestinal epithelial cells as well as systemic exocrinopathy in nu/nu hosts. Our experimental system may be a unique animal model for analysing the developmental course of gas-

trointestinal lesions due to defects in immunoregulatory mechanisms.

We thank Dr H Ishikawa (Department of Microbiology, Keio University School of Medicine, Tokyo, Japan) for helpful discussion, Drs K Satoh, K Hasegawa, and S Yamagawa for flow cytometric analyses of iIEL and LPL, and Mrs S Akiyama for technical assistance. This work was supported by grants from the Ministries of Education and of Health and Welfare, the Government of Japan.

- 1 Fauci AS. The human immunodeficiency virus: infectivity and mechanisms of pathogenesis. *Science* 1988; **239**: 617-22.
- 2 Ziegler JL, Stites DP. Hypothesis: AIDS is an autoimmune disease directed at the immune system and triggered by a lymphotropic retrovirus. *Clin Immunol Immunopathol* 1986; **41**: 305-13.
- 3 Kopelman RG, Zolla-Pazner S. Association of human immunodeficiency virus infection and autoimmune phenomena. *Am J Med* 1988; **84**: 82-8.
- 4 Spivak JL, Bender BS, Quinn TC. Hematologic abnormalities in the acquired immune deficiency syndrome. *Am J Med* 1984; **77**: 224-8.
- 5 Clerck LC, Counttenye MM, Broe ME, *et al*. Acquired immunodeficiency syndrome mimicking Sjogren's syndrome and systemic lupus erythematosus. *Arthritis Rheum* 1988; **31**: 272-5.
- 6 Fox RI, Kang HI. Sjogren's syndrome: an autoimmune exocrinopathy. In: Bona CA, Siminovitch KA, Zanetti M, Theofilopoulos AN, eds. *The molecular pathology of autoimmune diseases*. Basel: Harwood Academic Publishers, 1993: 317.
- 7 Hahn BH. Systemic lupus erythematosus. In: Isselbacher KJ, Braunwald E, Wilson JD, Martin JB, Fauci AS, Kasper DL, eds. *Principles of internal medicine*. New York: McGraw-Hill, 1994: 1643.
- 8 Mosier DE, Yetter RA, Morse III HC. Retroviral induction of acute lymphoproliferative disease and profound immunosuppression in adult C57BL/6 mice. *J Exp Med* 1985; **161**: 766-84.
- 9 Klinken SP, Fredrickson TN, Hartley JW, Yetter RA, Morse III HC. Evolution of B cell lineage lymphomas in mice with a retrovirus-induced immunodeficiency syndrome, MAIDS. *J Immunol* 1988; **140**: 1123-31.
- 10 Jolicoeur P. Murine acquired immunodeficiency syndrome (MAIDS): an animal model to study the AIDS pathogenesis. *FASEB J* 1991; **5**: 2398-405.
- 11 Suzuki K, Makino M, Okada Y, *et al*. Exocrinopathy resembling Sjogren's syndrome induced by a murine retrovirus. *Lab Invest* 1993; **69**: 430-5.
- 12 Mosier DE, Yetter RA, Morse HC III. Functional T lymphocytes are required for a murine retrovirus-induced immunodeficiency disease (MAIDS). *J Exp Med* 1987; **165**: 1737-42.
- 13 Ohtsuka K, Hiai T, Watanabe H. Similarities and differences between extrathymic T cells residing in mouse liver and intestine. *Cell Immunol* 1994; **153**: 52-66.
- 14 Davis MDJ, Parrott DMV. Preparation and purification of lymphocytes from the epithelium and lamina propria of murine small intestine. *Gut* 1981; **22**: 481-8.
- 15 Van der Heijden PJ, Stoch W. Improved procedure for the isolation of functionally active lymphoid cells from the murine intestine. *J Immunol Methods* 1987; **103**: 161-7.
- 16 Birkeland ML, Johnson P, Trowbridge I, Pure E. Changes in CD45 isoform expression accompany antigen-induced murine T cell activation. *Proc Natl Acad Sci USA* 1989; **86**: 6734-8.
- 17 Muralidhar G, Koch S, Haas M, Swain SL. CD4 T cells in murine acquired immunodeficiency syndrome: polyclonal progression to anergy. *J Exp Med* 1992; **175**: 1589-99.
- 18 Selvey LA, Morse HC III, Granger LG, Hodes RJ. Preferential expansion and activation of V $\beta$ 5<sup>+</sup> CD4<sup>+</sup> T cells in murine acquired immunodeficiency syndrome. *J Immunol* 1993; **151**: 1712-22.
- 19 Powrie F, Mason D. OX-22<sup>high</sup> CD4<sup>+</sup> T cells induce wasting disease with multiple organ pathology: prevention by the OX-22<sup>low</sup> subset. *J Exp Med* 1990; **172**: 1701-8.
- 20 Powrie F, Leach MW, Mauze S, Caddle LB, Coffman RL. Phenotypically distinct subsets of CD4<sup>+</sup> T cells induced or protect from chronic intestinal inflammation in C.B-17 scid mice. *Int Immunol* 1993; **5**: 1461-71.
- 21 Morrissey P, Charrier K, Braddy S, Liggitt D, Watson JD. CD4<sup>+</sup> T cells that express high levels of CD45RB induce wasting disease when transferred into congenic severe combined immunodeficient mice. Disease development is prevented by cotransfer of purified CD4<sup>+</sup> T cells. *J Exp Med* 1993; **178**: 237-44.
- 22 Sadlack B, Merz H, Schorle H, Schimpl A, Feller AC, Horak I. Ulcerative colitis-like disease in mice with a disrupted interleukin-2 gene. *Cell* 1993; **75**: 253-61.
- 23 Strober W, Ehrhardt RO. Chronic intestinal inflammation: an unexpected outcome in cytokine or T cell receptor mutant mice. *Cell* 1993; **75**: 203-5.
- 24 Kroemer G. Soluble factors in immune homeostasis: cytokines and glucocorticoids. In: *Mechanism of immunological self-tolerance*. Austin, Texas: RG Landes Co., 1994: 89-106.
- 25 Fujihashi K, Taguchi T, Aicher WK, McGhee JR, Bluestone JA, Eldridge JH, *et al*. Immunoregulatory functions for murine intraepithelial lymphocytes:  $\gamma\delta$ T cell receptor-positive (TCR<sup>+</sup>) T cells abrogate oral tolerance, while  $\alpha\beta$ TCR<sup>+</sup> T cells provide B cell help. *J Exp Med* 1992; **175**: 695-707.