

Co-amoxiclav jaundice: clinical and histological features and HLA class II association

J O'Donohue, K A Oien, P Donaldson, J Underhill, M Clare, R N M MacSween, P R Mills

Abstract

Background and aims—Jaundice associated with co-amoxiclav has been increasingly recognised. We aimed to characterise its clinical and histological features and to investigate linkage with human leucocyte antigen class II haplotypes.

Methods—We identified cases in the west of Scotland in the period 1991–1997 and performed polymerase chain reaction amplification and oligonucleotide probing on whole blood.

Results—Twenty two cases were identified (10 male, mean age 59.1 years). Jaundice occurred a median of 17 days after drug commencement, with a median peak bilirubin level of 225 $\mu\text{mol/l}$ (range 84–598) and median duration of jaundice 69 days (range 29–150). Two patients had primary biliary cirrhosis and two other patients had persistently abnormal liver biochemistry on follow up. One death occurred in a frail elderly woman despite resolving jaundice. The frequency of jaundice was 1 in 78 209 co-amoxiclav prescriptions. Liver biopsy, available in 12 patients, showed perivenular bilirubinostasis, accompanying reactive ceroid laden macrophages, and portal inflammation with focal injury to interlobular bile ducts. Fourteen of 20 patients had DRB1*1501 compared with 27 of 134 controls ($p < 2.5 \times 10^{-6}$; odds ratio (OR) 9.25; relative risk (RR) 6.43). Of these, seven patients were homozygous for DRB1*1501 ($p < 10^{-3}$; OR 35.54; RR=8.68) compared with two of 134 controls. All patients with DRB1*1501 had the extended haplotype DRB1*1501-DRB5*0101-DQA1*0102-DQB1*0602.

There were no clinical or histological differences between genotypes.

Conclusions—Co-amoxiclav associated hepatotoxicity may have a genetic basis and be delayed, severe, and prolonged, although complete recovery is usual.

(Gut 2000;47:717–720)

Keywords: co-amoxiclav; jaundice; human leucocyte antigen

The addition of clavulanic acid, a potent inhibitor of β lactamases, to amoxicillin produces the combination co-amoxiclav (amoxicillin-clavulanate potassium), first marketed in 1981. Co-amoxiclav is now one of the most frequently prescribed antibiotics. Hepatotoxicity associated with the use of the drug was

first reported in 1988,¹ is mostly cholestatic, and full recovery is usual, although there are two reports of fatal outcomes.^{2,3} A recent study of 35 patients from Belgium has reported an increase (57% cf. 10%) in the frequency of the HLA haplotype DRB1*1501-DQB1*0602 compared with matched controls.⁴ The aims of this study were to determine the incidence of co-amoxiclav associated jaundice in the west of Scotland and to describe its clinical characteristics and histological appearance of liver biopsy specimens. In addition, we sought to confirm the recently reported association with the HLA DRB1*1501-DQB1*0602 haplotype in these patients.

Patients and methods

The source population was the west of Scotland, a region with a population of 2.597 million in 1991.⁵ Cases reported in the seven years from 1 January 1991 to 31 December 1997 were studied. Co-amoxiclav associated jaundice was defined as an episode of clinically apparent jaundice occurring within 60 days of drug exposure, with causality based on international criteria of drug induced liver disorders.⁶ Three methods of case finding were used: a postal enquiry of all gastroenterologists in the region (100% response), a search of pathology records of the Western Infirmary University Department of Pathology, and a search of hospital discharge diagnoses using international classification of disease codes (ICD9 and ICD10) (Dr P Sandham, Drug Information Unit, Greater Glasgow Health Board). Clinical details were obtained from medical records of the referring institution, supplemented where necessary by the general practitioner and patient.

All surviving patients gave informed consent for the study and had blood drawn and sent to the Institute of Liver Studies. DNA was extracted from whole blood EDTA samples. HLA DRB, DQA, DQB, and DPB genotypes were determined by polymerase chain reaction amplification and oligonucleotide probing. The distribution of DRB1, DQA1 and DQB1, and DPB1 alleles was compared with those of 134 racially matched healthcare workers.⁷ Liver biopsies from 12 of the 22 cases were available for review by two pathologists (KO and RNM MacS) using standard stains. The number of prescriptions for co-amoxiclav issued in the west of Scotland in the study period was deter-

Abbreviations used in this paper: HLA, human leucocyte antigen; PBC, primary biliary cirrhosis; OR, odds ratio; RR, relative risk.

Department of
Gastroenterology,
Gartnavel General
Hospital, Glasgow
G12 0YN, UK
J O'Donohue
P R Mills

University
Department of
Pathology, Western
Infirmary, Glasgow
G11 6NT, UK
K A Oien
R N M MacSween

Institute of Liver
Studies, King's College
Hospital, London
SE5 9RS, UK
P Donaldson
J Underhill
M Clare

Correspondence to:
Dr J O'Donohue, University
Hospital Lewisham, London
SE13 6LH, UK. Email:
john.odonohue@uhl.nhs.uk

Accepted for publication
9 May 2000

mined from central records (Pharmacy Practice Division, National Health Service in Scotland, Edinburgh, UK).

Clinical and biochemical data were analysed using Pearson's correlation coefficient for independent variables where appropriate and, for non-parametric data, the Mann-Whitney U test (SPSS for Windows, version 7.5.2). Distribution of different HLA alleles was compared by χ^2 or Fisher's exact test as appropriate using the EPISTAT program (Epiinfo, CDC, Atlanta, Georgia, USA). Probability (p) values were corrected for multiple testing (pc); the number of individuals positive for each allele was calculated rather than the number of chromosomes.⁸ The level of significance in all tests was set as $p < 0.05$.

Results

Twenty two patients were identified. All were Caucasian and 10 were male. Mean age was 59.1 years (range 43–91). All patients presented with jaundice. Median duration of co-amoxiclav treatment was seven days (range 3–21), with a median total dose of 8.3 g of amoxicillin and 4.1 g of clavulanic acid. The median interval between initiation of co-amoxiclav treatment and development of jaundice was 17 days (range 3–48); in six patients (27%), the onset of jaundice was delayed for more than three weeks after starting the drug. Median peak bilirubin level was 225 $\mu\text{mol/l}$ (range 84–598) and median duration of jaundice was 69.0 days (range 29–150). One patient received intravenous and the remainder oral therapy. At onset of jaundice, four patients had been receiving other medications for at least four months; in two patients, metronidazole was commenced at the same time as co-amoxiclav. Patients Nos 12 and 21 had previously suffered episodes of jaundice; on enquiry, it was found that co-amoxiclav had also been prescribed shortly before the previous episode of jaundice, but no association with the antibiotic had been suspected.

The pattern of the biochemical abnormalities⁶ was cholestatic in eight, hepatocellular in one, and mixed in eight (not categorised in five patients). Abdominal ultrasound examination showed normal calibre extrahepatic bile ducts in all but patient No 20 who subsequently had normal endoscopic retrograde cholangiopancreatography. Tests for serum hepatitis B surface antigen, antibodies to hepatitis C, and for IgM antibody to hepatitis A were negative in every patient. Two female patients had serum antimitochondrial antibodies detected by indirect immunofluorescence at titres of $>1:200$; one (patient No 22) with known primary biliary cirrhosis (PBC) and the other, a 48 year old female (patient No 1) with no prior history of liver disease.

The 12 patients who had percutaneous liver biopsy had similar clinical and biochemical features to the non-biopsied patients (Mann-Whitney U test). Patient No 17 was biopsied 12 months after jaundice when full clinical resolution had occurred, apart from continued slight elevation of serum alkaline phosphatase; this biopsy was normal except for minimal

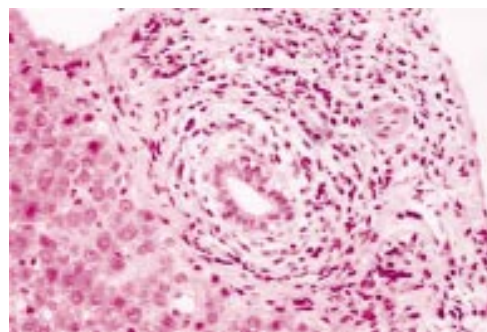


Figure 1 Portal tract containing a mainly lymphocytic inflammatory infiltrate. There is inflammation and oedema around the bile duct which contains intraepithelial lymphocytes and shows epithelial damage (haematoxylin and eosin).

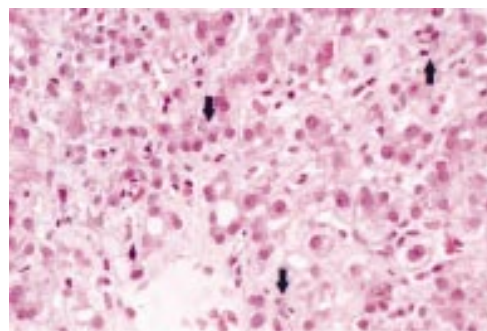


Figure 2 Perivenular bilirubinostasis with intracellular and intracanalicular bile plugs (arrows) with cholestatic rosettes (haematoxylin and eosin).

steatosis. The other biopsies were performed between four and 36 days after the onset of jaundice. As patient No 1 had a high serum titre for antimitochondrial antibodies and was diagnosed as having PBC, her biopsy was excluded from the series. In no biopsy was there architectural disturbance or fibrosis. In all biopsies, the portal tracts contained a mild to moderate chronic inflammatory cell infiltrate, composed mainly of lymphocytes with a few eosinophils. There were no granulomas. The inflammation was concentrated around interlobular bile ducts of which many contained intraepithelial lymphocytes, sometimes with neutrophils (fig 1). Five cases showed more severe (but variable) bile duct injury, with epithelial swelling, vacuolation, and degeneration (fig 1). One biopsy contained occasional portal tracts without bile ducts. All biopsies showed perivenular bilirubinostasis (fig 2) accompanied by numerous reactive ceroid laden macrophages and mild spotty liver cell necrosis. In all but one case there was periportal cholangiolitis. Copper associated protein was absent. None of the biopsy features showed any relationship with HLA haplotype (Mann-Whitney U test).

HLA TYPING

Whole blood samples were available in 20 surviving patients. Seventy per cent (14/20) of patients had DRB1*1501 compared with 20% (27/134) of controls ($p = 2.5 \times 10^{-6}$; odds ratio (OR) 9.25; relative risk (RR) 6.43). Of these, seven patients were homozygous for DRB1*1501 compared with 2/134 controls

($p < 10^{-8}$; OR 35.54; RR 8.68). All patients had the extended haplotype DRB1*1501-DRB5*0101-DQA1*0102-DQB1*0602. The haplotype did not extend to DPB, a number of different alleles being present in these patients. Patients homozygous or heterozygous for DRB1*1501 were compared with those without the haplotype. There were no significant differences in duration or severity of jaundice or in the latent period between drug administration and jaundice between these three groups (NS, Mann-Whitney U test). Of patients with the DRB1*1501 haplotype, the pattern of liver biochemistry⁸ was cholestatic in four, mixed in six, hepatocellular in one, and unknown in three; of patients without the haplotype, the pattern was cholestatic in two, mixed in two, and unknown in two (NS). Both patients with PBC had the DRB1*1501 haplotype (one homozygous and one heterozygous). When the data were analysed excluding the two patients with known PBC, 12 of 18 patients (67%) had the DRB1*1501 haplotype compared with 27 of 134 controls ($p < 0.00016$).

CLINICAL OUTCOME

One fatality from multiorgan failure occurred in a frail 91 year old female (patient No 9) who had received co-amoxiclav on the first postoperative day after fixation of a fractured neck of femur; cholestasis had been resolving prior to death. Jaundice resolved fully in all other surviving patients, apart from patient No 22 with known PBC in whom serum bilirubin declined to its pre-co-amoxiclav level within 12 weeks. Patient No 1, who also had positive serum antimitochondrial antibodies and presumably had PBC, had significantly elevated serum gamma glutamyl transpeptidase and alkaline phosphatase levels two years later. Patient No 8, a 45 year old female whose initial liver biopsy showed only features of cholestasis, had abnormal liver biochemistry throughout five years of follow up, and patient No 17 had marginally abnormal liver biochemistry one year after drug exposure, when liver biopsy showed only minimal steatosis.

PREVALENCE

The number of prescriptions of co-amoxiclav in the west of Scotland in the seven year study period was 1 720 592. The reported frequency of jaundice in this period was therefore 1 in 78 209 prescriptions, with an average incidence of three cases yearly.

Discussion

We have described 22 cases of significant jaundice associated with co-amoxiclav, a frequency of 1 case per 78 209 prescriptions. This is comparable with the previously published rates of spontaneously reported hepatic adverse events of 1 in 56 000⁹ and one in 100 000,¹⁰ but lower than the rate of 1 per 4449 prescriptions reported from a retrospective cohort study of family practitioners' records with a greater proportion of milder cases.¹¹ As a result of these data, it has been recommended that use of the compound in the UK should be reserved for

when amoxicillin resistant β lactamase strains are suspected.¹²

The causality of the association between jaundice and co-amoxiclav exposure was examined according to internationally agreed criteria.⁶ The interval from drug administration to onset of jaundice (latent period) was found, as previously reported,¹³ to be longer (median 17 days) with co-amoxiclav than with other drugs associated with hepatotoxicity and was a significant factor in delaying the diagnosis, as an association with co-amoxiclav was not suspected by the primary care physician in any patient. In no patient was any other medication considered responsible for hepatotoxicity. In patient Nos 1 and 22, who had PBC, there was a clear temporal relationship between co-amoxiclav and subsequent hepatotoxicity. The two patients who had been inadvertently rechallenged (patient Nos 12 and 21) had a shorter than average latent period (six and nine days), perhaps reflecting a pre-sensitisation phenomenon as previously recognised.^{13 14} Apart from the patients with PBC, two other patients had persistent disturbance in liver biochemistry but without evidence of liver failure or cirrhosis; follow up biopsy in one was normal. Cholestasis persisting for more than six months after co-amoxiclav has previously been observed in only three patients.^{15 16} In the fatality in our series, many comorbid factors were present; however, one of the two previous reports of fatalities described death from liver failure one month after co-amoxiclav in a previously healthy 37 year old man.³

We found three characteristic histological features: perivenular bilirubinostasis; accompanying reactive ceroid laden macrophages; and portal inflammation with focal injury to interlobular bile ducts. This agrees with previous reports. Severe injury to the biliary epithelium was present in only five of our cases, in contrast with a previous series which described "focal destructive cholangiopathy" in every case.¹⁵ Granulomatous inflammation was absent in our series but has been described previously.^{10 15} Bile duct lesions and portal inflammation may also occur in other cholangiopathies such as PBC or primary sclerosing cholangitis. Differential diagnosis is assisted by the prominent perivenular bilirubinostasis and accompanying macrophage reaction, unusual in early chronic cholestatic disease. No copper associated protein was seen in our cases, thus favouring acute rather than chronic injury.

It is of interest that two patients had PBC in the series. Overexpression of HLA class II molecules on biliary epithelium is well described in PBC¹⁷ and may be important in the initiation of autoimmune mediated bile duct destruction in the disease; it would be plausible that such patients would also be at increased risk of developing immunologically mediated drug induced bile duct damage.

This study confirms the recently described association between the HLA haplotype DRB1*1501-DQA1*0102-DQB1*0602 and co-amoxiclav associated liver disease.⁴ However, in contrast with the latter study, we also found an increased frequency of patients with

the homozygous status for this haplotype, a difference which may reflect population differences and the small sample size in both studies. Interestingly, we found no difference between patients homozygous for DRB1*1501 and either heterozygotes for DRB1*1501 or patients negative for DRB1*1501 in the severity or duration of jaundice, in liver histology, or in the biochemical pattern of liver injury. The DRB1*1501 haplotype confers resistance to PBC¹⁸ and to type I autoimmune hepatitis,¹⁹ but susceptibility to primary sclerosing cholangitis²⁰; it is interesting that both patients in our series with co-amoxiclav associated jaundice and co-existing PBC had the DRB1*1501 haplotype. The statistical association of co-amoxiclav associated jaundice and the DRB1*1501 haplotype was still highly significant when patients with PBC were excluded from the analysis. The HLA DR2 antigen, of which DRB1*1501 is the most common allele, has also been associated with hepatitis following nitrofurantoin,²¹ with halothane induced hepatitis in Japan,²² and with allergies to ragweed pollen.²³

One explanation for co-amoxiclav associated liver disease is formation through metabolism of neoantigens and subsequent recognition of these novel antigens as foreign by the immune system. This "immune allergic hypothesis" is supported by the current observations of a strong HLA class II haplotype association. HLA class II molecules are required for antigen presentation to CD4 positive T cells. HLA alleles may differ by as little as a single codon, and one amino acid residue difference at a critical site in the resulting polypeptide may be functionally significant, determining not only the affinity with which a given antigen is presented but also the interaction of the HLA peptide complex with the T cell receptor. Alternatively, co-amoxiclav associated liver disease may arise through linkage with another gene on chromosome 6p. The "linked gene" hypothesis may explain why jaundice following treatment with co-amoxiclav is rare, although this particular HLA haplotype is common in northern Europe, being present in up to 30% of the normal population, and co-amoxiclav is commonly prescribed. Furthermore, the high frequency of homozygotes, which is unusual compared with other HLA associated diseases, may indicate that the disease is more frequently expressed in those with two copies of the candidate gene (that is, as in an autosomal recessive condition).

Interestingly, amoxicillin can bind directly to HLA molecules, and a hapten effect has been proposed in penicillin related allergies.²⁴ However, as the combination of amoxicillin and clavulanate²⁵ is more hepatotoxic than amoxicillin alone, and hepatotoxicity has been reported with clavulanate and ticarcillin,²⁶ it is possible that clavulanate is the hepatotoxic component of co-amoxiclav. Further studies of

the genetic susceptibility to co-amoxiclav associated liver disease are necessary to further elucidate the mechanism of this disease, which is at least in part immune mediated.

We thank Dr C Waugh, Pharmacy Practice Division, Common Services Agency for the National Health Service in Scotland, Edinburgh, Scotland, UK and Dr P Sandham, Statistics and Information Unit, Greater Glasgow Health Board, Glasgow, Scotland, UK. We are grateful to gastroenterologists in the west of Scotland who referred patients.

- 1 Van Den Broek JWJ, Buennemeyer BLM, Stricker BHC. Cholestatic hepatitis due to amoxicillin and clavulanic acid. *Ned Tijdschr Geneesk* 1988;**132**:1495-7.
- 2 Hebbard GS, Smith KG, Gibson PR, et al. Augmentin-induced jaundice with a fatal outcome. *Med J Aust* 1992;**156**:285-6.
- 3 Carter RW, Brodmerkel GJ. Augmentin-induced hepatorenal failure and death. *Hepatology* 1995;**22**(Pt 2):400A.
- 4 Hautekeete ML, Horsmans Y, Van Waejenberge C, et al. HLA association of amoxicillin-clavulanate-induced hepatitis. *Gastroenterology* 1999; **117**:1181-6.
- 5 Office of Population. *Census of Population*. London: HMSO, 1991.
- 6 Benichou C. Criteria of drug-induced liver disorders: report of an international consensus meeting. *J Hepatol* 1990;**11**: 272-6.
- 7 Cramp ME, Carucci P, Underhill J, et al. Association between HLA class II genotype and spontaneous clearance of hepatitis C viraemia. *J Hepatol* 1998;**29**:207-13.
- 8 Svejgaard A, Ryder LP. HLA and disease associations: detecting the strongest association. *Tissue Antigens* 1994;**43**: 18-27.
- 9 Cholestatic jaundice with co-amoxiclav. *Curr Probl Pharmacovigilance* 1993;**19**:2.
- 10 Larrey D, Vial T, Micallef A, et al. Hepatitis associated with amoxicillin-clavulanic acid: combination report of 15 cases. *Gut* 1992;**33**:368-71.
- 11 Garcia Rodriguez LA, Stricker BH, Zimmermann HI. Risk of acute liver injury associated with the combination of amoxicillin and clavulanic acid. *Arch Intern Med* 1996;**156**: 1327-32.
- 12 Revised indications for co-amoxiclav (Augmentin). *Curr Probl Pharmacovigilance* 1997;**23**:8.
- 13 Hautekeete ML, Brenard R, Horsmans Y, et al. Liver injury related to amoxicillin-clavulanic acid: interlobular bile-duct lesions and extrahepatic manifestations. *J Hepatol* 1995;**22**:71-7.
- 14 Reddy KR, Brilliant P, Schiff ER. Amoxicillin-clavulanate potassium-associated cholestasis. *Gastroenterology* 1989;**96**: 1135-41.
- 15 Ryley NG, Fleming KA, Chapman RW. Focal destructive cholangiopathy associated with amoxicillin/clavulanic acid (Augmentin). *J Hepatol* 1995;**23**:278-82.
- 16 Hartleb M, Boldys H, Januszewski K, et al. Vanishing bile duct syndrome after amoxicillin/clavulanic acid (A/CA). *J Hepatol* 1997;**26**:160A.
- 17 Yasoshima M, Nakanuma Y, Tsuneyama K, et al. Immunohistochemical analysis of adhesion molecules in the micro-environment of portal tracts in relation to aberrant expression of PDC-E2 and HLA-DR on the bile ducts in primary biliary cirrhosis. *J Pathol* 1995;**175**:319-25.
- 18 Begovich AB, Klitz W, Moonsamy PV, et al. Genes within the HLA class II region confer both predisposition and resistance to primary biliary cirrhosis. *Tissue Antigens* 1994; **43**:71-7.
- 19 Strettell MJD, Donaldson PT, Thompson LJ, et al. Allelic basis for HLA-encoded susceptibility to type I autoimmune hepatitis. *Gastroenterology* 1997;**112**:2028-35.
- 20 Donaldson PT. *Epidemiology and immunogenetics of primary sclerosing cholangitis*. Freiberg: International Falk Workshop (Part II of the Liver week), 1998.
- 21 Stricker BH, Blok AP, Claas FH, et al. Hepatic injury associated with the use of nitrofurans: a clinicopathological study of 52 reported cases. *Hepatology* 1988;**8**:599-606.
- 22 Otsuka S, Yamamoto M, Kasuya S, et al. HLA antigens in patients with unexplained hepatitis following halothane anaesthesia. *Acta Anaesthesiol Scand* 1985;**29**:497-501.
- 23 Blumenthal M, Marcus-Bagley D, Awdeh Z, et al. HLA-DR2, [HLA-B7, SC31, DR2], and [HLA-B8, SC01, DR3] haplotypes distinguish subjects with asthma from those with rhinitis only in ragweed pollen allergy. *J Immunol* 1992;**148**:411-16.
- 24 Horton H, Weston SD, Hewitt CR. Allergy to antibiotics; T cell recognition of amoxicillin is HLA-DR restricted and does not require antigen processing. *Allergy* 1998;**53**:83-8.
- 25 Garcia Rodriguez LA, Stricker BH, Zimmermann HI. Risk of acute liver injury associated with the combination of amoxicillin and clavulanic acid. *Arch Intern Med* 1996;**156**: 1327-32.
- 26 Sweet JM, Jones MP. Intrahepatic cholestasis due to ticarcillin-clavulanate. *Am J Gastroenterol* 1995;**90**:675-6.