

# PostScript

## LETTERS

### ITPA genotyping test does not improve detection of Crohn's disease patients at risk of azathioprine/6-mercaptopurine induced myelosuppression

The thiopurine drugs azathioprine (AZA) and 6-mercaptopurine (6-MP) are effective for the treatment of inflammatory bowel disease (IBD) and their prescription is increasing. Haematotoxicity, which can lead to potentially life threatening bone marrow suppression, represents the most serious side effect of thiopurine therapy. It has been attributed to the accumulation of active cytotoxic metabolites of AZA/6-MP, collectively called 6-thioguanine nucleotides, resulting from a deficiency in thiopurine catabolism specifically catalysed by the thiopurine S-methyltransferase (TPMT) enzyme. Genotyping tests are now available to identify deficient and intermediate methylators who are, respectively, homozygous and heterozygous for non-functional alleles of the TPMT gene. As pointed out by Lennard in the leading article (*Gut* 2002;51:143-6), it is clear that myelosuppression may be caused by other factors in addition to variable TPMT.

Since the identification of the molecular basis of inosine triphosphate pyrophosphatase (ITPase) deficiency,<sup>1</sup> a clinically benign condition characterised by abnormal accumulation of inosine triphosphate in erythrocytes, the possibility of a correlation between thiopurine toxicity and ITPase deficiency has been raised. Complete ITPase deficiency was found to be associated with a homozygous missense 94C>A mutation that encodes a Pro<sup>32</sup>Thr exchange, whereas an intronic IVS2+21A>C polymorphism was shown to have a less severe effect, homozygotes retaining 60% ITPase activity. It was then postulated that in ITPase deficient patients treated with thiopurine drugs, a 6-thio-ITP metabolite could accumulate resulting in toxicity.<sup>1</sup> A recent study in 62 patients with inflammatory bowel disease reported a significant association between the ITPA 94C>A polymorphism and AZA related adverse effects, specifically flu-like symptoms, rash, and pancreatitis.<sup>2</sup> No correlation was observed with occurrence of neutropenia but only 11 patients were studied. We previously reported TPMT genotype analysis in 41 Crohn's disease

(CD) patients who had experienced leucopenia during AZA/6-MP therapy.<sup>3</sup> Even though this study confirmed the efficiency of TPMT genotyping in identifying patients at risk of developing myelosuppression, it also highlighted its limitations, as only 27% of patients carried mutant alleles of the TPMT gene that were associated with enzyme deficiency. This prompted us to investigate the occurrence of ITPA mutations in this series of patients in order to evaluate whether genotyping of the ITPase gene could improve the detection rate of patients at risk of thiopurine myelotoxicity.

Our population comprising 41 patients with CD has been described in detail previously.<sup>3</sup> Briefly, all patients had either leucopenia (white blood cell count <3000/mm<sup>3</sup>; n = 24) or thrombocytopenia (platelets <100 000/mm<sup>3</sup>; n = 30), or both (n = 14), leading either to discontinuation of treatment or reduction of dose by 50% or more during AZA (n = 33) or 6-MP (n = 8) treatment. Patients were genotyped for the ITPA 94C>A and IVS2+21A>C mutations according to a previously described procedure based on endonuclease digestion of polymerase chain reaction products.<sup>1</sup> Distribution of the 41 patients according to their ITPA genotype is presented in table 1 and compared with that of a previously published control population of 100 healthy Caucasians.<sup>1</sup> Allele frequencies in the CD population were 0.085 for the 94C>A mutation and 0.12 for the IVS2+21A>C mutation, similar to frequencies observed in the control population (0.06 and 0.13, respectively). There was no significant difference in the genotypes distribution between the two populations, which confirmed the lack of association between ITPase deficiency and myelosuppression during thiopurine therapy. Due to the retrospective nature of the study, no correlation with other side effects could be investigated.

In conclusion, application of ITPA genotyping tests does not seem to improve the identification of patients at risk of myelosuppression with AZA/6-MP therapy. Although we believe that conventional TPMT genotyping tests should still be applied before the initiation of thiopurine treatment, further work is needed on the role of other candidate genes that may be involved in thiopurine haematotoxicity.

### Acknowledgements

We thank N Ferrari and A Vincent for their assistance in performing the study and the members of the GETAID for recruiting patients in the study.

**Table 1** Distribution of ITPA genotypes in 41 Crohn's disease (CD) patients and 100 healthy Caucasians

ITPA genotype	CD patients (n = 41)	Control population† (n = 100)
WT/WT	26 (0.63)*	64 (0.64)
WT/94C>A	6 (0.15)	10 (0.10)
WT/IVS2+21A>C	7 (0.17)	24 (0.24)
94C>A/94C>A	0 (0.00)	0 (0.00)
IVS2+21A>C/IVS2+21A>C	1 (0.02)	0 (0.00)
94C>A/IVS2+21A>C	1 (0.02)	2 (0.02)

\*Values in parentheses represent genotype frequencies.

†The control population comprised 100 healthy Caucasians who were genotyped in a previous study.<sup>1</sup>

D Allorge, R Hamdan, F Broly

EA2679, Faculté de Médecine/Pôle Recherche, Place de Verdun, Lille, France

C Libersa

Centre d'Investigations Cliniques, Hôpital Cardiologique, CH et U Lille, Lille, France

J-F Colombel

Service d'Hépatogastroentérologie, Hôpital Huriez, CH et U Lille, Lille, France

Groupe d'Etudes Thérapeutiques des Affections Inflammatoires Digestives (GETAID)

Service d'Hépatogastroentérologie, Hôpital Saint-Louis, Paris, France

Correspondence to: Professor J-F Colombel, Service d'Hépatogastroentérologie, Hôpital Huriez, CH et U Lille, 59037 Lille, France; jfcolombel@chru-lille.fr

doi: 10.1136/gut.2004.055947

Competing Interests: None declared.

### References

- Sumi S, Marinaki AM, Arenas M, et al. Genetic basis of inosine triphosphate pyrophosphohydrolase deficiency. *Hum Genet* 2002;111:360-7.
- Marinaki AM, Ansari A, Duley JA, et al. Adverse drug reactions to azathioprine therapy are associated with polymorphism in the gene encoding inosine triphosphate pyrophosphatase (ITPase). *Pharmacogenetics* 2004;14:181-7.
- Colombel JF, Ferrari N, Debuyere H, et al. Genotypic analysis of thiopurine S-methyltransferase in patients with Crohn's disease and severe myelosuppression during azathioprine therapy. *Gastroenterology* 2000;118:1025-30.

### Small bowel malignancy at diagnosis of coeliac disease

We were very interested in the paper by Rampertab *et al* (*Gut* 2003;52:121-14) and the correspondence by Hawdle *et al* (*Gut* 2004;53:470). Their data are quite similar to ours, from the Italian Registry of Complications of Coeliac Disease.

We collected information on 1968 patients over 18 years of age (mean age at diagnosis: 36.7 years; female/male ratio 3:1), diagnosed with coeliac diseases between January 1982 and December 2002 at 20 Italian clinical centres specialised in gastrointestinal disease. The diagnosis was made according to revised ESPGHAN criteria.<sup>1</sup> We found five (0.25%) patients with a small bowel malignancy at the time of diagnosis of coeliac disease. Age range was 49-69 years (mean 59 years) with a predominance of females (4:1). Survival rate was very poor as three patients died within 36 months of diagnosis.

These results indicate that there is an increased risk of developing small bowel malignancy in patients with coeliac disease. This correlation was confirmed by the female/male ratio. In fact, while small bowel neoplasms are usually more frequent in males, in our population four of five cases were female. Moreover, mean age at diagnosis of these cases was higher than that of patients overall, emphasising that the risk of a neoplasm increases with longstanding coeliac disease.

In conclusion, early diagnosis of coeliac disease should be made to prevent small bowel neoplasms from developing, and screening for this cancer should be carried out at diagnosis of coeliac disease, especially in patients diagnosed during adulthood.

**M Silano, M De Vincenzi**

Division of Human Nutrition and Health, Istituto Superiore di Sanità, Rome, Italy

Correspondence to: Dr M Silano, Division of Human Nutrition and Health, Istituto Superiore di Sanità, Viale Regina Elena, 299, 00161 Roma, Italy; marco.silano@iss.it

Competing Interests: None declared.

## Reference

- 1 Walker-Smith J, Guandalini S, Schmitz J, et al. Revised criteria for diagnosis of coeliac disease. Report of Working Group of European Society of Paediatric Gastroenterology and Nutrition. *J Pediatr Gastroenterol Nutr* 1990;**65**:909–11.

## Hypergastrinaemia in patients infected with *Helicobacter pylori* treated with proton pump inhibitors

We read with interest the commentary by McColl on *Helicobacter pylori* infection and long term proton pump inhibitor (PPI) therapy (*Gut* 2004;**53**:5–7).

It is remarkable that he did not mention gastrin although hypergastrinaemia is a result of reduced gastric acidity<sup>1</sup> as well as *Helicobacter pylori* infection,<sup>2</sup> and that patients with *H pylori* infection treated with PPI have additive hypergastrinaemia.<sup>3</sup> Hypergastrinaemia predisposes to gastric carcinoids in animals<sup>4,5</sup> and humans<sup>6,7</sup> as well as to malignant ECL cell derived tumours (gastric carcinomas) in animals<sup>8</sup> and humans.<sup>9,10</sup>

Interestingly, the carcinogenic effect of *H pylori* infection may be completely explained by its hypergastrinaemic effect,<sup>11</sup> a work where McColl was one of the authors. Furthermore, the increased gastric cancer frequency in moderate hypergastrinaemic INS-GAS mice concomitantly infected by *H pylori* infection<sup>12</sup> may also be caused by increased hypergastrinaemia in infected mice.<sup>13</sup>

To conclude, it is odd that gastrin was not taken into consideration when discussing the risk of gastric cancer following treatment with PPI in patients infected with *H pylori*. Animal as well as human studies linking gastrin to gastric cancer give support for a strategy where *H pylori* is eradicated in patients on long term PPI treatment.

**H L Waldum**

Correspondence to: Professor H L Waldum, Norwegian University of Science and Technology, Department of Clinical and Molecular Medicine, Trondheim University, Trondheim N-7006, Norway; helge.waldum@medisin.ntnu.no

Competing Interests: None declared.

## References

- 1 Korman MG, Strickland RG, Hansky J. Serum gastrin in chronic gastritis. *BMJ* 1971;**2**:16–18.
- 2 Moss SF, Calam J. Acid secretion and sensitivity to gastrin in patients with duodenal ulcer: effect of eradication of *Helicobacter pylori*. *Gut* 1993;**34**:888–92.

- 3 Schenk BE, Kuipers EJ, Klinkenberg-Knol EC, et al. Hypergastrinaemia during long-term omeprazole therapy: influences of vagal nerve function, gastric emptying and *Helicobacter pylori* infection. *Aliment Pharmacol Ther* 1998;**12**:605–12.
- 4 Havu N. Enterochromaffin-like cell carcinoids of gastric mucosa in rats after life-long inhibition of gastric acid secretion. *Digestion* 1986;**35**(suppl):42–55.
- 5 Hirayama F, Takagi S, Iwao E, et al. Development of poorly differentiated adenocarcinoma and carcinoid due to long-term *Helicobacter pylori* colonization in Mongolian gerbils. *J Gastroenterol* 1999;**24**:450–4.
- 6 Sjöblom S-M, Sipponen P, Karonen S-L, et al. Argrophil cell hyperplasia and carcinoid tumours in oxyntic mucosa of the stomach. Dependence on duration of pernicious anaemia. *Eur J Gastroenterol Hepatol* 1991;**31**:153–7.
- 7 Cadiot G, Vissuzaine C, Potet F, et al. Fundic argyrophilic carcinoid tumor in a patient with sporadic-type Zollinger-Ellison syndrome. *Dig Dis Sci* 1995;**40**:1275–8.
- 8 Waldum HL, Rørvik H, Falkmer S, et al. Neuroendocrine (ECL-cell) differentiation of spontaneous gastric carcinomas of cotton rats (*Sigmodon hispidus*). *Lab Anim Sci* 1999;**49**:241–7.
- 9 Qvigstad G, Qvigstad T, Westre B, et al. Neuroendocrine differentiation in gastric adenocarcinomas associated with severe hypergastrinemia and/or pernicious anemia. *APMIS* 2002;**110**:132–9.
- 10 Qvigstad G, Falkmer S, Westre B, et al. Clinical and histopathological tumour progression in ECL cell carcinoids ("ECLomas"). *APMIS* 1999;**107**:1085–93.
- 11 Hansen S, Vollset SE, Ardliff JES, et al. Hypergastrinemia is a strong predictor of distal gastric adenocarcinoma among *Helicobacter pylori* infected persons. *Gastroenterology* 1997;**112**:A575.
- 12 Wang TC, Dangler CA, Chen D, et al. Synergistic interaction between hypergastrinemia and *Helicobacter* infection in a mouse model of gastric carcinoma. *Gastroenterology* 2000;**118**:36–47.
- 13 Waldum HL, Brenna E, Mariensen TC. Safety of proton pump inhibitors. *Aliment Pharmacol Ther* 2000;**14**:1537–8.

## Terminal ileal biopsies should not be used to document extent of colonoscopic examination

We commend the British Society of Gastroenterology and the authors for the excellent publication of guidelines for the management of inflammatory bowel disease in adults (*Gut* 2004;**53**(suppl V):vi–16). However, we feel that their recommendation for routine terminal ileal biopsy is inappropriate. Although it is important to biopsy the terminal ileum if there is macroscopic evidence of an abnormality, their statement that "a terminal ileal biopsy performed at colonoscopy documents the extent of examination" is not recommended practice, due to the potential risk of variant Creutzfeldt-Jacob disease transmission from prion proteins which are prevalent in the lymphoid tissue of Peyer's patches in the ileum. Although the use of disposable forceps may reduce the risk of transmission, there could still be contamination of the intubation channel of the colonoscope and prion protein is resistant to the standard endoscopic cleaning process.<sup>1</sup> If the extent of examination needs to be documented, then a photograph of the ileocaecal valve or ileal mucosa is preferable.

It is worth emphasising that prion protein may be present in any part of the gastrointestinal tract<sup>2</sup> and random biopsy of gastrointestinal mucosa for reasons other than confirming an endoscopic abnormality or excluding microscopic colitis is not accepta-

ble. Similarly, for surveillance colonoscopy where multiple biopsy is recommended, the risk benefit ratio of this policy must be supported by the clinical indications.

**M D Rutter**

University Hospital of North Tees, Stockton-on-Tees, Cleveland, UK

**M G Bramble**

James Cook University Hospital, Middlesbrough, Cleveland, UK

Correspondence to: Dr M D Rutter, University Hospital of North Tees, Stockton-on-Tees, Cleveland, TS19 8PE, UK; matt.rutter@nth.nhs.uk

Competing Interests: None declared.

## References

- 1 Bramble MG, Ironside JW. Creutzfeldt-Jacob disease: implications for gastroenterology. *Gut* 2002;**50**:888–90.
- 2 Herzog C, Sales N, Etcheagaray N, et al. Tissue distribution of bovine spongiform encephalopathy agent in primates after intravenous or oral infection. *Lancet* 2004;**363**:422–8.

## IgG food antibodies should be studied in similarly treated groups

The recent paper by Atkinson and colleagues (*Gut* 2004;**53**:1459–1464) regarding IgG food antibodies and irritable bowel syndrome (IBS) fails to compare like with like. Regardless of the IgG results, the treatment group excluded significantly different foods to the control group, particularly those foods which appear to exacerbate symptoms of IBS. Of particular concern is the "yeast exclusion" diet. A low yeast diet is not a recognised diet in standard textbooks of dietetics and nutrition. However, alternative practitioners offering such a "yeast exclusion diet" sometimes recommend exclusion of a wide range of foods, such as: bakery products, alcoholic beverages, many other beverages including commercial fruit juices, cereals, condiments, dairy produce, fungi, meat products (hamburgers, sausages, and cooked meats made with bread or breadcrumbs), yeast extracts (Bisto, Marmite, Oxo, Bovril, Vegemite, gravy browning, and all similar extracts), all B vitamin preparations, and sometimes, most worryingly, "sugar foods" (sugar, sucrose, fructose, maltose, lactose, glycogen, glucose milk, sweets, chocolate, sweet biscuits, cakes, candies, cookies, puddings, desserts, canned food, packaged food, hamburgers, honey, mannitol, sorbitol, galactose, monosaccharides, polysaccharides, date sugar, turbinado sugar, molasses, maple syrup, most bottled juices, all soft drinks, tonic water, milkshakes, raisins, dried apricots, dates, prunes, dried figs, and other dried fruit).

Therefore, regardless of IgG antibody status, the dietary restrictions in one group are not controlled for by the other group, and hence the conclusion may not be valid.

It would also be helpful to know if any of the patients with IgG antibodies to a particular antigen also had IgE antibodies to the same antigen.

**W A C Sewell**

Correspondence to: Dr W A C Sewell, Path Links Immunology, Scunthorpe General Hospital, Scunthorpe DN15 7BH, UK; carrock.sewell@nlg.nhs.uk

Competing Interests: None declared.

## IgG antibodies to foods in IBS

We read with interest the article by Atkinson *et al* (*Gut* 2004;**53**:1459–64). The authors describe an important advance in our understanding of the putative role of inflammation in irritable bowel syndrome (IBS). However, we wonder whether their conclusion that assay of IgG antibodies may have a role in identifying candidate foods for elimination to treat patients with IBS may be a step too far. The four foods to which the patients most commonly formed antibodies and hence the four foods most commonly eliminated from the “true diet” were yeast (86.7%), milk (84.3%), whole egg (58.3%), and wheat (49.3%). The “sham diet” involved eliminating foods to which the patients had not formed antibodies and, therefore, in the sham group the exclusion rates for yeast, milk, whole egg, and wheat were very low (0%, 1.3%, 26.7%, and 8% respectively). It is therefore difficult to assess whether a diet excluding these foods would have led to symptomatic improvement in all patients, regardless of their antibody status.

Furthermore, the foods to which the study group commonly formed antibodies were similar to those already identified as leading to symptomatic benefit in patients with IBS when excluded from their diet. In a review cited by Atkinson and colleagues,<sup>1</sup> it was noted that in eight trials of exclusion diets in IBS, seven identified dairy products and five identified wheat as worsening symptoms. It is not clear whether the difference in improvement in symptoms seen in the current study between true and sham groups can be explained simply by the omission of these foods. This could in practice eliminate the need for antibody testing.

**J E D Mawdsley, P Irving, R Makins**

Barts and the London School of Medicine and Dentistry, London, UK

Correspondence to: Dr J E D Mawdsley, St Bartholomew's and Royal London Hospital, Turner St, London E1 2AD, UK; joelmawdsley@yahoo.com

Competing Interests: None declared.

## Reference

- 1 Burden S. Dietary treatment of irritable bowel syndrome: current evidence and guidelines for future practice. *J Hum Nutr Diet* 2001;**14**:231–41.

## Influence of dietary factors on the clinical course of inflammatory bowel disease

Jowett *et al* reported in their elegant study on the role of diet in maintaining remission in patients with ulcerative colitis (*Gut* 2004;**53**:1479–84). Surely the effect of diet has an essential, but often forgotten, role in altering the course of disease in all types of inflammatory bowel diseases. This role does not necessarily act by maintaining patients in remission clinically, but perhaps more importantly by minimising the activities of the disease and rendering it quiescent.

We have recently reported a case of active stricturing Crohn's disease in an adult female patient with high stoma output.<sup>1</sup> She was treated solely with casein base formula (Modulen IBD-Nestle, Vevey, Switzerland) for three weeks. Her stoma output was reduced from 2800 ml to 400 ml per day by

day 10. Serum albumin and serum protein significantly increased also. She subjectively felt better and pain free and stopped her opiate and non-opiate formula. The casein based formula is a nutritionally complete formulation containing a natural anti-inflammatory growth factor, transforming growth factor  $\alpha 2$ . The mechanism for inducing remission in our patient was possibly inhibition of expression of MHC class II protein in downregulating the inflammatory response.<sup>2</sup>

Previous studies have shown that there is a decrease in plasma antioxidant defences in all types of inflammatory bowel disease.<sup>3</sup> This is mirrored by an increase in free radical peripheral leucocyte DNA damage. It is therefore possible that the casein based formula acts as an antioxidant to minimise the oxidative stress that occurs in patients with active Crohn's disease. Another possible mechanism is that this formula may have a role as a prebiotic by stimulating the activity of bacteria which are already present in the gut.

Remission induced in our case study highlights the part played by a casein based formula in the management of adult Crohn's disease. The encouraging result demonstrates the need to treat similar cases with dietary measures first. This opportunity should not be missed as it may well obviate the need for surgical intervention or administration of potent pharmacotherapeutic agents which carries the risk of several comorbidities.

**N Y Haboubi, S Jones**

Nevill Hall Hospital, Gwent, South Wales, UK

Correspondence to: Dr N Y Haboubi, Nevill Hall Hospital, Brecon Rd, Abergavenny, Gwent NP7 7EG, South Wales, UK; nadim.haboubi@gwent.wales.nhs.uk

Competing Interests: None declared.

## References

- 1 Jones S, Shannon H, Srivastava E, *et al*. A novel approach to a patient with Crohn's disease and a high stoma output: a missed opportunity? *Scand J Gastroenterol* 2004;**4**:398–400.
- 2 Donnet-Hughes A, Duc N, Serrant P, *et al*. Bioactive molecules in milk and their role in health and disease: the role of transforming growth factor- $\alpha$ . *Immunol Cell Biol* 2000;**34**:49–53.
- 3 D'Odorico A, Bortolan S, Gaardin R, *et al*. Reduced plasma antioxidant concentrations and increased oxidative DNA damage in inflammatory bowel disease. *Scand J Gastroenterol* 2001;**36**:1289–94.

## Identification of ferroportin disease in the Indian subcontinent

Haemochromatosis is a common inherited disorder of iron metabolism, characterised by excessive iron absorption and deposition in tissues. The majority of cases are associated with mutations in the *HFE* gene and inherited in an autosomal recessive manner.<sup>1</sup> Autosomal dominant forms of haemochromatosis have been reported, mainly associated with mutations in the *ferroportin 1* gene.<sup>2</sup> This syndrome, termed type 4 haemochromatosis or more recently ferroportin disease,<sup>3</sup> is usually characterised by an early increase in serum ferritin with normal transferrin saturation. Iron accumulation is most prominent in Kupffer cells and other macrophages, in addition to hepatocytes. Some patients do not tolerate venesection

therapy well and can develop anaemia. Hereditary iron overload disorders appear to be uncommon in Asia. Secondary iron overload due to beta thalassaemia is relatively common in the Indian subcontinent. However, primary iron overload disorders and *HFE* mutations appear to be rare and cases have not been well characterised in this region.<sup>4,5</sup> We identified a patient from the Indian subcontinent with features typical of ferroportin disease.

A 36 year old female of Sri Lankan origin presented for a routine medical examination in December 2003. She was found to have an elevated serum ferritin of 3145  $\mu\text{g/l}$ . Her serum iron (17.1  $\mu\text{mol/l}$ ) and transferrin saturation (29%) were normal. Liver functions tests, blood glucose, and thyroid studies were all normal. Physical examination was normal and she had no significant past medical history or risk factors for iron overload.

C282Y, H63D, and S65C *HFE* gene mutations were all negative and she had no family history of iron overload. Her mother and three siblings all had normal serum ferritin levels. Her father died of ischaemic heart disease aged 48 years.

A magnetic resonance imaging scan showed hepatic iron overload. Liver biopsy showed grade 3–4 iron deposition within hepatocytes and Kupffer cells; no fibrosis or cirrhosis was evident (fig 1). The hepatic iron concentration was 17 700  $\mu\text{g/g}$  dry weight and hepatic iron index was 9.1.

Venesection therapy was initially poorly tolerated with the development of anaemia following the first two 500 ml venesections. Her haemoglobin is now stable on a programme of 300–500 ml venesections every three weeks.

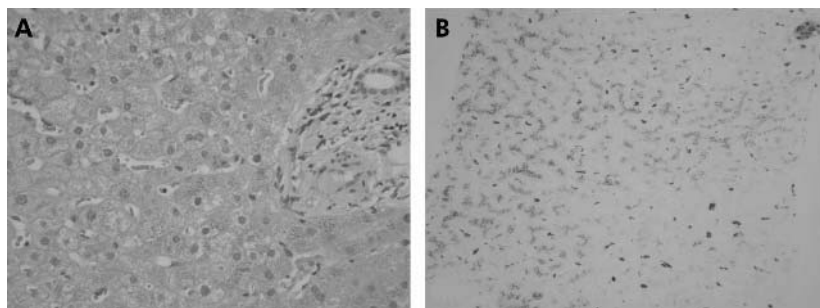
The features of ferroportin disease in this patient led us to sequence the *ferroportin 1* gene, as previously described.<sup>6</sup> Analysis of the DNA sequence revealed a heterozygous three base pair deletion (TTG) in exon 5. This is the same deletion, V162del, described by us and others in haemochromatosis patients from Australia, the UK, Italy, and Greece.<sup>6–9</sup>

This is the first report to identify V162del or indeed any *ferroportin 1* mutation in an individual from the Indian subcontinent. Identification of V162del in an Asian patient confirms that this mutation is likely to be the most common mutation of *ferroportin 1* and the most common cause of non-*HFE* associated haemochromatosis. The wide geographical distribution of this mutation suggests that it is a recurrent mutation that has repeatedly arisen in distinct populations, probably by slippage mispairing.

Iron overload in this patient was typical of ferroportin disease. At the time of diagnosis she was asymptomatic and had no fibrosis on liver biopsy. Whether fibrosis or clinical complications will develop with age if iron stores are not depleted is unclear.

In conclusion, we have identified the V162del mutation of *ferroportin 1* in a fifth geographical location, emphasising that this mutation is the most common and widely distributed mutation which causes non-*HFE* haemochromatosis. We have identified V162del in a region where iron overload disorders have not been well characterised. Analysis of this and other *ferroportin 1* mutations may be useful in the study of iron overload disorders in this region and may be the basis of hitherto unexplained cases of iron overload.





**Figure 1** Liver biopsy sections from our patient stained with (A) haematoxylin and eosin and (B) Perls' Prussian blue (magnification 100×). Grade 3–4 iron is prominent in hepatocytes and Kupffer cells.

### Acknowledgements

This work was supported in part by grants from the National Health and Medical Research Council of Australia (953219), the National Institutes of Health, USA (5R01DK057648-02), and the Haemochromatosis Society of Australia to VNS.

#### D F Wallace

Membrane Transport Laboratory, The Queensland Institute of Medical Research, Brisbane, Queensland, Australia

#### P Browett

Department of Molecular Medicine and Pathology, University of Auckland, and LabPlus, Auckland City Hospital, Auckland, New Zealand

#### P Wong

Department of Gastroenterology, Auckland City Hospital, Auckland, New Zealand

#### H Kua

Diagnostic Medlab, Auckland, New Zealand

#### R Ameratunga

LabPlus, Auckland City Hospital, Auckland, New Zealand

#### V N Subramaniam

Membrane Transport Laboratory, the Queensland Institute of Medical Research, Brisbane, Queensland, Australia

Correspondence to: Dr V N Subramaniam, Membrane Transport Laboratory, The Queensland Institute of Medical Research, 300 Herston Rd, Herston, Brisbane, QLD 4006, Australia; nathanS@qimr.edu.au

doi: 10.1136/gut.2004.060988

Competing Interests: None declared.

### References

- 1 Feder JN, Gnirke A, Thomas W, *et al.* A novel MHC class I-like gene is mutated in patients with hereditary haemochromatosis. *Nat Genet* 1996;**13**:399–408.
- 2 Pietrangelo A. Non-HFE hemochromatosis. *Hepatology* 2004;**39**:21–9.
- 3 Pietrangelo A. The ferroportin disease. *Blood Cells Mol Dis* 2004;**32**:131–8.
- 4 Kaur G, Rappaport CC, Xavier M, *et al.* Distribution of C282Y and H63D mutations in the HFE gene in healthy Asian Indians and patients with thalassaemia major. *Natl Med J India* 2003;**16**:309–10.
- 5 Thakur V, Guptan RC, Hashmi AZ, *et al.* Absence of hemochromatosis associated Cys282Tyr HFE gene mutation and low frequency of hemochromatosis phenotype in nonalcoholic chronic liver disease patients in India. *J Gastroenterol Hepatol* 2004;**19**:86–90.
- 6 Wallace DF, Pedersen P, Dixon JL, *et al.* Novel mutation in ferroportin1 is associated with autosomal dominant hemochromatosis. *Blood* 2002;**100**:692–4.
- 7 Devalia V, Carter K, Walker AP, *et al.* Autosomal dominant reticuloendothelial iron overload associated with a 3-base pair deletion in the ferroportin 1 gene (SLC11A3). *Blood* 2002;**100**:695–7.
- 8 Roetto A, Merryweather-Clarke AT, Daraio F, *et al.* A valine deletion of ferroportin 1: a common mutation in hemochromatosis type 4. *Blood* 2002;**100**:733–4.
- 9 Cazzola M, Cremonesi L, Papaioannou M, *et al.* Genetic hyperferritinaemia and reticuloendothelial iron overload associated with a three base pair deletion in the coding region of the ferroportin gene (SLC11A3). *Br J Haematol* 2002;**119**:539–46.

## BOOK REVIEW

### Morson and Dawson's Gastrointestinal Pathology, 4th edn

Edited by D W Day, J R Jass, A B Price, *et al.* Massachusetts: Blackwell Publishing, 2003, £175.00, pp 692. ISBN 0-632-04204-4

Why do people buy a book such as this, which involves a not inconsiderable financial outlay (even if you box clever and make it tax deductible)? I think for two main reasons—firstly, for use as a bench book, and secondly, for information on the pathological basis of gastrointestinal disease for interest, teaching, or indeed research purposes.

On the first criterion, this book succeeds, usually quite brilliantly. As a *vade mecum* on gastrointestinal pathology it should be on the shelf of every pathologist who engages in the reporting of such material. In my view, the book is more user friendly than the

competition—Fenoglio-Preiser and Goldman to name but two—and is certainly more readable. I would therefore extol its virtues unreservedly in this respect.

On the second criterion, as a source book, I suppose the correct word is patchy. Some sections, for example that on colorectal tumours, is admirable in this respect, whereas other sections are more limited in scope and even cursory in their treatment of the pathobiology. There is also the problem of the unavoidable intrinsic delay in producing such a book, resulting in reference lists which are some years away from the publication date. I am aware however that my personal outlook is not that of most individuals who will purchase this volume so I am probably being over critical. It is, after all, quintessentially a bench book, and excellent at that.

However, I do have one real beef. In any multi-author work there is bound to be variation, but here we are not told which one of the stellar caste were responsible for which section or chapter. Of course we can make informed guesses about the Barrett's or colorectal carcinoma sections, but who did the GIST bit? Because of some (minor) errors in the criteria for the diagnosis of malignancy, I have tried to berate a number of authors who have all denied responsibility, and blamed someone else—usually the author(s) absent at the time. Not good enough.

I have to concede however that the authors have succeeded in producing perhaps *the text* in gastrointestinal pathology, which is a credit to both themselves and the discipline in the UK. I congratulate them.

N A Wright

## CORRECTIONS

doi: 10.1136/gut.2003.025494corr1

In the January 2005 issue of *Gut*, one of the author's names of the paper entitled Human peripheral and gastric lymphocyte responses to *Helicobacter pylori* NapA and AphC differ in infected and uninfected individuals (H J Windle, Y S Ang, V A Morales, R McManus, and D Kelleher. *Gut* 2005;**54**:25–32) was cited incorrectly. V A Morales should read V Athie-Morales. The journal apologises for this mistake.

doi: 10.1136/gut.2003.026807corr1

In the December issue of *Gut* fig 1 in the paper by AJG Bell *et al.* (Human lymphocyte stimulation with pouchitis flora is greater than with flora from a healthy pouch but is suppressed by metronidazole. *Gut* 2004;**53**:1801–1805) is incorrect. The labels for fig 1C are inverted; the squares should have been labelled HetNon and the triangles HetPM. The legend is also incorrect because the label for flora grown on agar without metronidazole is HetNon, not HetP as stated.