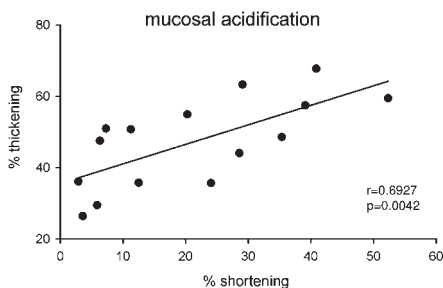


doi:10.1136/gut.2010.212431

Emad El-Omar and Severine Vermeire and Alexander Gerbes *Editor and Deputy Editors*

Intraluminal ultrasound and oesophageal shortening

Longitudinal muscle contraction is associated with oesophageal shortening. When exaggerated this shortening could lead to symptoms such as dysphagia, chest pain and heartburn. Oesophageal shortening has traditionally been monitored by tracking clips with fluoroscopy. High-frequency intraluminal ultrasound (HFIUS) has recently been proposed as an alternative method of evaluating oesophageal shortening in patients with oesophageal symptoms. Boesmans *et al* provide the first in vivo study comparing HFIUS measurements against fluoroscopy. They simultaneously assessed oesophageal shortening and muscle wall thickness in lightly sedated cats, using fluoroscopic tracking of endoscopically attached metal clips and HFIUS, respectively. Oesophageal shortening was studied during secondary peristalsis and oesophageal mucosal acidification (see figure). Apart from validating the use of HFIUS against the more cumbersome metal clip tracking by fluoroscopy, the authors also showed that oesophageal mucosal acidification provokes basal oesophageal shortening and secondary peristaltic contractions associated with strong and prolonged oesophageal shortening. This technique should now be transferrable to humans. *See page 433*



Correlation between muscle wall thickness and oesophageal shortening. Baseline muscle wall thickness (% thickening) and oesophageal shortening (% shortening) correlate significantly ($r=0.69266$; $p=0.0042$) during mucosal acidification.

A novel non-viral gene vector against TNF- α

TNF- α blockade can be achieved by monoclonal antibodies (eg Infliximab) but this is associated with side effects. An alternative and safer approach is to use

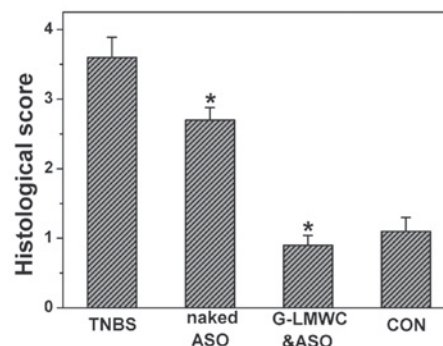
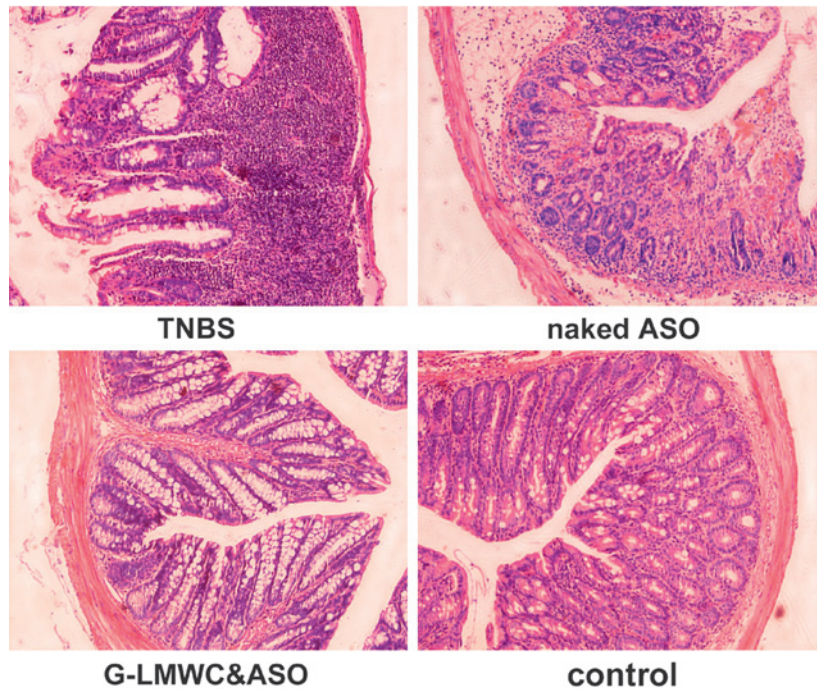
anti-sense oligonucleotide (ASO) which has smaller molecular size and less immunogenic effect. The main problem however is in devising a safe and effective delivery mechanism to the target cells (eg, the activated colonic macrophages that secrete TNF- α). Zuo *et al* used a novel nano-complex, based on galactosylated low molecular weight chitosan (gal-LMWC) and an ASO against TNF- α . A stable nano-complex (gal-LMWC/ASO) was injected into mice by intracolonic administration. The therapeutic effects of this complex were studied in two models of colitis: 2,4,6-trinitrobenzene sulfonic acid (TNBS)-induced colitis and CD4+CD45RBhi T cells transfer colitis. A single injection in TNBS

colitis or repeated treatment in CD45RBhi transfer colitis both significantly ameliorated the clinical and histopathological severity of the wasting disease (see figure), reduced tissue levels of inflammatory cytokines, and abrogated body weight loss, diarrhoea and intestinal protein loss. The inhibition of TNF- α by this strategy represents a promising therapeutic approach for the treatment of CD. *See page 470*

Restoration of APC gene function in colorectal cancer cells with antibiotics

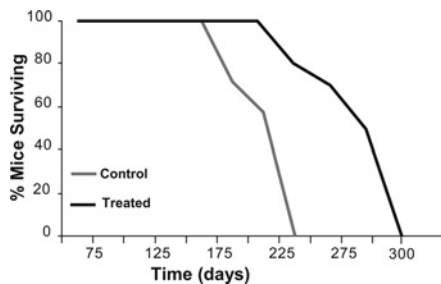
The majority of patients with sporadic and hereditary colorectal cancer have

TNBS colitis



gal-LMWC/ASO reduces histopathological scores in TNBS-colitis.

mutations in the gene encoding APC. Approximately 30% of these mutations are single nucleotide changes that result in premature stop codons (nonsense mutations). A potential therapeutic approach for treatment of this subset of patients is the use of aminoglycosides and macrolides that induce nonsense mutation read-through and restore levels of full-length protein. Zilberberg *et al* used precisely this approach and report some potentially exciting results. They first used reporter plasmids and colorectal cancer cell lines to demonstrate that several aminoglycosides and tylosin, a member of the macrolide family, induced read-through of nonsense mutations in the APC gene. Later, in xenograft experiments and in the ApcMin/+ mouse model, they show that these compounds ameliorated the tumorigenic clinical symptoms caused by nonsense mutations in the APC gene. **See page 496**



Tylosin treatment increases the survival of ApcMin/+.

Primary biliary cirrhosis—environmental risk factors are quite important

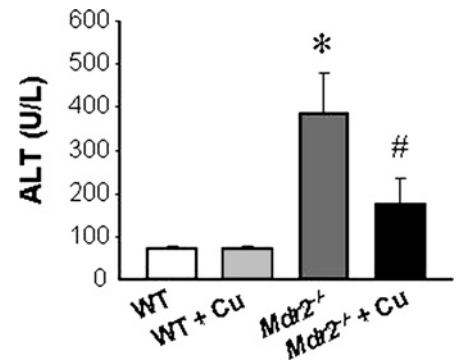
The aetiology of PBC is enigmatic. An influence of genetic, but also of environmental factors has been suggested. The paper presents the largest study so far, investigating possible risk factors of PBC. More than 2500 PBC patients were compared to 2400 age and sex matched controls. Beside smoking and urinary tract infections (antibiotics as risk factor?) some cosmetics were found as prominent risk factors (see table). This confirms the hypothesis, that ingredients of some cosmetics may trigger autoimmune processes ultimately leading to PBC. An association with other autoimmune diseases, shingles and a history of obstetric cholestasis underline the contribution of genetic risk factors to PBC. **See page 508**

Results of multivariate analysis (forward logistic regression)

Risk factor	Adjusted OR compared to epidemiological cases (95% CI)	Adjusted OR compared to PBC foundation cases (95% CI)
Smoking	1.6 (1.2 to 2.3)	1.5 (1.3 to 1.7)
Hair dye	1.8 (1.2 to 2.7)	1.3 (1.0 to 1.5)
Thyroid disease	2.0 (1.4 to 2.9)	1.6 (1.3 to 1.9)
Urinary tract infections	2.4 (1.7 to 3.4)	1.7 (1.5 to 2.1)
Shingles	2.5 (1.7 to 3.5)	NS
Obstetric pruritus	NS	2.1 (1.6 to 2.7)

Curcumin—a yellow cure for jaundice

Curcumin, a yellow pigment found in the perennial herb curcuma longa, has been used to treat gastrointestinal disorders in Ayurvedic medicine. In rodent models of chemically induced liver fibrosis curcumin exhibits anti-inflammatory, anti-oxidative and anti-fibrotic properties. The present work by the group of Michael Trauner elucidates the mechanisms of curcumin action in a knock-out mouse model (*MDR2*^{-/-}) of progressive cholangiopathy with biliary fibrosis. Biliary fibrosis, as in PBC and PSC, is an important mechanism of cirrhosis with limited medical treatment available so far. In vivo and in vitro curcumin inhibited proliferation and inflammatory activation of both cholangiocytes and myofibroblasts. This was mediated by activation of PPAR γ and by inhibition of ERK signalling. Portal inflammation, fibrosis and liver injury were clearly reduced (see figure), which may explain beneficial effects of curcumin in jaundiced patients. **See page 521**

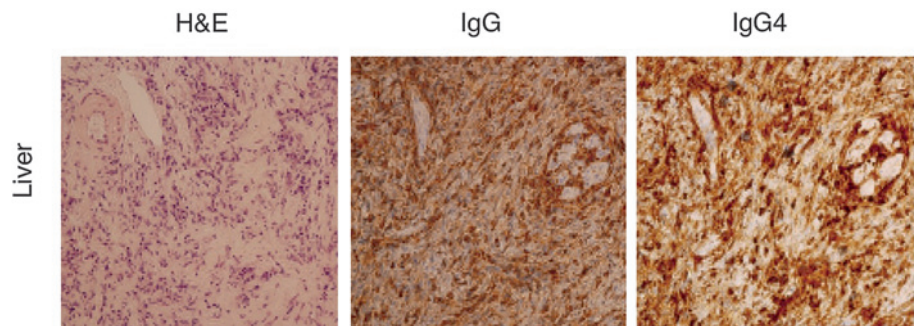


Compared with WT mice, untreated *Mdr2*^{-/-} mice show increased serum parameters of liver injury (ALT) whereas *Mdr2*^{-/-} + Cu mice have significantly reduced serum ALT.

IgG4-related sclerosing disease

Autoimmune pancreatitis (AIP) is an inflammatory disorder which is characterised by increased serum levels of IgG4 or by an IgG4-positive plasmacytic infiltrate into the inflamed tissue. Another important feature of AIP is a wide variety

of extrapancreatic manifestations such as sialadenitis, cholangitis, retroperitoneal fibrosis and inflammatory pseudotumor of the liver and lung. However, little is known about the role played by the IgG4 subtype in the inflammatory process. Akitake report a case with IgG4-related sclerosing disease whose ileal and colonic mucosa bore a marked infiltration of IgG4-expressing plasma cells. Interestingly, peripheral blood mononuclear cells (PBMCs) isolated from this case show enhanced T helper type 2 (Th2) and IgG4 responses upon stimulation with Toll-like receptor (TLR) ligands. These results indicate possible involvement of excessive Th2 responses against intestinal microflora in some cases with IgG4-related sclerosing disease. **See page 542**



Liver biopsies were stained with anti-IgG4 or anti-IgG antibody for visualisation of plasma cells expressing IgG4 or IgG.