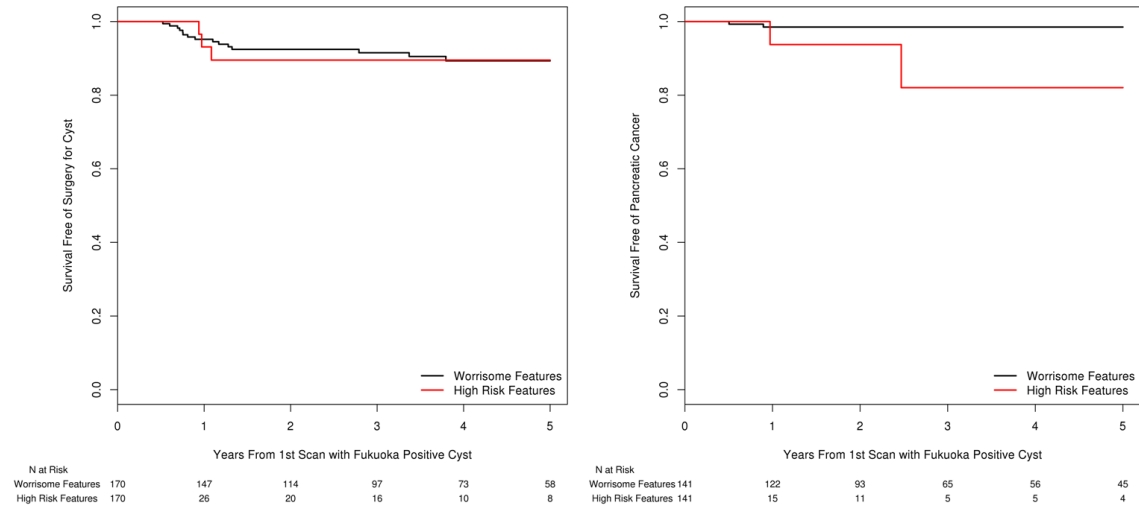
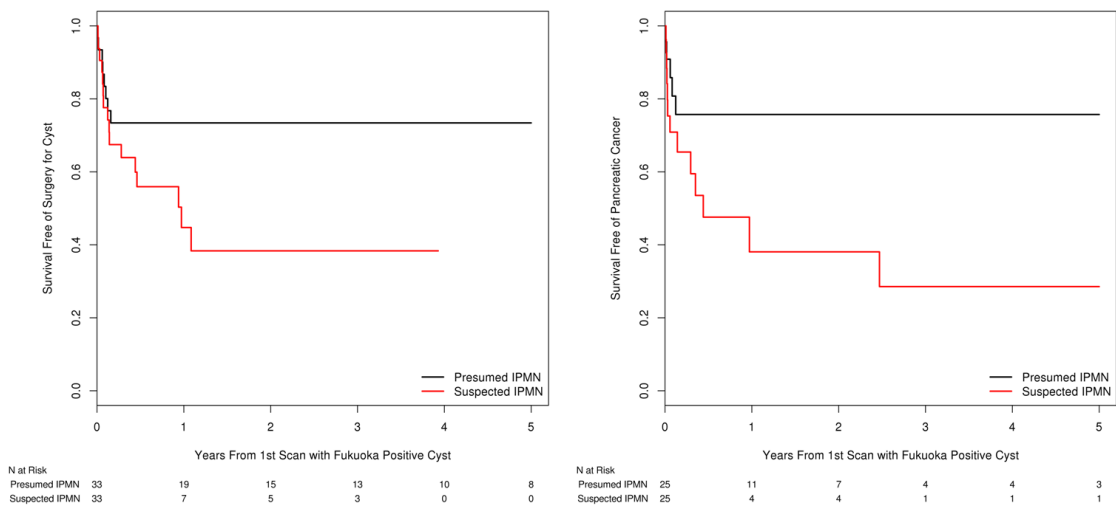


## Supplementary Figures

**Supplementary Figure 1.** Survival-free Rates After 6 Months of Fukuoka-Positive Characteristics. A, Pancreatic cyst surgery. B, Pancreatic cancer.



**Supplementary Figure 2.** Survival-free rates based on Fukuoka-Positive suspected and presumed intraductal papillary mucinous neoplasm. A, Pancreatic cyst surgery. B, Pancreatic cancer.



**Supplementary Figure 3.** Survival-free Rates for Pancreas Cyst Surgery by time-period of diagnosis for A, Fukuoka Negative cysts. B, Fukuoka Positive cysts.

