

## Gastrointestinal Symptoms of 95 Cases with SARS-CoV-2 Infection

Lu Lin<sup>1\*</sup>, Xiayang Jiang<sup>1\*</sup>, Zhenling Zhang<sup>1</sup>, Siwen Huang<sup>1</sup>, Zhenyi Zhang<sup>1</sup>, Zhaoxiong Fang<sup>1</sup>, Zhiqiang Gu<sup>1</sup>, Liangqing Gao<sup>1</sup>, Honggang Shi<sup>1</sup>, Lei Mai<sup>1</sup>, Yuan Liu<sup>1</sup>, Xianqi Lin<sup>1</sup>, Renxu Lai<sup>1</sup>, Zhixiang Yan<sup>2#</sup>, Xiaofeng Li<sup>1#</sup>, Hong Shan<sup>2,3#</sup>

### Author Affiliations

<sup>1</sup> Department of Gastroenterology, the Fifth Affiliated Hospital, Sun Yat-sen University, Zhuhai, Guangdong Province, China

<sup>2</sup> Guangdong Provincial Key Laboratory of Biomedical Imaging and Guangdong Provincial Engineering Research Center of Molecular Imaging, the Fifth Affiliated Hospital, Sun Yat-sen University, Zhuhai, Guangdong Province, China

<sup>3</sup> Center for Interventional Medicine, the Fifth Affiliated Hospital, Sun Yat-sen University, Zhuhai, Guangdong Province, China

\* These authors contributed equally to this work.

# Correspondence to

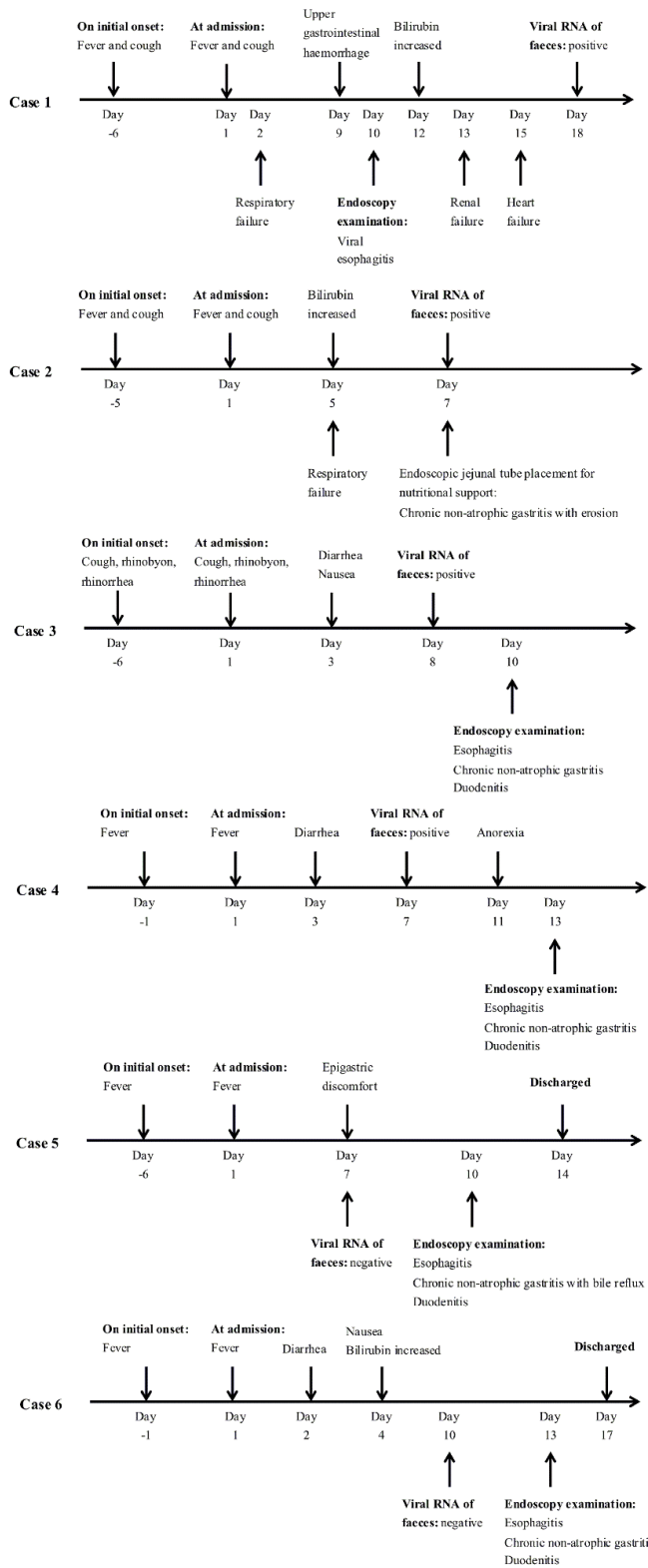
Professor Hong Shan, Guangdong Provincial Key Laboratory of Biomedical Imaging and Guangdong Provincial Engineering Research Center of Molecular Imaging, the Fifth Affiliated Hospital, Sun Yat-sen University, Zhuhai, Guangdong Province 519000, China; [shanhong@mail.sysu.edu.cn](mailto:shanhong@mail.sysu.edu.cn);

Dr Xiaofeng Li, Department of Gastroenterology, the Fifth Affiliated Hospital, Sun Yat-sen University, Zhuhai, Guangdong Province 519000, China; [zdwylxf@163.com](mailto:zdwylxf@163.com);

Dr Zhixiang Yan, Guangdong Provincial Key Laboratory of Biomedical Imaging and Guangdong Provincial Engineering Research Center of Molecular Imaging, the Fifth Affiliated Hospital, Sun Yat-sen University, Zhuhai, Guangdong Province 519000, China; [yanzhix3@mail.sysu.edu.cn](mailto:yanzhix3@mail.sysu.edu.cn)

**Table S1.** Gastrointestinal manifestations of 11 SARS-CoV-2 infected patients without imaging features of COVID-19 pneumonia

	<b>All patients (n=11)</b>	<b>On initial presentation (n=3)</b>	<b>During hospitalization (n=8)</b>
<b>Symptoms</b>			
Diarrhea	4	2	2
Anorexia	2	0	2
Nausea	2	0	2
Vomiting	0	0	0
Acid reflux	0	0	0
Epigastric discomfort	1	0	1
Upper gastrointestinal hemorrhage	0	0	0
<b>Hepatic function impairment</b>	7	1	6
Bilirubin	5	0	5
ALT or AST	2	1	1



**Figure S1.** Clinical timeline for six patients subjected to endoscopic examination