

Ergot poisoning in acute hepatic necrosis

M. J. WHELTON, A. ALLAWAY, ANNE STEWART, AND L. KREEL

From the Departments of Medicine, Pathology, and Radiology, Royal Free Hospital, London

Reports of ergot poisoning are rare in the literature in English (Robertson and Ashby, 1928; Gabbai, Lisbonne, and Pourquier, 1951; Jones and Williams, 1966). The toxic effects of ergot appear to be enhanced in the presence of febrile and septic states and in liver disease (Brazeau, 1965), and we report a patient with ergotism leading to peripheral gangrene, who also suffered from acute hepatic necrosis.

CASE HISTORY

A 39-year-old woman was admitted to the Royal Free Hospital on 3 May 1967. She had a five-year history of migraine for which she had been treated with Cafergot (ergotamine tartrate and caffeine) and Migril (ergotamine cyclizine and caffeine). She had taken Cafergot suppositories (ergotamine, caffeine, belladonna, isobutallyl barbituric acid) each night for two years and had recently supplemented these with Migril taken orally. There was a long history of vague cramps in the hands and legs and of peripheral vasoconstriction on exposure to cold. These symptoms had become progressively worse in the six weeks before admission. Approximately three weeks before admission she noticed nausea and lassitude, and became jaundiced. There was no history of contact with other cases of jaundice nor had she taken any drugs apart from ergotamine. She was admitted to hospital and continued to receive Cafergot suppositories at night until 1 May. At this time there were no pulses in the upper limbs and she was transferred to the Royal Free Hospital for further care on 3 May.

On admission she was deeply jaundiced, confused, and precomatose. No distal pulses could be felt beyond the level of the brachial and femoral arteries. There was a Volkmann's ischaemic contracture on the right and both hands were pale and cold below the wrists. Both legs were pale and cold below mid calf. The liver was small on percussion.

Liver function tests showed bilirubin (total) 27 mg/100 ml, (conjugated) 24 mg/100 ml; alkaline phosphatase 16 King Armstrong units, aspartate transaminase 295 iu; cholesterol 100 mg/100 ml.

Haemoglobin was 9.3 g, and WBCs numbered 13,000. An ECG was normal, and an EEG compatible with hepatic coma. Treatment was continued with neomycin 1 g six hourly, magnesium sulphate by enema and stomach tube, and prednisolone 15 mg six hourly. Peritoneal dialysis was begun to assist elimination of any

remaining ergotamine. Bilateral brachial blocks were performed with lignocaine and an epidural block with marcaine was instituted via a Tuohy catheter. Serial skin temperatures showed little change after the institution of sympathetic blockade and this was discontinued after 36 hours. In addition she was given nitrites orally and penicillin 1 mega four hourly, intramuscularly.

Intermittent hyperbaric oxygen therapy was instituted after 24 hours in view of the incipient gangrene of all four limbs. Almost immediately improvement was seen in the limb temperatures and appearance. Her mental state also gradually improved over the second 48 hours and by the third day she was rational. However, the liver could not be palpated, and the Thrombotest remained ominously low at 12%. A total of 36 hours' intermittent hyperbaric oxygen was administered over the first week and gradual improvement was maintained in the limbs throughout this period. Therapy was discontinued when she developed a mild chest infection, at which stage the terminal digits on the right hand developed irreversible gangrene (Fig. 1). The left hand had recovered completely apart from some probable ischaemic damage to the intrinsic muscles. The right foot demarcated below the ankle but the left foot recovered apart from the toes.

Despite the improvement in the limbs, the liver showed no evidence of regeneration. In the second week she gradually went into hepatic and renal failure and died on 17 May. At necropsy the liver was small and shrunken and weighed only 700 g. Histologically the appearances were those of massive hepatic necrosis with early nodular regeneration. The changes were compatible with a viral

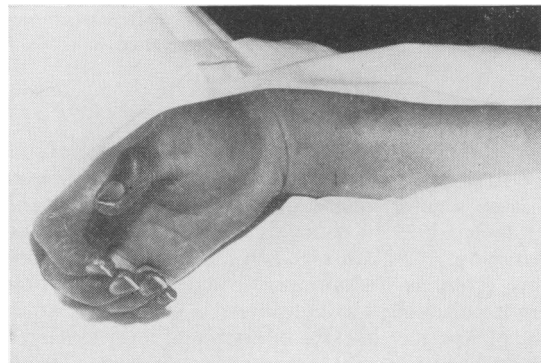

FIG. 1. *Peripheral gangrene in the right hand. Both radial and ulnar pulses were absent.*

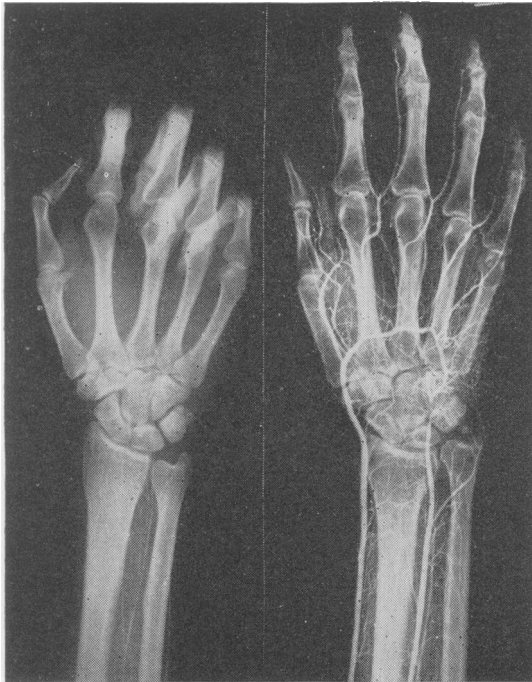


FIG. 2. Postmortem arteriograms: right hand shows incomplete filling of the distal vessels even after injection of excess quantities of diluted barium. Control arteriogram with normal filling on right.

aetiology. Abnormal constriction of the peripheral arteries of the right arm and leg were demonstrated by postmortem arteriography (Fig. 2). The right radial artery showed no structural abnormality at the level of the constriction. A section of the skin of the foot close to a gangrenous area showed congested, swollen arteries and arterioles. There was marked endothelial swelling and some vessels contained small thrombi. The small arteries of the spleen, myocardium, lung, and kidney showed no abnormality. There was a haemorrhagic infarct in the head of the pancreas. Pancreatic arteries showed thickened walls and narrowed lumens.

DISCUSSION

Ergot poisoning is uncommon but many of the reported cases have been in association with liver disease (Yater and Cahill, 1936; Comfort and Erickson, 1939; Kenney, 1946; Gould, Price, and Ginsberg, 1936). In many instances the ergotamine was given as an antipruritic agent. At one time ergot poisoning was considered a special hazard in the puerperium in cases of puerperal fever (Saenger, 1929).

Treatment is difficult. Sympathetic blockade is usually recommended as the vasoconstrictor effect

of ergot outweighs its a blocking effect, though Lewis (1935) found that relaxation of vasomotor tone did not help to prevent necrosis in the Fowl comb. Nitrites, papaverine, or even bradykinin may be of value in promoting vasodilatation. Hyperbaric oxygen may help to preserve tissue for an interim period while the effects of the drug are regressing, though oxygen itself is a vasoconstrictor (Ledingham, 1967). Dialysis may help to remove the drug, and one of the cases reported by Jones and Williams (1966) had a mannitol diuresis induced with apparent benefit, though Brazeau (1965) points out that only traces are seen in the urine under normal circumstances. No specific antagonist is known and so the aim must be to eliminate the drug and prevent gangrene if possible. Unfortunately, permanent intimal damage occurs in some cases with resultant intravascular clotting.

The case of Yater and Cahill (1936) showed varying degrees of constriction with medial and intimal degeneration in the vessels of the amputated limbs. Gould *et al.* (1936) described changes in many arterioles in addition to those of the affected limb.

In our patient, though constriction of the main peripheral limb arteries was convincingly shown on post-mortem arteriography, a section of the radial artery taken at its point of constriction failed to show any abnormality. The changes seen in skin from the edge of a gangrenous area, and on section through a gangrenous toe, were the non-specific ones of endothelial swelling and proliferation with small thrombi in the vascular lumens. No lesions were found in the arteries of the heart, lungs, or kidneys, but the arteries of the infarcted pancreas showed structural abnormalities.

The toxic dose varies enormously and is much less in the presence of febrile states and liver disease. It is suggested that the liver normally detoxicates the drug (Brazeau, 1965) but this effect is decreased in the presence of defective hepatic function.

At the present time ergotamine tartrate is used almost exclusively in the treatment of migraine. The dangers of its use, even in currently acceptable pharmacological dosage, in the presence of liver disease, must be constantly borne in mind. Indeed routine medication, as in our case, would seem to have many disadvantages, not the least being the fact that ergot poisoning can itself produce headache.

SUMMARY

A case of ergot poisoning in association with acute hepatic necrosis is recorded. Initial improvement followed treatment by sympathetic blockade, peritoneal dialysis, nitrites, and hyperbaric oxygen. Before death, pulses had returned in both forearms,

though peripheral gangrene had developed in one hand and leg. Death was due to acute hepatic necrosis, presumably of viral origin. It is suggested that the manifestations of ergot poisoning were augmented by defective hepatic detoxication. The use of ergotamine preparations should be avoided, as far as possible, in the presence of liver disease.

Our thanks are due to Professor Sherlock for her permission to publish details of this case.

REFERENCES

- Brazeau, P. (1965). Ergot, ergot alkaloids and oxytocin. In *The Pharmacological Basis of Therapeutics*, edited by L. S. Goodman and A. Gilman, 3rd ed., pp. 878-887. Macmillan, New York.
- Comfort, M. W., and Erickson, C. W. (1939). Untoward effects from the use of ergot and ergotamine tartrate. *Ann. intern. Med.*, **13**, 46-60.
- Gabbai, A., Lisbonne, and Pourquier, H. (1951). Ergot poisoning at Pont St. Esprit. *Brit. med. J.*, **2**, 650-651.
- Gould, S. E., Price, A. E., and Ginsberg, H. I. (1936). Gangrene and death following ergotamine tartrate (gynergen) therapy. *J. Amer. med. Ass.*, **106**, 1631-1635.
- Jones, E. M., and Williams, B. (1966). Two cases of ergotamine poisoning in infants. *Brit. med. J.*, **4**, 466.
- Kenney, F. R. (1946). Gangrene of the hand following treatment for pruritus of hepatotoxic origin. *New Engl. J. Med.*, **235**, 35-49.
- Ledingham, I. McA. (1967). Hyperbaric oxygenation. *Sci. Basis Med. Ann. Rev.*, pp. 90-108.
- Lewis, T. (1935). The manner in which necrosis arises in the fowl's comb under ergot poisoning. *Clin. Sci.*, **2**, 43-55.
- Robertson, J., and Ashby, H. T. (1928). Ergot poisoning among rye bread consumers. *Brit. med. J.*, **1**, 302-303.
- Saenger, H. (1929). Über Puerperalgangrän bei septischen Zuständen und Gynergenmedikation. *Zbl. Gynäk.*, **53**, 586-594.
- Yater, W. M., and Cahill, J. A. (1936). Bilateral gangrene of feet due to ergotamine tartrate, used for pruritus of jaundice. *J. Amer. med. Ass.*, **106**, 1625-1631.