
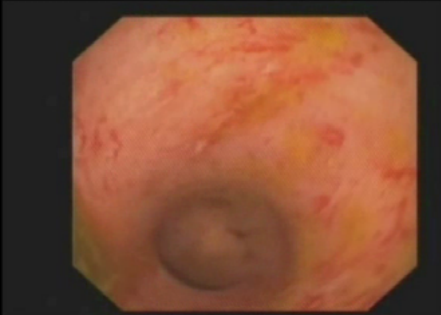
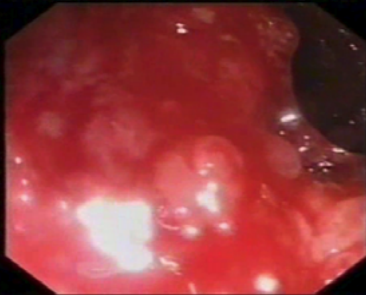


# UCEIS©: Bleeding Reference

	None (1)	No visible blood	<i>See Normal under Vascular Pattern</i>
Bleeding	Mucosal (2)	Some spots or streaks of coagulated blood on the surface of the mucosa ahead of the scope, which can be washed away.	 <p>12:03:47 CVP: A1/4 D.F: h:5 h:N</p>
	Luminal mild (3)	Some free liquid blood in the lumen	
Bleeding cont'd	Luminal severe (4)	Frank blood in lumen ahead of endoscope or visible oozing from mucosa	 <p>ID No. : Name : Sex : Age : D. O. Birth : 04/06/2008 07:37:49 SCV: 46  C: N E: A3 C: D  Physician : Comment :</p>